

PEER REVIEWED

Conjunctival Lymphoma

Jasmine Wong Yumori OD, FAAO, Naida Jakirlic OD, FAAO, and Kenneth Van, OD

Abstract

Mucosa-associated lymphoid tissue (MALT) lymphoma is a subtype of non-Hodgkin lymphoma (NHL) that can occur in the stomach, salivary glands, lungs, thyroid glands or conjunctiva. This teaching case report involving a patient with localized conjunctival lymphoma reviews key findings, differential diagnoses and treatment and management. The epidemiology, pathophysiology and risk factors associated with conjunctival lymphoma are also discussed. Although this cancer is relatively uncommon, it is critical to diagnose it while it is still confined to conjunctival tissue because delayed diagnosis may lead to systemic dissemination, a more complicated treatment regimen and poorer prognosis.

Key Words: conjunctival neoplasia, lymphoma, conjunctival lymphoma, MALT lymphoma

Background

This teaching case report describes the diagnosis and care of an otherwise healthy 24-year-old Asian male with conjunctival lymphoma. The case report is appropriate as a teaching guide for optometry students at all levels. It provides a thorough review of conjunctival anatomy and physiology along with explanations of key findings, common clinical presentations, differential diagnoses, epidemiology, pathophysiology, risk factors, treatment and management options and prognosis for conjunctival lymphoma. Although conjunctival lymphomas are typically slow-growing, unilateral and rarely metastatic, students and facilitators are reminded that early diagnosis is critical to minimize the need for aggressive treatment and to optimize patient prognosis.

Case Description

An initially asymptomatic 24-year-old Asian male was referred to Eye Care Institute at Western University of Health Sciences (Pomona, CA) for evaluation of multiple long-standing large follicles in the inferior conjunctiva of both eyes and newly noted salmon-colored gelatinous masses located in the inferior fornix of both eyes. The patient's systemic history included seasonal allergies and eczema. His family medical history was positive for an unknown stomach lymphoma in his paternal grandmother. His ocular history included chronic allergic conjunctivitis in both eyes. The patient denied any significant family ocular history. He reported no current medications. The patient indicated drug allergies to erythromycin, neomycin, fluorometholone and loteprednol, the latter two having been used recently to treat his suspected allergic conjunctivitis, which was unresponsive to more conservative therapy.

His best-corrected visual acuity was 20/20 in each eye. Slit-lamp examination revealed salmon-pink gelatinous masses in the inferior fornix of each eye (**Figures 1A and 1B**). The remainder of the examination was normal. The patient denied any known history of a recent viral illness, and preauricular, submandibular and cervical lymphadenopathy were absent. The patient was referred to a corneal specialist for a conjunctival biopsy.

Bilateral conjunctival biopsies were performed at Pacific Eye Care Institute (Upland, CA). The biopsy

report showed a population of small- to medium-sized lymphocytes with high nuclear to cytoplasmic ratio, clumped chromatin with inconspicuous nucleoli and rounded nuclear contours with mildly irregular and clefted centrocytes. The cytoplasm was moderate to abundant with absence of necrotic debris. Immunohistochemistry stains showed population of neoplastic B-cells that were positive for BCL-2 and CD20, and lambda light chain restriction was found. The immunohistochemistry stains were negative for CD3, CD5, CD10, CD23 and CD43 markers. These histopathological findings were consistent with mucosa-associated lymphoid tissue (MALT) lymphoma.

The patient was referred to the hematology department at Keck Medicine of USC (Los Angeles, CA) for an extensive evaluation including full-body computed tomography (CT) and magnetic resonance imaging (MRI) of the head. Both were negative for active tissue beyond the orbit. The patient was referred to the radiation department at Keck Medicine of USC for treatment. External beam radiation therapy (EBRT, 16 treatments of 1.5 Gy for a total of 24 Gy) was delivered to both orbits.

Therapy was relatively well-tolerated. The patient experienced ocular dryness, which was successfully addressed with artificial tears. No changes in vision, eyelid edema or erythema, or other symptoms were noted. The patient had been followed closely after radiation treatment, and no evidence of disease recurrence had been seen by the time of this publication (**Figure 2**).



Educator's Guide

Learning objectives

At the end of this case discussion, readers should be able to:

1. Identify the anatomical zones and main functions of the conjunctiva
2. List appropriate differential diagnoses for a suspicious conjunctival mass
3. Explain common assessment strategies for a conjunctival mass
4. Describe the epidemiology, pathophysiology and risk factors associated with conjunctival lymphoma
5. Describe key findings for conjunctival lymphoma
6. Explain common treatment and management strategies for conjunctival lymphoma
7. Describe the necessary systemic evaluation following a diagnosis of conjunctival lymphoma
8. Discuss the expected prognosis and common complications for patients treated with EBRT for conjunctival lymphoma

Key concepts

1. Recognize concerning signs of suspicious conjunctival masses
2. Describe an abnormal conjunctival mass in a systematic manner
3. List common assessment strategies for a conjunctival mass
4. Recognize characteristic signs of conjunctival lymphoma
5. Identify possible ocular complications associated with radiation therapy

Discussion questions

1. Knowledge and concepts required for critical review of the case
 - a. what are the histological features of the conjunctiva?
 - b. what anatomical structures are located within the conjunctiva?
 - c. list the functions of the conjunctiva
 - d. how do you systematically describe a conjunctival mass?
 - e. describe the epidemiology, pathophysiology and risk factors associated with conjunctival lymphoma
 - f. describe key clinical findings in patients with conjunctival lymphoma
 - g. describe systemic complications associated with conjunctival lymphoma
2. Differential diagnoses
 - a. list the main concerning and characteristic signs of a suspicious conjunctival mass
 - b. list appropriate differential diagnoses for a suspicious conjunctival mass
 - c. what assessment strategies are helpful in formulating a differential diagnosis?
3. Disease treatment and management
 - a. which specialists should you involve in the care of a patient with a suspicious conjunctival mass?
 - b. what is the appropriate timeline to refer patients with suspicious conjunctival lesions to the necessary specialist(s)?
 - c. what is the gold standard for the treatment of localized conjunctival lymphoma?
 - d. list alternative/additional treatment strategies and discuss the rationale behind each
 - e. discuss the most likely prognosis and possible complications following treatment of patients with conjunctival lymphoma
 - f. what is the follow-up schedule for patients with suspected and confirmed conjunctival lymphoma?
 - g. what are potential ocular complications associated with radiation therapy?
4. Patient education
 - a. how would you educate the patient regarding your suspected diagnosis?
 - b. what is the most likely long-term prognosis for this patient?
5. Critical thinking
 - a. how would you have managed this case? Justify your answer based on the findings

- b. what would have been a sign of poor prognosis?

Learning activity

1. Assign the case with selected discussion questions as homework during the Anterior Segment Disease course or as part of the clinical assignment
2. Require students to provide at least 2-4 recent, peer-reviewed articles to support their answers
3. Block off 1-2 hours during class or clinic time to allow students to present their answers and learn from each other; encourage questions from other students by providing participation credit incentives

Learning assessment

1. Assess knowledge regarding conjunctival lymphoma and differential diagnoses by use of multiple-choice and/or short-answer questions
2. Facilitate demonstration of clinical skills associated with anterior segment slit lamp examination including systematically describing abnormal clinical findings
3. Incorporate the case into clinical or didactic discussions

Discussion

Identify anatomical zones and main functions of the conjunctiva

The conjunctiva is a thin, translucent mucous membrane that starts at the eyelid edge between the outer and inner canthi and extends from the inner surface of the eyelids (i.e., palpebral or tarsal region) to the corneoscleral limbus on the globe (i.e., bulbar conjunctiva).¹ The conjunctival fornix connects the palpebral and bulbar sections. The conjunctiva is composed of non-keratinized stratified columnar-cuboidal epithelium overlying a layer of loose connective tissue termed the conjunctival substantia propria.² Nerves, blood vessels, lymphocytes, mast, goblet and Langerhans cells, and the Wolfring and Krause accessory glands are located within the conjunctiva.³ It is crucial to highlight that lymphocytes are found in the superficial layer of the lamina propria, thus making up the MALT, i.e., the tissue that undergoes malignant transformation in conjunctival lymphoma. This is precisely the anatomic reason why conjunctival lymphoma presents as a mobile salmon-pink mass in the palpebral conjunctival fornices and why it can potentially metastasize to other parts of the body via lymph node dissemination.

Functions of the conjunctiva include:⁴

1. Protecting the orbit from the external environment
2. Facilitating movement of the eyelids and globe
3. Contributing to the immune defense system (e.g., secreting antibodies and antimicrobial proteins, and mediating cellular responses)
4. Supporting the optical function of the cornea
5. Tear secretion

List differential diagnoses for a conjunctival mass

While patients with a conjunctival mass can present with complaints of irritation, pain, discharge, epiphora and photophobia,^{5,6} most are asymptomatic. Thus, the initiation of the differential diagnostic process for an abnormal conjunctival mass is based on key signs, with a focus on concerning signs associated with possible malignancy. It is critical to highlight that lesion appearance should raise red flags for urgent investigation, but that the definitive diagnosis of a conjunctival lymphoma is ultimately determined via tissue biopsy. Nevertheless, students can follow a rule that is used to summarize clinical features of melanoma as a structured and systematic description of an amelanotic conjunctival mass and

the initial groundwork for differential diagnoses. Known as the “ABCDEF” rule,⁷ the acronym stands for:

- Asymmetry
- Border irregularity
- Color variation: both intralesional and interlesional
- Diameter: greater than 6 mm is more concerning for possible melanoma
- Evolving: new or changing lesion
- Funny-looking: unlike other lesions

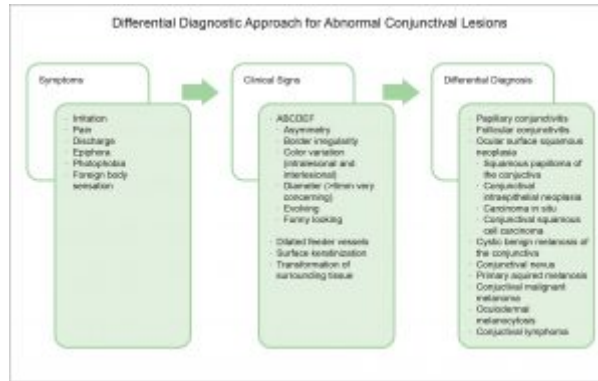


Figure 3. [Click to enlarge](#)

Other concerning signs of a suspicious conjunctival mass include the presence of dilated feeder vessels, leukoplakia (surface keratinization) and transformation of surrounding tissue.⁸⁻¹⁰ **Figure 3** provides a summary of the differential diagnostic approach for abnormal conjunctival lesions.

Conjunctival lymphoma can present with asymmetry, irregular borders, color variation, larger diameter, signs of evolution and “funny-looking” characteristics. More specific key signs for a conjunctival lymphoma include the presence of a fleshy, vascularized, salmon-colored/fish-flesh swollen patch that is freely mobile and usually unilateral.² While definitive diagnosis is made through conjunctival biopsy with histopathologic examination, differential diagnoses for a conjunctival mass include:

- Papillary conjunctivitis
- Follicular conjunctivitis
- Ocular surface squamous neoplasia
- Squamous papilloma of the conjunctiva
- Conjunctival intraepithelial neoplasia (CIN)
- Carcinoma in situ
- Conjunctival squamous-cell carcinoma (SCC)
- Cystic benign melanosis (CBM) of the conjunctiva
- Conjunctival nevi
- Primary acquired melanosis (PAM)
- Conjunctival malignant melanoma (CMM)
- Oculodermal melanocytosis (ODM) or Nevus of Ota
- Conjunctival lymphoma



Table 1. [Click to enlarge](#)

Table 1 outlines key characteristics associated with these common conjunctival abnormalities.

Explain common assessment strategies for a conjunctival mass

Clinical descriptions of color, size, shape, consistency, symmetry, pigmentation, borders, elevation, presence of feeder vessels and exact anatomic location — whether conjunctival, subconjunctival or fixed to the globe — are crucial for distinguishing between diagnoses.¹¹ Assessment of the extent of the mass in the exam room can include:

- Cotton-tipped applicator wetted with topical anesthetic drop: easy movement implies localization to the conjunctiva
- Slit lamp biomicroscopy: clinical descriptions should include encroachment onto the cornea; evaluation involving eyelid elevation and ocular rotation is instrumental because masses can be hidden under the eyelid or in the fornix
- Gonioscopy: to assess the degree of intraocular angle involvement
- Lymph node examination: preauricular, submandibular and upper deep cervical lymph node examination is important to assess the presence and degree of lymph node involvement and disseminated disease

Ultrasound biomicroscopy, CT scans and/or MRI scans focusing on the anterior orbit, with gadolinium enhancement using 2-mm cuts, may also be considered to assess the degree of globe involvement and, with CT and MRI, possible orbital extension. Because it can be difficult to establish a diagnosis based on clinical examination alone, impression cytology, in-vivo confocal microscopy and/or biopsy with a systemic evaluation is usually necessary.

Describe the epidemiology, pathophysiology and risk factors associated with conjunctival lymphoma

Lymphoma is a malignant neoplasm stemming from a monoclonal proliferation of B-lymphocytes, T-lymphocytes and, rarely, natural killer cells.² Lymphoma may be divided into two types: Hodgkin and non-Hodgkin. MALT lymphoma is a subtype of non-Hodgkin lymphoma.²⁰ Conjunctival lymphoma constitutes approximately 25% of all ocular adnexal lymphoma and falls into the following subtypes, ranked in order of frequency: extranodal marginal zone lymphoma (EMZL; 96% of cases), follicular lymphoma, diffuse large B-cell lymphoma, and mantle-cell lymphoma.² Conjunctival lymphoma is the most common primary neoplasm²¹ and has been found in approximately 30% of patients with disseminated lymphoma.^{22,23} Although conjunctival lymphoma tends to be slow-growing, unilateral and indolent, systemic metastasis is seen in approximately 20% of patients; risk of metastasis increases in patients with a bilateral presentation; and the incidence of MALT ocular lymphoma is rising.^{22,23}

While conjunctival lymphoma is primarily seen in the elderly, it has been described in individuals as young as 33 months; trends have been identified regarding subtypes based on age, gender and pathogenesis. Chronic antigenic stimulation from pathogens including *Helicobacter pylori*, *Chlamydia psittaci* and hepatitis C² has been associated with conjunctival EMZL. Autoimmune disorders such as Sjögren syndrome,²⁴ systemic lupus erythematosus²⁵ and Hashimoto thyroiditis²⁶ have also been implicated in the pathogenesis of conjunctival EMZL. Additionally, chronic exposure to bioactive solvents and reagents²⁷ and genetic abnormalities such as translocations, inactivating mutations and trisomies² have been suspected to be related to conjunctival EMZL.

Describe key findings for conjunctival lymphomas

Patients report few symptoms because conjunctival MALT lymphoma lacks a connective tissue stroma and is thus able to mold to surrounding tissue without causing ocular irritation.¹¹ Therefore, careful slit lamp examination is crucial for identification of the malignant lesions. Characteristic findings of conjunctival lymphoma identified during slit lamp biomicroscopy include the presence of a fleshy, vascularized, salmon-pink patch that is readily movable.² Because differentiating between benign inflammation and a malignant lymphoid tumor is challenging based on clinical exam alone, patient referral for biopsy with histopathologic examination is necessary for a definitive diagnosis.¹⁹

Explain common treatment and management strategies for conjunctival lymphoma

The main roles of primary care optometry in the care of a patient with a conjunctival lymphoma include:

1. Identifying and describing clinical findings
2. Appropriately educating the patient regarding clinical suspicion and planning; while the level of detail is dependent on clinical findings and characteristics of both the provider and patient, a focus on providing the correct amount and type of information, aiding accurate recall and understanding, incorporating the patient's perspective, and ensuring shared decision-making are important²⁸
3. Referring the patient for further evaluation including consideration for a conjunctival biopsy with an ophthalmologist, specifically a corneal specialist because others may not have the appropriate resources or experience

While no specific guidelines exist regarding the ideal timeline to refer patients for biopsy, a prompt referral with increasing urgency based on more suspicious clinical findings is appropriate. The initial referral for conjunctival biopsy should be made to an oculoplastic or corneal specialist. Pathology should also likely be involved to provide definitive diagnosis before involvement with hematology, radiology and other specialties for staging and initiating treatment.

Isolated conjunctival MALT lymphoma is most often treated by radiology with EBRT²⁹ with or without chemotherapy. EBRT is highly effective and is the current gold standard treatment, with a complete remission rate of 86-100% and a five-year overall survival rate for approximately 94%.¹¹ While no specific consensus has emerged regarding the optimal planning target volume of radiotherapy for treating patients with conjunctival lymphoma, the normal EBRT dose range is 15-45 Gy.² Including the entire conjunctiva and eyelid within the treatment area has been recommended because the conjunctiva has intrinsic lymphoid tissue.²⁹ Alternative treatment methods include chemotherapy, immunotherapy with monoclonal antibodies and/or interferon- γ , brachytherapy, complete excision, cryotherapy and careful observation.² Single-agent or combination chemotherapy is typically used for patients with disseminated disease,²² and there is a recent movement towards use of monoclonal antibody therapy for better local control, less tissue toxicity and better overall systemic control compared to orbital radiotherapy.²¹ Other variables that can influence management include the patient's symptoms, ocular surface health and quality of life.

Describe the systemic evaluation associated with a diagnosis of conjunctival lymphoma

Conjunctival lymphoma presents with co-existing systemic lymphoma in approximately one-third of patients.²¹⁻²³ Thus, if the diagnosis of conjunctival lymphoma is confirmed, a thorough clinical examination is necessary. It is necessary to include basic hematologic screening tests (complete blood count, white blood cell differential, serum immunoprotein electrophoresis), full-body positron emission tomography and CT or MRI, and bone marrow biopsy.^{2,21} A gastrointestinal endoscopy is also recommended for patients with MALT lymphoma because gastrointestinal tract involvement is frequent.³⁰ Characteristics of conjunctival lymphoma that increase the risk for disseminated systemic lymphoma include fornicial or mid-bulbar location, multifocality and bilaterality.²³

Discuss the expected prognosis and common complications for patients treated with EBRT for conjunctival lymphoma

Successful treatment of conjunctival lymphoma generally has a very good prognosis regardless of type.² Low-grade B-cell NHL carries the best prognosis followed by EMZL in which only 9% of patients experience progression or recurrence within the first year of treatment.² T-cell NHL has the worst prognosis. Specifically, while 90% of conjunctival lymphoma cases do not progress or recur within the first year of treatment, a staggering 50% of patients with T-cell NHL undergo progression or recurrence

of the cancer. Other factors that influence prognosis include stage of the cancer, patient age, and non-bulbar location of the lesion. Standard follow-up is every three months for the first year followed by every six to 12 months thereafter.²² It has been suggested that response to treatment, specifically a slow response to radiotherapy, may be associated with the development of metachronous lesions so more frequent follow-up may be required for such patients.²⁹

Common complications for patients treated with EBRT for conjunctival lymphoma include xerophthalmia, keratitis, cataract and retinal damage.¹¹ Such complications are important to discuss and address with patients. For example, lens shielding can minimize cataract development,²⁹ and continued follow-up is needed.

Prognosis of untreated conjunctival MALT lymphoma

While conjunctival lymphoma is rarely lethal, and tumors tend to remain confined to the involved conjunctiva, systemic spread via lymph node infiltration, systemic dissemination to extranodal organs, and contralateral conjunctival involvement can occur, particularly if the cancer is left untreated. If systemic lymphoma develops, the prognosis is determined mainly by the grade of the lymphoma.

Conclusion

Though relatively uncommon, conjunctival lymphoma can present in young adults. Careful clinical evaluation using appropriate assessment strategies is critical to identify concerning conjunctival masses. It is important to promptly involve appropriate specialists to definitively diagnose, treat and manage this cancer because delays may lead to systemic dissemination, a more complicated treatment and poorer prognosis.

References

1. Remington LA. Clinical anatomy of the visual system. St. Louis, MO: Elsevier; 2005.
2. Kirkegaard MM, Coupland SE, Prause JU, Heegaard S. Malignant lymphoma of the conjunctiva. *Surv Ophthalmol.* 2015;60(5):444-58. Epub 2015/05/25. doi: 10.1016/j.survophthal.2015.05.001. PubMed PMID: 26003619.
3. Yanoff M, Fine B. Conjunctiva. In: Yanoff M, Fine B, editors. *Ocular pathology*. St. Louis, MO: Mosby; 2002.
4. Sehu K, Lee WK. *Ophthalmic pathology: an illustrated guide for clinicians*. Oxford: BMJ Books/Blackwell Pub; 2005.
5. Mehta M, Fay A. Squamous cell carcinoma of the eyelid and conjunctiva. *Int Ophthalmol Clin.* 2009;49(1):111-21. Epub 2009/01/07. doi: 10.1097/IIO.0b013e3181928fb9. PubMed PMID: 19125070.
6. Yumori JW, Ilsen P, Bright DC. Conjunctival plasmacytoma. *Optometry.* 2010;81(5):234-9. Epub 2010/05/04. doi: 10.1016/j.optm.2009.11.006. PubMed PMID: 20435269.
7. Jensen JD, Elewski BE. The ABCDEF rule: combining the "ABCDE rule" and the "ugly duckling sign" in an effort to improve patient self-screening examinations. *J Clin Aesthet Dermatol.* 2015;8(2):15. Epub 2015/03/06. PubMed PMID: 25741397. PubMed Central PMCID: PMC4345927.
8. Hamam R, Bhat P, Foster CS. Conjunctival/corneal intraepithelial neoplasia. *Int Ophthalmol Clin.* 2009;49(1):63-70. Epub 2009/01/07. doi: 10.1097/IIO.0b013e3181924ec3. PubMed PMID: 19125065.
9. Laird PW, Woodward MA, Williams JG, Lee WB, Grossniklaus HE. Cystic benign melanosis of the conjunctiva. *Cornea.* 2012;31(11):1273-7. Epub 2012/10/10. doi: 10.1097/ICO.0b013e31823d1ec4. PubMed PMID: 23044615. PubMed Central PMCID: PMC43467456.

10. Oellers P, Karp CL. Management of pigmented conjunctival lesions. *Ocul Surf*. 2012;10(4):251-63. Epub 2012/10/23. doi: 10.1016/j.jtos.2012.08.002. PubMed PMID: 23084146.
11. Othman IS. Ocular surface tumors. *Oman J Ophthalmol*. 2009;2(1):3-14. Epub 2009/01/01. doi: 10.4103/0974-620X.48415. PubMed PMID: 21234217. PubMed Central PMCID: PMC3018103.
12. American Academy of Ophthalmology. Papillary versus follicular conjunctivitis 2018 [cited 2018 June 5th]. Available from: <https://www.aao.org/bcscsnippetdetail.aspx?id=9d2ac3f7-43cb-4096-9c26-3c7b6d052e20>
13. Sjo N, Heegaard S, Prause JU. Conjunctival papilloma. A histopathologically based retrospective study. *Acta Ophthalmol Scand*. 2000;78(6):663-6. Epub 2001/02/13. PubMed PMID: 11167228.
14. Huang YM, Huang YY, Yang HY, et al. Conjunctival papilloma: clinical features, outcome, and factors related to recurrence. *Taiwan J Ophthalmol*. 2018;8(1):15-8. Epub 2018/04/21. doi: 10.4103/tjo.tjo_2_18. PubMed PMID: 29675344. PubMed Central PMCID: PMC5890578.
15. Crim N, Fornies-Paz ME, Monti R, Esposito E, Maccio JP, Urrets-Zavalía JA. In situ carcinoma of the conjunctiva: surgical excision associated with cryotherapy. *Clin Ophthalmol*. 2013;7:1889-93. Epub 2013/10/05. doi: 10.2147/OPTH.S50762. PubMed PMID: 24092968. PubMed Central PMCID: PMC3788814.
16. Ong SS, Vora GK, Gupta PK. Anterior segment imaging in ocular surface squamous neoplasia. *J Ophthalmol*. 2016;2016:5435092. Epub 2016/11/02. doi: 10.1155/2016/5435092. PubMed PMID: 27800176. PubMed Central PMCID: PMC5069377.
17. Swann PG, Kwong E. The naevus of Ota. *Clin Exp Optom*. 2010;93(4):264-7. Epub 2010/06/11. doi: 10.1111/j.1444-0938.2010.00484.x. PubMed PMID: 20533926.
18. Plateroti AM, Scavella V, Abdolrahimzadeh B, Plateroti R, Rahimi S. An update on oculodermal melanocytosis and rare associated conditions. *Semin Ophthalmol*. 2017;32(4):524-8. Epub 2016/04/16. doi: 10.3109/08820538.2015.1118133. PubMed PMID: 27083007.
19. Shields CL, Kels JG, Shields JA. Melanoma of the eye: revealing hidden secrets, one at a time. *Clin Dermatol*. 2015;33(2):183-96. Epub 2015/02/24. doi: 10.1016/j.clindermatol.2014.10.010. PubMed PMID: 25704938.
20. Swerdlow S, Campo E, Harris N. WHO classification of tumours of haematopoietic and lymphoid tissues. 4th edition ed. Lyon: IARC Press; 2008.
21. Hatfegul E, Roberts D, McLaughlin P, Pro B, Esmaeli B. Prevalence and nature of systemic involvement and stage at initial examination in patients with orbital and ocular adnexal lymphoma. *Arch Ophthalmol*. 2007;125(12):1663-7. Epub 2007/12/12. doi: 10.1001/archophth.125.12.1663. PubMed PMID: 18071119.
22. Sein J, Stefanovic A, Karp C. Diagnosis and treatment of conjunctival lymphoma 2012 [cited 2018 Sept 12, 2018]. Available from: <https://www.aao.org/eyenet/article/diagnosis-treatment-of-conjunctival-lymphoma/>.
23. Honavar SG, Manjandavida FP. Tumors of the ocular surface: a review. *Indian J Ophthalmol*. 2015;63(3):187-203. Epub 2015/05/15. doi: 10.4103/0301-4738.156912. PubMed PMID: 25971163. PubMed Central PMCID: PMC4448231.
24. Bjerrum KB. Primary Sjogren's syndrome and keratoconjunctivitis sicca: diagnostic methods, frequency and social disease aspects. *Acta Ophthalmol Scand Suppl*. 2000(231):1-37. Epub 2002/01/05. PubMed PMID: 11763500.
25. Arevalo JF, Lowder CY, Muci-Mendoza R. Ocular manifestations of systemic lupus erythematosus. *Curr Opin Ophthalmol*. 2002;13(6):404-10. Epub 2002/11/21. PubMed PMID: 12441845.
26. Hyjek E, Isaacson PG. Primary B cell lymphoma of the thyroid and its relationship to Hashimoto's thyroiditis. *Hum Pathol*. 1988;19(11):1315-26. Epub 1988/11/01. PubMed PMID: 3141260.
27. American Academy of Ophthalmology. Orbit, eyelids, and lacrimal system, section 7. San Francisco: American Academy of Ophthalmology; 2014.
28. Kurtz S, Silverman J, Benson J, Draper J. Marrying content and process in clinical method

teaching: enhancing the Calgary-Cambridge guides. *Acad Med.* 2003;78(8):802-9. Epub 2003/08/14. PubMed PMID: 12915371.

29. Uno T, Isobe K, Shikama N, et al. Radiotherapy for extranodal, marginal zone, B-cell lymphoma of mucosa-associated lymphoid tissue originating in the ocular adnexa: a multiinstitutional, retrospective review of 50 patients. *Cancer.* 2003;98(4):865-71. Epub 2003/08/12. doi: 10.1002/cncr.11539. PubMed PMID: 12910532.
30. Niksirat H, Sarvi K, Amiri BM, Karami M, Hatef A. In vitro storage of unfertilized ova of endangered Caspian brown trout (*Salmo trutta caspius*) in artificial media. *Anim Reprod Sci.* 2007;100(3-4):356-63. Epub 2006/09/22. doi: 10.1016/j.anireprosci.2006.08.019. PubMed PMID: 16987621.

Dr. Wong Yumori [jyumori@westernu.edu] is an Associate Professor at Western University of Health Sciences College of Optometry.

Dr. Jakirlic is an Assistant Professor at Western University of Health Sciences College of Optometry.

Dr. Van, a graduate of Western University of Health Sciences College of Optometry, practices in the Los Angeles area.