Retention of Knowledge of Retinal Microanatomy by Optometric Students, Faculty and Practitioners

Barclay W. Bakkum, DC, PhD
Ruth A. Trachimowicz, OD, PhD, FAAO

Abstract

The purpose of this study was to identify the ability of fourth-year optometric students and clinical faculty members at an optometric college (including residents) and a cohort of private practice optometrists to label the 10 layers of the retina on a diagram. The private practitioners were least proficient in identifying the retinal layers. The faculty optometrists performed better. The students did the best. With increased use of advanced imaging technologies, optometrists may need to become increasingly proficient in retinal microanatomy. Basic and clinical science concepts should be correlated not only throughout optometric school curricula but also in continuing education courses.

Key Words: *anatomy, retina, optical coherence tomography, long-term learning, optometry, education*

Dr. Bakkum is an Associate Professor of Biological Sciences at the Illinois College of Optometry.
Dr. Trachimowicz is an Associate Professor of Optometry at the Illinois College of Optometry.

Introduction

Anatomy can be considered one of the basic pillars of medical training. Recent evidence has shown that although some areas of patient management differ in relevancy to anatomical education, some areas of clinical care are uniformly ranked as relying heavily on anatomical knowledge, e.g., imaging and diagnostic studies, physical examination and arrival at correct diagnosis.[1] A recent study of clinicians indicated that they generally agree that anatomy is "fundamental" to daily clinical practice.[2]

Typically, anatomy is taught in the first year of medical school, but most of the clinical application of this knowledge does not usually occur until the third or fourth years of the curriculum, during clinical rotations and in clinical training after graduation. Studies have shown that there is a considerable loss of anatomical knowledge among medical students within a year after completing their anatomy studies[3] and that specific radiologic anatomy information was "poorly retained" by fourth-year medical students.[4]

Several studies have used labeling the carpal bones on a diagram of the hand to assess retention of anatomical knowledge. The anatomy of the carpal bones was chosen as a benchmark for anatomical knowledge because it is easily and objectively examined and has relevance to clinical practice in a number of disciplines.[5] One study using this task compared the performance of medical students with the performance of junior doctors.[5] The overall recognition scores achieved by medical students were "poor" [4 of 25 (16%) of the students could identify seven or eight of the bones]; however, the junior doctors' scores were "more reassuring" [7 of 10 (70%) could do the same]. In another study, physical therapy students exhibited better retention of the anatomy of the carpal bones than medical students.[6] In that study, 23 of 54 (42%) of the physical therapy students vs. 16 of 80 (20%) of the medical students could identify all eight carpal bones. It has also been shown that the results of chiropractic students on the carpal bone test was generally better than those of previously tested final-year medical students, although only 32 of 84 (38%) of

the chiropractic students identified all eight bones.[7] Another study asked 102 junior doctors in accident and emergency and orthopedic departments to identify nine wrist landmarks by palpation on normal wrists and name the carpal bones on plain film radiographs.[8] None of the subjects identified all nine wrist landmarks using palpation and only 61 of 102 (60%) could name all eight carpal bones on a plain film radiograph.

A search of the literature found no published studies concerning the retention of pertinent anatomical knowledge by optometric students or doctors of optometry. With the development of advanced imaging techniques with increasingly better resolution, knowledge of microscopic anatomy is becoming more and more important in clinical practice. An example of this is optical coherence tomography (OCT). OCT has a variety of applications in clinical practice.[9] One of the most common uses of OCT, especially spectral domain OCT (SD-OCT), is in eye care, where it can produce high-resolution cross-sectional images of the subsurface retina, with resolutions that allow differentiation of all retinal layers from the internal limiting membrane to the retinal pigmented epithelium. OCT is used to detect and monitor macular diseases including age-related macular degeneration (AMD), retinal vein occlusion, diabetic retinopathy, macular holes, epiretinal membranes and other disorders of the vitreoretinal interface.[10] It is especially helpful in quantifying and monitoring macular thickness in diseases that cause macular edema or subretinal fluid accumulation.[11] Experts in the field consider OCT to be an essential part of the diagnosis and follow-up of patients with diabetic macular edema (DME) and AMD.[12] Some think that OCT-guided treatment for chronic conditions such as AMD and macular edema can be considered a de facto standard of care.[13] SD-OCT is one of the objective tests recommended by the American Academy of Ophthalmology for the screening of chloroquine and hydroxychloroquine retinopathy.[14] The International Vitreomacular Traction Group has developed an OCT-based anatomic classification system for diseases of the vitreomacular interface, i.e., vitreomacular adhesion, vitreomacular traction and macular holes.[15]

Given the increased use of OCT in eye care, it was hypothesized that identifying the 10 layers of the retina on a diagram could be a comparable benchmark for anatomical knowledge for those in the optometric profession. Therefore, the purpose of this study was to identify the ability of fourth-year optometric students and clinical faculty members at an optometric college (including residents) and a cohort of private practice optometrists to label the 10 layers of the retina on a diagram.

Methods

Subjects were recruited from the fourth-year student population and the clinical faculty having an optometry degree (including residents) at the Illinois College of Optometry (ICO) and from among private practice optometrists who participated in a continuing education (CE) program at ICO. Inclusion in the study was based on the subject's willingness to participate in the study and his/her attendance at the venue where the test was administered. Fourth-year students were tested at the end of grand rounds (where retinal cases were not discussed); faculty members were tested during a faculty retreat; and the private practitioners were tested at a CE program held at the college. Subjects who had prior knowledge of the task involved in the study were excluded to allow a fair representation of subjects' level of knowledge without prior preparation.

After an IRB-approved consent process, subjects (the faculty members and private practice optometrists) were asked to report the number of years since they graduated and any optometric specialties they considered themselves to have, e.g., primary care, contact lenses, pediatrics, low vision or a combination of these specialties. They were allowed five minutes maximum to label the layers of the retina on a line drawing provided to them (**Figure 1**). Abbreviations were not allowed. The test was given without prior warning. At least one of the authors was present when the test was administered.

Data were recorded and tallied in Excel spreadsheets. Descriptive data, including percentages, means and standard deviations, were calculated where appropriate. A one-way analysis of variance (ANOVA) was calculated for both

Figure 1
Histologic Cross-Sectional Image of the Retina Used as the Task in the Study



the average number of layers correctly identified and years since graduation, and post hoc analysis was performed with the Games-Howell test. Chi squares were calculated for both the percentage of times each layer was correctly identified and percentage of answers that were blank or non-retina. All statistics were computed using SPSS, V17.0 (Chicago, IL).

Results

A total of 172 participants were recruited for this study: 35 fourth-year optometry students out of approximately 40 that attended the grand rounds, 41 clinical faculty members (including nine residents) out of approximately 45 that attended the session of the retreat, and 96 private practice optometrists out of approximately 225 that attended the CE program. The number of years since graduation and the self-selected specialty information for clinical faculty members and private practice optometrists are shown in **Figures 2 and 3**, respectively.

The students had the best performance on the task, followed by the clinical faculty members and then the private practice optometrists (**Figure 4**). The mean number of layers correctly identified differed significantly by group ($F=69.2$, $p<0.05$). In general, for both groups of optometrists, the more time since the subject graduated, the fewer layers that were correctly identified (**Figure 5**). The number of years since graduation significantly affected performance ($F=9.7$, $p<0.05$). The outermost and innermost layers (i.e., retinal pigmented epithelium and inner limiting membrane, respectively) were correctly identified most commonly (**Figure 6**). There were significant differences between the groups in identifying the remaining layers ($\chi^2=39.4$, $p<0.05$). The group that had the most subjects that either left the task completely blank or had non-retina answers was the private practice optometrists, followed by the clinical faculty members and then the students (**Figure 7**). The numbers of subjects in these groups that either left the task blank or had non-retina answers were significantly different from each other ($\chi^2=9.51$, $p<0.05$).

Figure 2
Number of Years Since Graduation for Clinical Faculty Members and Private Practice Optometrists

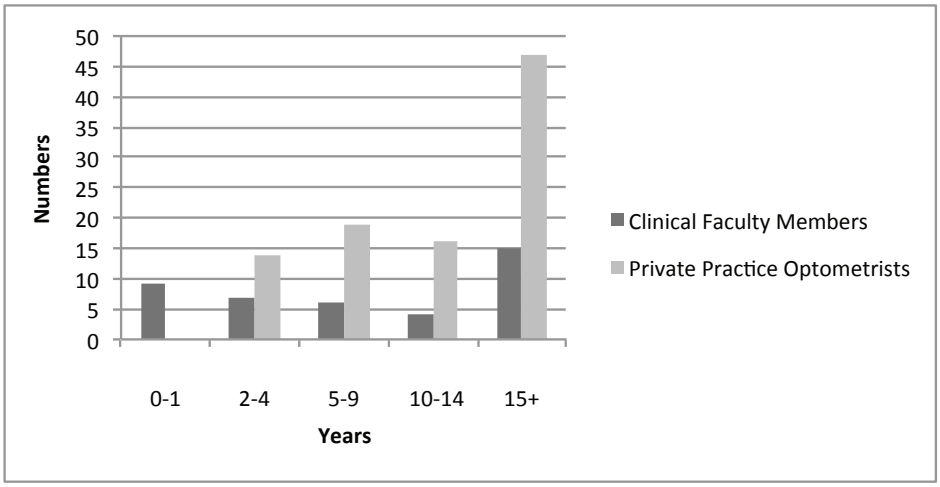

Figure 3
Self-Selected Specialty for Clinical Faculty Members and Private Practice Optometrists

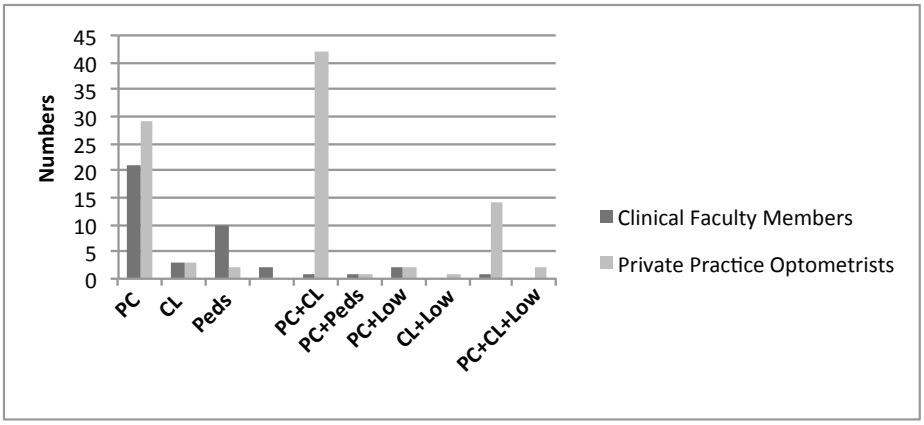

PC: primary care; CL: contact lenses; Peds: pediatrics; Low: low vision.

Figure 4
Average Number of Retinal Layers Correctly Identified

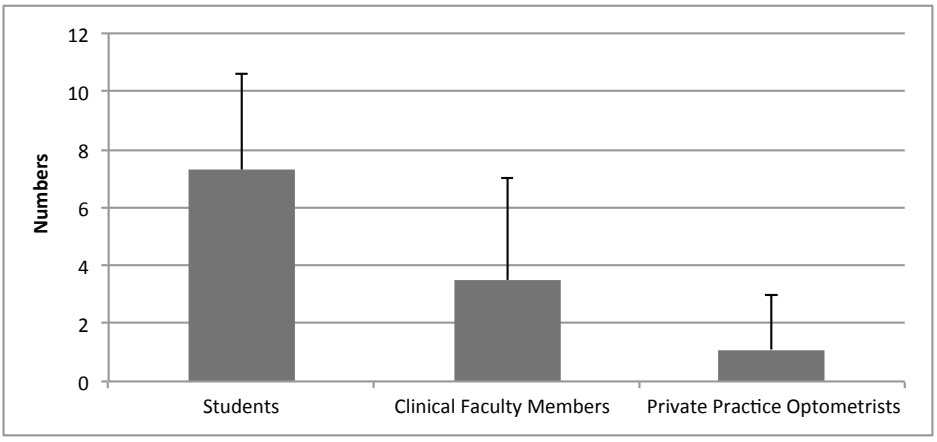

Error bars show standard deviations.

Figure 5
Average Number of Retinal Layers Correctly Identified

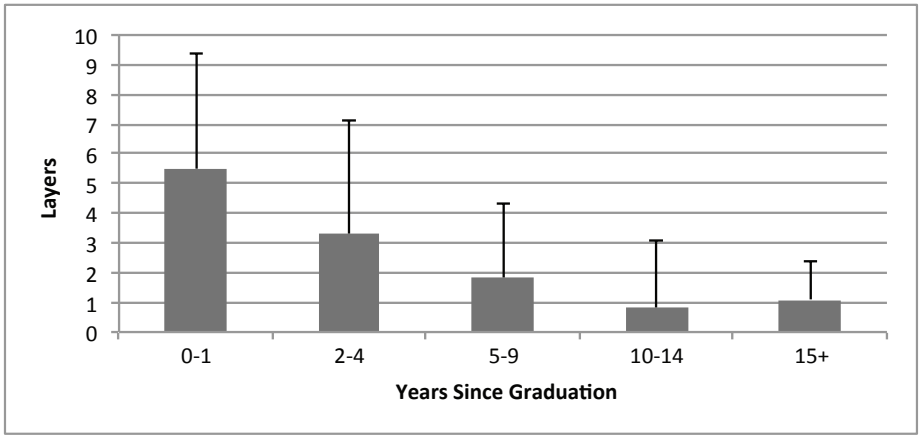

Error bars show standard deviations.

Figure 6
Percentage of Times Each Layer was Correctly Identified*

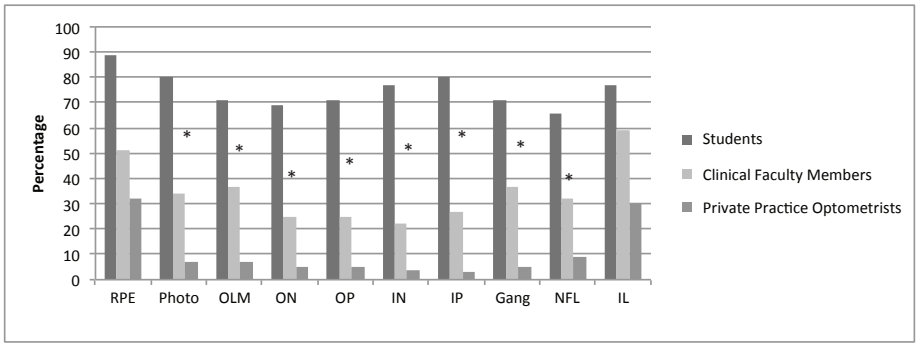

RPE: retinal pigmented epithelium; Photo: photoreceptor layer; OLM: outer limiting membrane; ON: outer nuclear layer; OP: outer plexiform layer; IN: inner nuclear layer; IP: inner plexiform layer; Gang: ganglion cell layer; NFL: nerve fiber layer; IL: inner limiting membrane.

** $p<0.05$.*

Figure 7
Percentage of Answer Sheets Left Completely Blank or Containing Non-Retina Answers

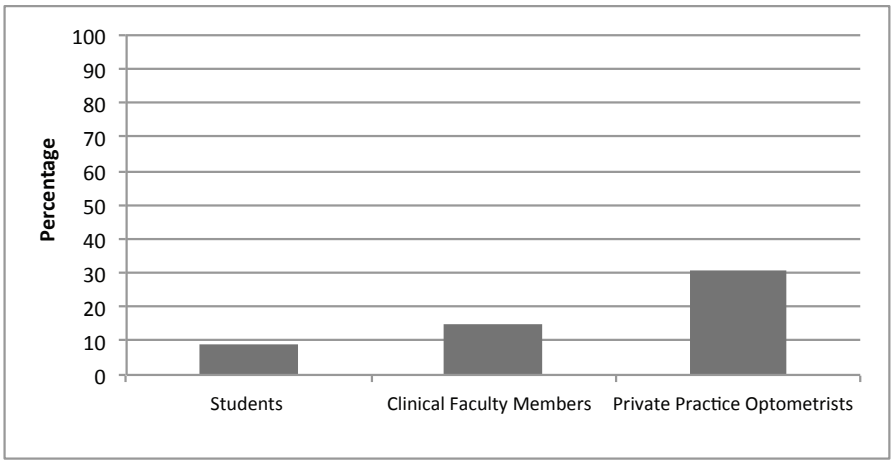

Discussion

About half (47 of 96) of the private practice optometrists group had graduated more than 15 years before the study. Likewise, if the residents are not counted, almost half (15 of 32) of the clinical faculty cohort had graduated more than a decade and a half ago.

The private practice optometrists appeared more likely to consider themselves experts in more than one specialty as compared to the clinical faculty optometrists. Nearly two-thirds (62 of 96) of the private practitioners classified themselves as experts in more than one specialty, while approximately 10% (5 of 41) of the faculty optometrists did so.

The private practice optometrists were least proficient in identifying the retinal layers. The clinical faculty members performed better. The students, who were preparing for national board exams, did the best. The results of this study suggest that specific knowledge of the retinal layers is not uniform across the groups in this study cohort.

Because time since graduation had a significant effect on the number of layers labeled correctly, it is not surprising that the two groups of optometrists did not perform as well as the students. This may be especially true because the students had studied the information more recently in class and were also preparing for national board examinations.

The innermost and outermost layers of the retina were the ones that were most frequently identified correctly. This may not be too surprising because these layers may have the most frequent clinical significance. This identification pattern is most clearly seen for the two optometrist groups. The student cohort data did not really show this pattern, although the retinal pigmented epithelium was most frequently identified correctly.

Nearly one-third (31of 96) of the private practice optometrists either wrote down non-retinal answers, implying that they did not recognize the figure as the retina, or left their sheet blank. Those who left the sheet blank may have done so for several reasons, including they did not recognize the im-

age as the retina, they recognized the retina but could not identify any of the layers, and/or although they consented to participate in the project, once they saw the task they did not "buy into" the project and refused to attempt to answer. These reasons are speculative because data were not gathered as to why the sheets were left blank.

The results of this study suggest that specific knowledge of the cross-sectional microanatomy of the retina is not currently necessary for successful practice of optometry in this cohort. While OCT has revolutionized the clinical practice of ophthalmology in terms of early detection of retinal diseases, monitoring not only disease progression but also the effects of treatments, it may not currently be considered a standard of care in optometric practice. However, there are those who think that this may change.[16] This may be especially true as more optometrists choose to not only diagnose retinal and other eye disease and make appropriate referrals but also offer follow-up care to these patients. As the use of advanced imaging procedures, e.g., OCT, grows, and as imaging technologies advance such that better resolution of ocular structures becomes possible,[17] optometrists may need to become increasingly proficient in their knowledge of ocular microanatomy in order to analyze and correctly interpret these images. Therefore it may be beneficial for optometric educators to correlate basic and clinical science concepts not only throughout optometric school curricula but also in continuing education courses as the use of these technologies expands.

This study has several limitations. The task given to the subjects was to name the retinal layers on a histologic image. Because most optometrists are not routinely exposed to this type of image, it may have not been readily recognizable to some of the members of the two optometrist groups. Using a retinal image that practitioners may encounter more frequently, such as an OCT image, may have been more helpful. Also, an OCT image may have aided in giving some relevance of the task to daily practice. Gathering information from the subjects regarding the relevance of the task to their clinical situation may have added interesting data as well. Although the choice of using an image of the cross-sectional microanatomy of the retina seemed logical because of its relevance to advanced imaging techniques, opting for a different anatomical subject that would be more routinely used in practice, such as the cornea or the crystalline lens, may have been more appropriate.

Additionally, only a small cohort of students and optometrists at a single college of optometry was sampled, limiting generalizations to all optometrists and optometry students. Also, only one specific anatomical structure viewed in a single orientation was used in this study; therefore, it should be pointed out that no conclusion can be drawn about the overall knowledge of ocular anatomy of the subjects in this cohort. It is not known whether similar results would be found if other ocular structures were similarly tested. While nothing can be inferred about the clinical skills of the members of this cohort, the results of this study reiterate the idea of "use it or lose it," i.e., retention of details (such as the layers of the retina) needs reinforcement by continued exposure in practice.

Conclusion

The results of this study suggest that specific knowledge of the retinal layers is not uniform across the groups in this study cohort. As the use of advanced imaging technologies expands, optometrists may need to become increasingly proficient in their knowledge of ocular microanatomy. It may be beneficial for optometric educators to correlate basic and clinical science concepts not only throughout optometric school curricula but also in continuing education courses.

Acknowledgement

The authors thank Dr. Susan Kelly for statistical contributions to this study.

References

1. Lazarus MD, Chinchilli VM, Leong SL, Kauffman GL. Perceptions of anatomy: critical components in the clinical setting. Anat Sci Educ. 2012;5(4):187-99.
2. Arráez-Aybar L-A, Sánchez-Montesinos I, Mirapeix R-M, Mompeo-Corredera B, Sañudo-Tejero J-R. Relevance of human anatomy in daily clinical practice. Ann Anat 2010;192(6):341-8.
3. D'Eon MF. Knowledge loss of medical students on first year basic science courses at the University of Saskatchewan. BMC Med Educ. 2006;6:5-10.
4. Feigin DS, Smirniotopoulos JG, Neher TJ. Retention of radiographic anatomy of the chest by 4th year medical students. Acad Radiol. 2002;9(1):82-8.
5. Spielmann PM, Oliver CW. The carpal bones: a basic test of medical students' and junior doctors' knowledge of anatomy. Surgeon. 2005;3(4):257-9.
6. Valenza MC, Castro-Martín E, Valenza G, Guirao-Piñeiro M, De-la-Llave-Rincón AI, Fernández-de-las Peñas C. Comparison of third-year medical and physical therapy students' knowledge of anatomy using the carpal bone test. J Manipulative Physiol Ther. 2012;35(2):121-6.
7. Strkalj G, Schroder T, Pather N, Solyali V. A preliminary assessment of the fifth-year chiropractic students' knowledge of anatomy. J Altern Complement Med. 2011;17(1):63-6.
8. Roche A, Williams G, Wharton D, Brown D. Physical and radiographic identification of the bones of the wrist by junior doctors. J Hand Surg Eur Vol. 2011;36(2):107-10.
9. Zysk AM, Nguyen FT, Oldenburg AL, Marks DL, Boppart SA. Optical coherence tomography: a review of clinical development from bench to bedside. J Biomed Optics. 2007;12(5):051403.
10. Adhi M, Duker JS. Optical coherence tomography – current and future applications. Curr Opin Ophthalmol. 2013;24:213-21.
11. Witkin AJ, Ip M, Duker JS. Optical coherence tomography. In: Duane's Ophthalmology (2012 Edition). Chapter 107. Tasman W, Jaeger EA (Eds). Lippincott Williams & Wilkins, Philadelphia, PA, USA (2011).
12. Health Quality Ontario. Optical coherence tomography for age-related macular degeneration and diabetic macular edema: an evidence-based analysis. Ont Health Technol

Assess Ser. 2009;9(13):1-22.
13. Goldberg RA, Waheed NK, Duker JS. Optical coherence tomography in the preoperative and postoperative management of macular hole and epiretinal membrane. Br J Ophthalmol. 2014;98:ii20-ii23.
14. Marmor MF, Kellner U, Lai TY, Lyons JS, Mieler WF. Revised recommendations on screening for chloroquine and hydroxychloroquine retinopathy. Ophthalmology. 2011;118(2):415-22.
15. Duker JS, Kaiser PK, Binder S, de Smet MD, Gaudric A, Reichel E, Sadda SR, Sebag J, Spaide RF, Stalmans P. The International Vitreomacular Traction Study Group classification of vitreomacular adhesion, traction, and macular hole. Ophthalmology. 2013;120(12):2611-9.
16. Murphy R. What SD-OCT can do for you: an optometric perspective. Optometric Management. 2012;47:22-6.
17. Wojtkowski M, Kaluzny B, Zawadzki RJ. New directions in ophthalmic optical coherence tomography. Optom Vis Sci. 2012;89(5):524-42.