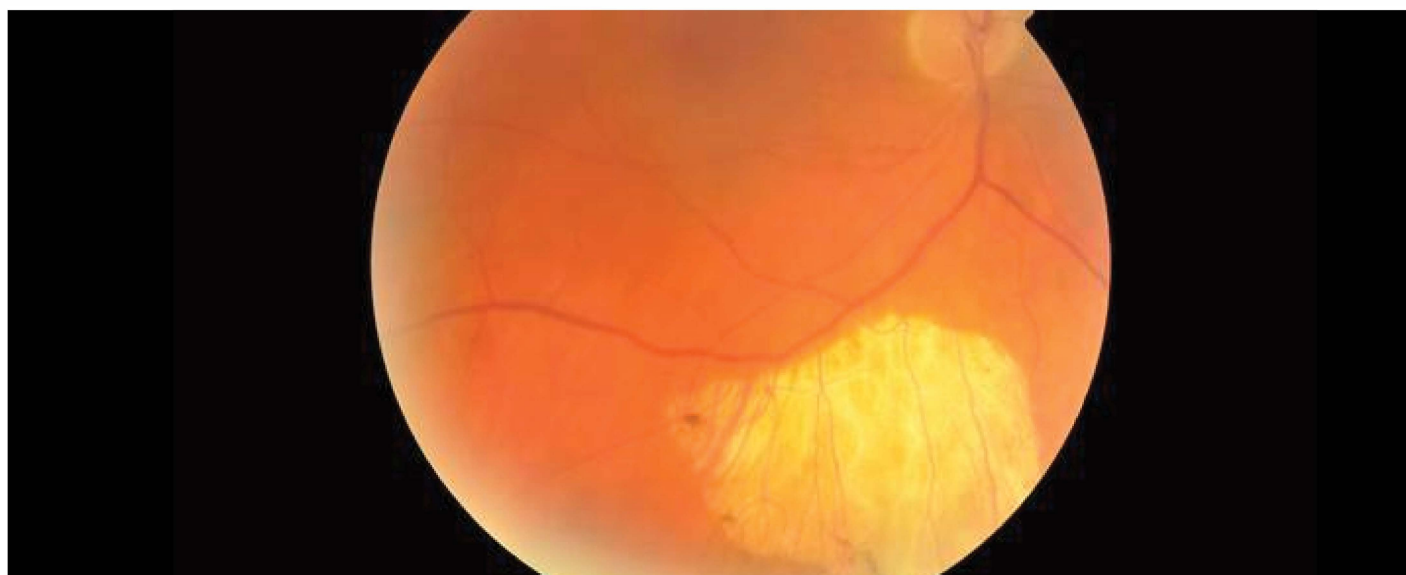


OPTOMETRIC EDUCATION

The Journal of the Association of Schools and Colleges of Optometry

Volume 43, Number 3
Summer 2018



Ocular Chrysiasis: a Teaching
Case Report

Teaching Ocular Imaging, Disease
Diagnosis and Management Within
a Work-Integrated Setting:
a Novel Model Within an Optometric
Education Program

Acquired Toxoplasmosis Manifesting as
Granulomatous Panuveitis:
a Teaching Case Report

Faculty Perceptions of the Impact of
Electronic Medical and Health Records in
Optometric Education in the United States
and Puerto Rico

ALSO INSIDE

Editorial: @ Our Wit's End with Unprofessional Student
E-mails

Special Announcement: ASCO thanks SIG Sponsors
Industry News

Table of contents

FACULTY PERCEPTIONS OF THE IMPACT OF ELECTRONIC MEDICAL AND HEALTH RECORDS IN OPTOMETRIC EDUCATION IN THE UNITED STATES AND PUERTO RICO	1
INDUSTRY NEWS	11
ACQUIRED TOXOPLASMOSIS MANIFESTING AS GRANULOMATOUS PANUVEITIS: A TEACHING CASE REPORT	17
TEACHING OCULAR IMAGING, DISEASE DIAGNOSIS AND MANAGEMENT WITHIN A WORK-INTEGRATED SETTING: A NOVEL MODEL WITHIN AN OPTOMETRIC EDUCATION PROGRAM	24
OCULAR CHRYSIASIS: A TEACHING CASE REPORT	36
THANK YOU!	41
@ OUR WIT'S END WITH UNPROFESSIONAL STUDENT E-MAILS	43

FACULTY PERCEPTIONS OF THE IMPACT OF ELECTRONIC MEDICAL AND HEALTH RECORDS IN OPTOMETRIC EDUCATION IN THE UNITED STATES AND PUERTO RICO

Abstract

Digital records, i.e., electronic health records (EHRs) and electronic medical Records (EMRs) are the current standard for documenting healthcare information. The purposes of this exploratory study were to gather information about the use of digital records in academic optometric settings in the United States and Puerto Rico and to assess faculty perceptions of the potential impact and implications of digital records in the teaching and learning process. The results indicated that most students have authority to enter data into the majority of the digital record. Potential influences of digital records in teaching and learning were identified in the areas of time for documentation, development of clinical reasoning, and student behaviors.

Key Words: *electronic medical records, electronic health records, digital records, optometric education*

Introduction

In 2001, the Institute of Medicine, which was established by the National Academy of Sciences as an independent advisory organization, advocated for the extensive use of information technology that would “lead to the elimination of most handwritten clinical data by the end of the decade.”¹ This information technology (digital records) became known as electronic health records (EHRs) and electronic medical Records (EMRs). EMRs are digital medical records that contain the standard medical and clinical data collected in one provider’s office.² EMRs were designed to reduce medical errors and improve quality of care.¹ Although the content can vary, most EMRs include clinical documentation (notes), patient data (demographics, lab results, problem/diagnosis list, medication list, psychosocial history, other test results), computerized order entry for medications and tests, clinical messaging, and decision support systems (alerts, warnings, reminders).³ EHRs are a digital collection of individual office visits (EMRs) and other health information. EHRs go beyond the information collected by one office or provider.² EHRs can be shared and provide information about an individual or populations.² As such they have the potential to enhance clinical care and impact research, public health policies and education.⁴

Digital records are a tool for documenting healthcare information and data used in caring for a patient. An important question to ask is whether this tool goes beyond documentation and has an impact on other areas such as student learning. Clinical reasoning, the cognitive process that clinicians use to care for patients, is based on data, information and evidence.⁵ Clinical reasoning can be defined as “thinking through the various aspects of patient care to arrive at a reasonable decision regarding the prevention, diagnosis or treatment of a clinical problem in a specific patient.”⁵ The digital record is a new method of documenting the data and information that can be used to drive the clinical reasoning process of clinicians.

Statistical data have shown a widespread increase in the use of digital records among healthcare providers and hospitals over the past few years.^{6,7} The Office of the National Coordinator for Health Information Technology reported in 2015 that 3 out of 4 (76%) non-federal acute care hospitals had adopted at least a basic digital record, and more than 8 out of 10 (83%) physicians had adopted a digital records system.^{6,7}

Digital records are also becoming commonplace in academic healthcare settings.⁸⁻¹⁰ In recent years, all optometric education institutions in the United States have implemented a digital record system in at least their main academic clinics.¹¹ In medical education, several advantages and disadvantages of increased digital records use have been identified. Advantages include ease of reviewing notes, availability of information, medical support tools, ease of organizing notes, and potential use of patient registries.⁸ Disadvantages include increased time spent charting, impact on clinical reasoning, impact on the development of student/patient rapport, and information overload.⁸

There is a paucity of information available about the use of digital records in optometric education. A search of PubMed, Medline, and VisionCite using the MeSH terms “electronic medical record” or “electronic health record” and “optometry teaching environments” or “optometric health care education” yielded no relevant articles. The purposes of this exploratory study were to gather information about the use of digital records in academic optometric settings in the United

States and Puerto Rico and to assess faculty perceptions of the potential impact and implications of digital records in the teaching and learning process.

Methods

All faculty members who were listed in the Association of Schools and Colleges of Optometry database as having clinical responsibilities were eligible for inclusion in the study. In May 2016, a link to a survey was e-mailed to 790 optometric faculty members who met the inclusion criteria. The survey consisted of 35 questions and sought information about the demographics of faculty users of digital records, and about the implementation, use and impact of digital records in clinical education. Seven of the questions were multiple-choice, four of the questions required a yes/no response, and 21 of the questions required a response along a four-point Likert-type scale (1 = strongly disagree; 2 = disagree; 3 = agree; 4 = strongly agree). A comment section was included.

Instrumentation

The survey was initially developed from a review of the literature and the investigators' clinical experience. A draft of the survey was fine-tuned by a focus group consisting of five clinical educators from the New England College of Optometry. The focus group refined questions and provided feedback on the readability and soundness of each question. To aid in simplicity, the terms EMR and EHR were used interchangeably in the survey. The intention was for faculty to reflect on the digital records used in their clinical setting. The survey was administered via the web-based system SurveyMonkey®. The survey was re-sent to all potential participants two weeks after the initial deployment. The formatting of the survey by SurveyMonkey® ensured that each participant could only respond once. Information obtained by the survey was confidential and anonymous. The survey is shown in **Appendix A**.

Data analysis

All data analysis was conducted using IBM SPSS version 25 (Chicago, IL) with alpha set at $p < 0.05$. Measures of central tendency were conducted for all continuous variables, and percent and proportions were calculated for all categorical variables. Within-subjects analysis of variance with the Bonferroni technique to control for inflated Type I error was employed to determine differences among survey items. A series of Spearman's rho correlations was conducted to determine the relationships between items from the survey and the following demographic variables: (a) age, (b) years practicing optometry, (c) years using EMRs, (d) number of clinical students, and (e) months using the current EMR system. Results of the a priori power analysis using G*Power (V3.1) software indicated a sample of $N = 67$ to achieve a moderate effect size of 0.30 with a 0.80 power and alpha set at $p < 0.05$ (two-tailed). The comments were analyzed using a grounded theory approach. The authors identified relevant comments with emerging themes and reached a consensus on the themes.

The study was reviewed by the Institutional Review Board at the New England College of Optometry and given an exempt status.

Results

The final overall response rate for the survey was 34% (265) of the clinical faculty members from optometry schools in the United States and Puerto Rico. The assumptions for linearity and normality were met for all variables.

TABLE 1
Student Use of Digital Records

Access to the EHR does the student have the authority to use	% Responses
yes	85
no	14
not sure	12
edit medications	96
view medications	98
view lab results	98
view notes	98
view radiology	98
view vitals	98
view history	98
view insurance	98
view billing	98
view other	98

Table 1.

[Click to enlarge](#)

TABLE 2

Using Digital Records in a Teaching Environment

	% Responses	Standard Deviation
1	80	0.40
2	62	0.49
3	52	0.50
4	46	0.40
5	16	0.37
6	31	0.46

Table 2.

[Click to enlarge](#)

TABLE 3

Advantages of Using Digital Records in a Teaching Environment

	% Responses	Standard Deviation
1	74	0.43
2	60	0.49
3	82	0.38
4	22	0.42

Table 3.

[Click to enlarge](#)

The median age of the respondents was between 36-45 years (mean 44 years). Respondents had 4-7 years of digital record experience. Thirty-two percent of the respondents had been practicing for more than 25 years. Eighty-seven percent of the respondents practiced in an optometric institution's eye clinic, 11% in a community health center, and 2% in a private practice setting. The Compulink system was the most used overall (48%). Eighty-six percent of the respondents reported using digital records specifically designed for eye care, and 96% reported using paper charts in the past. The majority of participants (66%) indicated that they felt students were well-trained in the use of digital records before arriving in clinic, and 84% indicated that students were exposed to using a digital record system in the preclinical environment. Most faculty (78%) reported being comfortable using their current digital record, and 69% reported not receiving formal training in the use of digital records as a teaching tool. The majority of respondents (85%) reported that students had authority to enter data into the EMR; 91% reported students could enter medication updates; 93% reported students could enter allergies; and 89% reported students could enter tests and interpretations. This data is shown in **Table 1**.

Statistically significant differences were found among the *challenges in using digital records in a teaching environment* $F(5, 259) = 79.52, p < 0.001, \eta^2 = 0.62$. Pairwise comparisons using the Bonferroni technique to control for inflated Type I error indicated that *time for documentation* is the greatest challenge, while *too much data* is the least challenging. Descriptive statistics related to challenges in using digital records are presented in **Table 2**. Statistically significant differences were also found among the *advantages in using digital records in a teaching environment* $F(3, 262) = 128.96, p < 0.001, \eta^2 = 0.60$. Pairwise comparisons using the Bonferroni technique indicated that *legibility of records* and *ability to access past records easily* are the greatest advantages, while *use of templates* is the least advantageous. Descriptive statistics related to advantages in using digital records are presented in **Table 3**.

The majority of faculty (74%) reported that time spent by students and faculty for documentation in the digital record takes away from time spent teaching. Respondents were split 50/50 on the perception of a digital record as a useful learning tool. The majority (78%) did not agree with the statement "The EHR has positively impacted my enthusiasm for teaching."

Fifty-eight percent of the respondents perceived that the inherent prompts (i.e., templates) and layout of a digital record system hinder students' development of clinical reasoning. Fifty-two percent of the respondents reported that they give students their undivided attention including direct eye contact during case presentation. Fifty-nine percent of the respondents did not agree with the statement "As a clinical instructor, I tend to rely more on information from the EHR than a student's oral case presentation."

Student behaviors as reported by faculty are impacted by digital records in *frequency of copying and pasting data* (67%

TABLE 4
Technology/Qualitative Research

[illegible]

Table 4.

Click to enlarge

[illegible]

Table 5.

[Click to enlarge](#)

[illegible]

Table 6.

[Click to enlarge](#)

agreed), relying more on information contained in the EHR rather than directly questioning the patient (57% agreed), writing before entering data into the computer (62% agreed), and ability to maintain eye contact with the patient during case history (85% agreed). **Table 4** lists responses to survey questions. **Table 5** lists descriptive statistics.

There were statistically significant correlations between faculty age and their (a) experience using a digital record system, and (b) the number of students they supervise in the clinic at a given time. The relationships between the demographic variables with the items from the survey are shown in **Table 6**. According to the data, older respondents and those practicing longer are statistically more likely to agree with items Q15 (*time spent by faculty for documentation within the EMR system takes away from teaching*), Q19 (*during case presentation, my student has my undivided attention including direct eye contact*), Q26 (*the use of EMRs has specifically impacted the students' ability to maintain eye contact with patients during the case history*), and Q29 (*I received formal faculty development training in the use of EMRs as a teaching tool*).

In addition, longer-time users of digital records are statistically more likely to agree with items Q19 and Q26. However, older respondents are less likely to agree with Q25 (*students tend to rely more on information contained in the EMR rather than directly questioning the patient*) and Q20 (*the instantaneous availability of information contained in the EMR has inhibited eliciting information from students*). No statistically significant relationships were found between *months using the current EMR system* and any of the survey items.

Finally, instructors with more clinical students are statistically more likely to agree with items Q21 (*students frequently*

copy and paste information from a previous record into the current EMR) and Q32 (EMRs propagate erroneous information). In contrast, instructors who were supervising fewer clinical students are statistically more likely to agree with items Q18 (as a clinical instructor, I tend to rely more of information from the EMR than a student's oral case presentation) and Q22 (to aid in efficiency, I frequently use information from EMRs to monitor students' activity in the exam room prior to speaking with students).

Survey Respondents' Comments Related to Digital Records and Teaching	
Table 7. Comments related to teaching and the use of digital records.	Table 8. Comments related to clinical reasoning and the use of digital records.
Comments related to teaching and the use of digital records.	Comments related to clinical reasoning and the use of digital records.

Table 7.
[Click to enlarge](#)

Table 8.
[Click to enlarge](#)

Table 7 depicts faculty comments related to teaching and the use of digital records. Qualitative analysis revealed a theme of decreased time for teaching with the use of digital records. Most of the comments expressed the challenges related to teaching and EMRs. However, two comments expressed the advantages of EMRs in teaching. **Table 8** depicts comments related to clinical reasoning and the use of digital records. Qualitative analysis revealed a theme of a negative impact on the development of critical thinking related to the use of digital records. All comments expressed a negative sentiment with regards to the development of clinical reasoning skills.

Discussion

The implementation of digital healthcare records in optometric settings has necessitated an evaluation of this method of documentation within the academic setting. In the survey, faculty perceptions of the potential impact and implications of digital records in the teaching and learning process focused on time for clinical teaching, student behaviors, and the development of clinical reasoning. Information gathered about the use of digital records addresses preparing students for success in patient care, which includes appropriate documentation in digital health records and clinical communication.

Student usage of the individual components of digital records

The majority of respondents indicated that students have the authority to enter data into the digital record, including updates of current medications, allergies, and tests and interpretation. Student use of EMRs is an important component in the educational process. The Association of Schools and College of Optometry states, "The school or college of optometry shall ensure that before graduation each student will have demonstrated: effective communication skills, both oral and written, as appropriate for maximizing successful patient care outcomes."¹² Additionally, the Accreditation Council on Optometric Education dictates that the optometric curriculum must prepare graduates for entry level practice, which includes the following standards:

- 2.9.1 The graduate must be able to identify, record and analyze pertinent history and problems presented by the patient.
- 2.9.8 The graduate must be able to effectively communicate orally and in writing with other professionals and patients.
- 8.2.4 The patient record must allow for efficient review of the patient's condition and any pertinent previous care provided at the program's clinical facility.¹³

Appropriate documentation is a learned skill and an essential component of patient care. Students must be given the opportunity to practice and receive feedback in all areas of documentation to ensure they achieve competency by graduation. In medical education, it is an accepted belief that student documentation enhances patient care and the student's education.¹⁴ Gliatto et al. state that "this hands-on experience has provided a way for students to reflect on patient encounters, learn proper documentation skills and attain a sense of being actively involved in and responsible for the care of patients."¹⁵ The survey revealed that in most sections of the digital record students have the authority to enter data. The majority (85%) of optometric sites and instructors give students the authority to document in the EMR. This gives

the students the opportunity to learn and practice documentation skills. In contrast, Wittels et al. found that only 63% of emergency medicine clerkships allowed medical students to document a patient encounter.¹⁶ These differences may reflect differences in billing policies, patient safety issues or environments (inpatient hospital care vs. outpatient care). According to the survey, optometry students participate less in some sections, such as data for billing, demographics, generating referrals, ordering additional tests, and ordering additional medications, than in other sections. Student documentation in all sections should be encouraged to provide a comprehensive educational experience.

Impact on teaching

Based on the survey responses, time spent on documentation by both students and faculty reduces the amount of time available for clinical teaching. The majority of comments related to teaching loudly echoed a concern for lost teaching time. Older respondents and those practicing longer were more likely to agree that faculty documentation within the digital record takes away from teaching. This may reflect differences in comfort levels related to technology and learning. Most clinical faculty are responsible for providing a high level of patient care, maintaining clinical productivity and educating students. In any given clinical session, there is a limited amount of time. In most clinical environments, a constant high level of patient care while maintaining productivity is necessary to ensure financial stability. Therefore, clinical teaching becomes vulnerable to any reduction in time. An important question to ask is why documentation in digital records is so slow. Slowness in documentation could be attributed to the inherent design of digital records, changes in student behaviors, or inadequate/ineffective training. The survey revealed that most faculty members feel that students are exposed to digital records in the preclinical environment and are well-trained before arriving in clinic. However, the study did not determine the students' level of skill after training, type of training or the specific amount of time dedicated to training, which may influence the speed of documentation. Student behaviors such as writing findings on paper before entering data into the computer could contribute to a slower and less efficient student. The reasons some students write before entering data was not explored in the study. Theoretically, students may write before entering data because they are not confident in their findings or efficient in the use of the computer or data entry. Seventeen percent of the respondents perceived that student documentation allows more time to teach. This group tended to be younger with less years in practice.

Faculty members were split on the potential use of digital records as a tool for assisting teaching and learning. Younger respondents with fewer years in practice were more likely to agree that digital records are a useful tool to assist in teaching and promote learning. The most significant advantages of digital records identified were *ability to access past records*, *ability to access patient information*, and *legibility of records*. In a national study by Hammoud, these same advantages were identified in medical education.⁸ Theoretically, these characteristics have the potential to aid in teaching and learning. However, the advantages afforded by digital records may be offset by the perceived loss of teaching time.

Student behaviors

Identifying changes in student behaviors related to digital records as perceived by faculty can be helpful in guiding teaching strategies. The *ability to maintain eye contact with a patient during case history* and the *use of the copy and paste features* were perceived changes in student behavior related to the use of digital records. Faculty who were older, practiced longer and had been using digital records longer were more likely to agree with the students' loss of eye contact. Most faculty agreed that the design of the exam room had not been adjusted to maximize communication while using a digital record. Faculty who felt that the layout of the exam room had been modified tended to be younger with fewer years in practice. The ability to communicate and develop a relationship with the patient is an essential tool in rendering a high level of patient care.¹⁷ Poor eye contact while using digital records reflects poor communication skills and may impact the development of rapport with the patient.¹⁸ Students in the preclinical environment need to develop and practice communication skills that allow for the gathering of appropriate data while fully maintaining eye contact and efficiently entering data into the digital record. Suggestions for improving eye contact may include altering exam room layout to maximize communication, instructing the student to look at the patient and move away from the keyboard during the case history, and using defined breaks from conversations with patients to enter data.

The tendency for students to copy and paste information was perceived by a majority of survey respondents. This has serious consequences related to ethics, medical errors and propagation of incorrect information. In 2001, a study within the Veterans Administration System revealed that "20% of notes showed evidence of copying with an average of 1.01 errors per copied note."¹⁹ In a 2009 physician survey, 90% of the physicians who wrote notes used the copy and paste function.²⁰ In optometric education, anecdotal information indicates that many students copy and paste information as a means of decreasing documentation time. In clinic, students are learning and it is the clinical instructor's job to instruct them on the potential negative consequences related to copying and pasting information. All institutions and clinical

environments should have a clear policy on copying and pasting during documentation. Unethical practices, poor patient care and increased liability should not be a mere click away.

Clinical reasoning

One of the goals of clinical teaching is the development of clinical reasoning. Faculty perceived digital records to impact the development of clinical reasoning in three areas: student reliance on templates, use of copy and paste features, and the presentation of clinical data/thought process. Most digital records contain multiple templates as well as the capability of adding free text. The majority of faculty in this study (58%) perceived digital records to hinder the development of clinical reasoning. This perception was also reiterated in the faculty comments on clinical reasoning. In medical education, a major challenge of digital records was the potential barrier to the development of clinical reasoning skills.⁸

Clinical reasoning involves gathering, synthesizing, analyzing and critically reviewing information/data. Historically, questioning during the case history allows the clinician to gather information, generate an initial hypothesis and refine the hypothesis based on a patient's response. The use of templates can impact reasoning because questions are asked as dictated by the template and not by the student's thought process. Therefore, and in order to ensure that a student is applying clinical reasoning, faculty should challenge the student's thought process to demonstrate that adequate skill, advancement and progression are achieved.

Another potential barrier to the development of clinical reasoning skills is the copying and pasting of information, specifically the assessment/diagnosis and management. The majority of faculty agreed in the survey that students utilize this feature. Respondents with more students to supervise were more likely to agree that students too frequently copied and pasted information from a previous record into the current digital record. Perhaps faculty with more supervisees are more exposed to repetitious notes and thus are more able to detect frequent copying and pasting. The final assessment/diagnosis and management lists represent coming to a conclusion by gathering, analyzing and evaluating appropriate information, examining assumptions and identifying any biases. If students are allowed to copy and paste this part of the note, it may negatively influence the development of clinical reasoning skills.

Student case presentation represents the oral presentation of data and a student's clinical reasoning.²¹ A majority of faculty (64%), especially those who were younger with fewer years in practice, indicated using digital records to get information to monitor a student's activity, and (66%) indicated using digital records to aid in instructor decision-making before student case presentation. Additionally, 59% of the respondents reported relying on information from the student's oral case presentation rather than the digital record, and 52% indicated that students have the clinical faculty member's undivided attention during case presentation. As an educational tool, case presentation allows the clinical instructor the opportunity to gain insight into a student's reasoning while allowing the student the opportunity to perfect the skill. In medicine, case presentation can take 2-7 minutes.²¹ Clinical faculty often balance the more efficient acquisition of information from a digital record with the educational experience of case presentation. Student need, productivity requirements and patient care may dictate during any given patient encounter where and how information is acquired. In the survey, age, years in practice and years using digital records were associated with providing undivided attention to students, which suggests that experienced clinicians might more easily recognize the value and educational benefit of case presentation.

Interestingly, respondents with fewer students were more likely to rely on information from the digital record than on the student's oral case presentation. One possible explanation is that faculty with fewer students may have a better understanding of their students' abilities and can with greater confidence simply rely on the digital record rather than investing in the time of an oral case presentation. This explanation is partially supported by the fact that respondents with fewer students are also more likely to use information from the digital record to monitor students' activity in the exam room prior to speaking with students.

The goals of clinical faculty are to educate and take care of patients. The value of case presentation must be recognized and balanced with the efficient acquisition of information.

Limitations of the study

The study was limited by the sample size, lack of data related to respondents' specific institution, blurring of the terms EMR and EHR in the survey, and lack of specificity in some of the questions. The overall response rate to the survey was 34%, representing 265 respondents. The individual response rate for each question varied between 265-252 respondents because a response to each question was not mandatory to complete the survey. There is no agreement in the literature on acceptable response rates.²² However, response bias or non-response error is always more of a risk with a lower response rate.²² Data were not collected related to the name of each respondent's institution. This may have introduced a bias if, for

example, a large number of faculty from one institution responded. In the survey, the participants were instructed to use the terms EHR and EMR interchangeably. Although the digital record that most faculty are completing after each encounter is an EMR, the interchangeable use of the terms may have blurred the specific components of the digital record that were impacted. In hindsight, more specificity in some of the questions such as the length and type of training received by students and faculty, level of expertise in using digital records, type of data or text that students copy and paste, and the specific level of impact on enthusiasm for teaching would have been helpful.

Conclusion

Digital records constitute the present and future landscape of health care and have become a vital component of clinical care. The results of this study indicate that students have authority to use several parts of the digital record. Further, the results indicate that time related to documentation within digital records impacts the educational process. Additionally, the study indicates that faculty perceive digital records as having an impact on student behaviors and the development of clinical reasoning skills. Age, years in practice and years using digital records are indicators for the perception of faculty documentation affecting teaching time, providing undivided attention to students during case presentation, and the perception of an impact in student eye contact with patients. To maximize use of digital records in patient care and clinical education, tools such as educational guidelines and template assistance need to be developed to guide faculty and students during the teaching and learning process. The study raises several issues for future investigation, including what specifically about digital records takes more time, whether the training and skill level of students impact the time for documentation, whether digital records impact enthusiasm for clinical optometric teaching, what specific type of training is received by faculty, what is the impact of the training, how template design impacts the development of clinical reasoning skills. In an effort to develop educational strategies, future areas of research may include students' perception of digital records, Medicare compliance, ethics and medical errors, implementation strategies and lessons learned from past experiences.

Acknowledgments

We extend gratitude and appreciation to the members of our focus group who provided insight and comments for the survey: Drs. Crystal Lewandowski, Judith Darrow, Thomas Andrea, Meng Meng Xu and James Aylward.

Special thanks to Elena Bilodeau for technical assistance and Taylor Cleland and Sophia Koevary for editing.

Data from this study were presented at the 2016 American Academy of Optometry Annual Meeting in Anaheim, Calif.

References

1. Institute of Medicine (US) Committee on Quality of Health Care in America. Crossing the quality chasm: using information technology. Washington (DC): National Academies Press, 2001. Available from: <https://www.ncbi.nlm.nih.gov/books/NBK22274/>.
2. Health IT and health information exchange basics [Internet]. Washington, DC: Health IT.Gov; c2014 [cited 2016 Feb 23]. Available from: <https://www.healthit.gov/providers-professionals/electronic-medical-records-emr>.
3. Keenan CR, Nguyen HH, Srinivasan M. Electronic medical records and their impact on resident and medical student education. *Acad Psychiatry*. 2006 Nov-Dec;30(6):522-527.
4. Institute of Medicine Committee on Data Standards for Patient Safety. Board on Health Care Services. Key capabilities of an electronic health record system: letter report. Washington, DC: National Academies Press, 2003. Available from: <https://www.ncbi.nlm.nih.gov/books/NBK216105/>.
5. Hawkins D, Elder L, Paul R. *The Thinker's Guide to Clinical Reasoning*. Dillon Beach CA: Foundation for Critical Thinking Press; 2010, P. 3-5.
6. Charles D, Gabriel M, Searcy T. Adoption of electronic health record systems among U.S. nonfederal acute care hospitals: 2008-2014 [Internet]. Washington (DC): National Coordinator for Health Information Technology, c2015 [cited 2016 Feb 23]. Available from: <https://www.healthit.gov/sites/default/files/data-brief/2014HospitalAdoptionDataBrief.pdf>.
7. Heisey-Grove D, Patel V. Any, certified, and basic: quantifying physician EHR adoption through 2014 [Internet]. Washington (DC): National Coordinator for Health Information Technology; c2015 [cited 2016 Feb 23]. Available from:

https://www.healthit.gov/sites/default/files/briefs/oncdatabrief28_certified_vs_basic.pdf.

8. Hammoud MM, Margo K, Christner JG, Fischer SH, Pangaro LN. Opportunities and challenges in integrating electronic health records into undergraduate medical education: a national survey of clerkship directors. *Teach Learn Med*. 2012;24(3):219-24.
9. Mintz M, Narvarte HJ, O'Brien KE, Papp KK, Thomas M, Durning SJ. Use of electronic medical records by physicians and students in academic internal medicine settings. *Academic Medicine*. 2009 Dec;84(12):1698-704.
10. Hammoud MM, Dalymple JL, Christner JG, et al. Medical student documentation in electronic health records: a collaborative statement from the Alliance for Clinical Education. *Teach Learn Med*. 2012;24(3):257-66.
11. Chu, Gary. Conversation with David Durkee, OD. July 10, 2016.
12. Smythe J, Daum K. Attributes of students graduating from schools and colleges of optometry: a 2011 report from the Association of Schools and Colleges of Optometry. *Optometric Education*. 2011;37(1):5-10.
13. Accreditation Council on Optometric Education. Professional optometric degree standards adopted by the Accreditation Council on Optometric Education (ACOE) at the ACOE Winter Meeting, Feb 19-21, 2016, Addendum 1 [cited 2017 Oct 23]. Available from: https://www.aoa.org/Documents/students/OD_Manual_08_2014_with_2017_standards_attached.pdf.
14. Friedman E, Sainte M, Fallar R. Taking note of the perceived value and impact of medical student chart documentation on education and patient care. *Acad Med*. 2010 Sep;85(9):1440-4.
15. Gliatto P, Masters P, Karani R. Medical student documentation in the medical record: is it a liability? *Mt Sinai J Med*. 2009 Aug;76(4):357-64.
16. Wittels K, Wallenstein J, Patwari R, Patel S. Medical student documentation in the electronic medical record: patterns of use and barriers. *West J Emerg Med*. 2017 Jan;18(1):133-136.
17. Stewart MA. Effective physician-patient communication and health outcomes: a review. *CMAJ*. 1995 May 1;152(9):1423-33.
18. Richter Ettinger E. *Professional Communications in Eye Care*. Butterworth-Heinman 1993; pages 43-45.
19. Weir CR, Hurdle JF, Felgar MA, et al. Direct text entry in electronic progress notes. An evaluation of input errors. *Methods Inf Med*. 2003;42(1):61-7.
20. O'Donnell HC, Kaushal R, Barrón Y, et al. Physicians' attitudes towards copy and pasting in electronic note writing. *J Gen Intern Med*. 2009 Jan;24(1):63-68.
21. Wiese J, Saint S, Tierney LM. Using clinical reasoning to improve skills in oral case presentation. *Semin Med Pract*. 2002 Sept;5(3):29-36.
22. Draugalis JR, Coons SJ, Plaza CM. Best practices for survey research reports: a synopsis for authors and reviewers. *Am J Pharm Educ*. 2008 Feb 15;72(1):11.

Appendix A
Survey Questions

1. How many hours of clinical experience do you have in your current position?	21. Student population within the 1000 system allows for clinical experience
2. How many hours of clinical experience do you have in your current position?	22. Is a clinical experience (or other) course used in the curriculum?
3. How many hours of clinical experience do you have in your current position?	23. How many hours of clinical experience (or other) course is used in the curriculum?
4. How many hours of clinical experience do you have in your current position?	24. How many hours of clinical experience (or other) course is used in the curriculum?
5. How many hours of clinical experience do you have in your current position?	25. How many hours of clinical experience (or other) course is used in the curriculum?
6. How many hours of clinical experience do you have in your current position?	26. How many hours of clinical experience (or other) course is used in the curriculum?
7. How many hours of clinical experience do you have in your current position?	27. How many hours of clinical experience (or other) course is used in the curriculum?
8. How many hours of clinical experience do you have in your current position?	28. How many hours of clinical experience (or other) course is used in the curriculum?
9. How many hours of clinical experience do you have in your current position?	29. How many hours of clinical experience (or other) course is used in the curriculum?
10. How many hours of clinical experience do you have in your current position?	30. How many hours of clinical experience (or other) course is used in the curriculum?
11. How many hours of clinical experience do you have in your current position?	31. How many hours of clinical experience (or other) course is used in the curriculum?
12. How many hours of clinical experience do you have in your current position?	32. How many hours of clinical experience (or other) course is used in the curriculum?
13. How many hours of clinical experience do you have in your current position?	33. How many hours of clinical experience (or other) course is used in the curriculum?
14. How many hours of clinical experience do you have in your current position?	34. How many hours of clinical experience (or other) course is used in the curriculum?
15. How many hours of clinical experience do you have in your current position?	35. How many hours of clinical experience (or other) course is used in the curriculum?
16. How many hours of clinical experience do you have in your current position?	36. How many hours of clinical experience (or other) course is used in the curriculum?
17. How many hours of clinical experience do you have in your current position?	37. How many hours of clinical experience (or other) course is used in the curriculum?
18. How many hours of clinical experience do you have in your current position?	38. How many hours of clinical experience (or other) course is used in the curriculum?
19. How many hours of clinical experience do you have in your current position?	39. How many hours of clinical experience (or other) course is used in the curriculum?
20. How many hours of clinical experience do you have in your current position?	40. How many hours of clinical experience (or other) course is used in the curriculum?

Appendix A.
[Click to enlarge](#)



Dr. Denial [deniala@neco.edu], Editor of Optometric Education, is a Professor of Optometry at the New England College of Optometry. She developed, administers and teaches in the Clinical Reasoning Course Sequence. She is also a clinical instructor.

Dr. Bastian is an Assistant Professor at the New England College of Optometry. He is an Instructor of Record for the first-year Principles and Practices of Optometry II and III courses. Dr. Bastian is an Attending Optometrist at the Lynn Community Health Center in Lynn, Mass.

Dr. Chu is the Senior Director of Public Health and Community Collaborations at the New England College of Optometry. He is responsible for the design, development, review and management of the college's community health center and outreach programs.

Dr. Moy is an Associate Professor of Clinical Optometry and Chief Clinical Officer of the Clinical Network at the New England College of Optometry. She is also the Director of Optometry at the Boston Children's Hospital, Martha Eliot Health Center.

INDUSTRY NEWS



DTC Campaign Features Multifocal Contact Lenses



Alcon has launched a new direct-to-consumer campaign to increase consumer awareness of multifocal contact lens options and encourage them to visit an eyecare professional. The “See Near and Far” campaign includes a television spot running throughout 2018 on ABC, NBC, CBS, ESPN and other networks along with national print and digital media.

“See Near and Far” aims to reach presbyopes who may already be wearing reading glasses or who are just starting to experience difficulties with near vision. It conveys the benefits patients can expect to experience with DAILIES TOTAL1 Multifocal contact lenses. [Click here for more information](#) about Alcon’s direct-to-consumer efforts to educate patients.

New Device Stimulates Natural Tear Production



The TrueTear handheld neurostimulation device from Allergan is the first and only FDA-cleared device designed to temporarily increase tear production with neurostimulation in adult patients, offering a novel and innovative way to address inadequate tear production. Using disposable tips, patients insert the device into the nasal cavity to induce the production of natural tears. In two clinical trials, TrueTear was shown to be safe and effective for temporarily increasing tear production in adult patients. Visit www.truetear.com for more information.

Photochromic Lens Options Expand



Sensity Dark and Sensity Shine, the newly launched photochromic lenses from Hoya Vision Care, include all of the features of original Sensity lenses with added processing and performance.

Sensity Dark, priced the same as original Sensity, activates behind the windshield of a car and fades back to full clarity. Sensity Shine also activates behind the windshield of a car and offers wearers a fashion-forward look with mirror coating. Color options for Sensity Dark and Sensity Shine — a neutral grey tone, a more flamboyant brown and a lively and slightly intense green — were chosen to provide ideal contrast and glare reduction without sacrificing precise vision. Visit <http://www.hoya.com>.

Project Foresight Winners



Walmart and Sam's Club Health & Wellness presented awards to the winners of its annual optometry student scholarship competition, Project Foresight. Project Foresight, open to students at all ASCO member schools, is a national competition that highlights the Walmart and Sam's Club Health and Wellness vision of providing quality, affordable, accessible healthcare for all. Two-person student teams were asked to research and present on how Walmart partners with optometrists and how they envision that partnership moving forward.

Janelle Sventek and Verle Judd (University of the Incarnate Word Rosenberg School of Optometry) earned first place and received a \$15,000 team scholarship and traveling trophy. Carrie DeWolfe and Katie Cargill (Michigan College of Optometry at Ferris State University) were the runners-up and received a \$5,000 team scholarship. Stay tuned for the 2018-2019 Project Foresight competition.

Higher Cylinder Power Debuts



The -2.75D cylinder power is now available for the entire portfolio of Bausch + Lomb ULTRA for Astigmatism contact lenses, from +6.00D to -9.00D. According to the company, the addition makes Bausch + Lomb ULTRA for Astigmatism contact lens the only monthly planned replacement lens with this cylinder power available in the fit set.

Bausch + Lomb ULTRA for Astigmatism lenses combine MoistureSeal technology for comfort and OpticAlign design for stability. For more information on these and other contact lenses, [visit the B+L website](#).

New White Paper on Ultra-widefield Imaging



Dr. Daniel Epshtein, OD, has added a new white paper to the New Grad Optometry website. [A Complete Guide to the Clarus 500 Ultra-widefield Retinal Camera](#) provides insights into the ever-changing eyecare landscape and why more eyecare professionals are implementing ultra-widefield technology into their patient care protocols.

Dr. Epshtein has a hospital-based practice where he combines his research experience with the latest clinical strategies to detect sight-threatening disorders early and to provide the best possible treatments. He considers the CLARUS 500, a

high-definition ultra-widefield fundus imaging system from Zeiss, to be a crucial component of an integrated approach to the diagnosis and management of ocular pathology.

Get Up to Date on the Value of VEP and ERG



Diopsys, developer of the Diopsys NOVA and other visual electrophysiology technologies, offers a variety of [resources for eyecare professionals](#) at its website, including educational videos and case studies. Recent blog posts at the site include "How Patients Benefit from ERG Vision Testing" and "What do I see on this VEP?"

Leading eyecare centers across the country utilize Diopsys devices, which are backed by more than 15 years of published studies. Visitors to the site can conveniently narrow their search for information based on disease state, product and/or resource type.

FDA Clears Multi-modal Imaging Device with Swept Source OCT



Topcon Medical Systems announced that its DRI OCT Triton Series has received 510(k) clearance from the FDA. The DRI OCT Triton features easy image capture and a 1-micron, 1050-nm light source with a scanning speed of 100,000 A-scans/second. The multi-modal instrument incorporates a built-in retinal camera, eye tracking during capture of selected scans, and combines the company's years of expertise in OCT imaging, color, red-free, fluorescein angiography and fundus autofluorescence imaging with the diagnostic power of swept source OCT.

For more information, visit www.topconmedical.com.

Schools Can Take Advantage of Digital Indirect



Keeler Americas now offers its Keeler Modified Digital Indirect ophthalmoscope to schools and colleges of optometry. The Modified Digital Indirect is the same unit used by the National Board of Examiners in Optometry for all students taking Part III of the board exam. The unit is designed to combine ease of use with a great view to allow swift examination by students and concise evaluation by professors.

For User Support and information about all of Keeler's products, visit <http://support.keeler-global.com/index.html>.

New Line of Slit Lamps Introduced



Marco has introduced a new line of slit lamps, the Ultra M Series, which it says features elegant and intelligent design, progressive engineering and functional flexibility. Attributes of the Ultra M Series include multiple color and blue-correction filters, patented integrated background illuminator, extended slit aperture and wider field of view, and intelligent operator and patient interfaces.

For more information on Ultra M Series design enhancements, visit www.MARCO.com.

Student Grant Program Completes Its Third Year



The 2018 winners of the National Vision/National Optometric Student Association (NOSA) grants are Jaelyn DeBerry, Southern College of Optometry class of 2019 (\$4,000); Priscilla Chang, Illinois College of Optometry class of 2019 (\$2,000); and Sterlin Blakley, University of Alabama at Birmingham School of Optometry class of 2019 (\$1,000).

Each year, the grant program recognizes three students who are NOSA members. For this year's grant program, which was inspired by Simon Sinek, consultant and author of *What is Your Why?*, students were asked to submit an essay or video revealing their "why," and explaining their personal mission as a future Doctor of Optometry. National Vision hopes the

grants encourage students to continue their work in primary care and to recognize its importance in communities nationwide.

Visit <https://www.nationalvision.com/> to learn more about National Vision.

Capture More Data for Scleral Lens Fitting



With the new Cornea Scleral Profile (CSP) Report, the Oculus Pentacam now measures sagittal height, a key parameter for scleral lens fitting. More than 200 Scheimpflug images covering a diameter of up to 18 mm are taken in the measuring process. All images for a Cornea Scleral Profile scan are taken from the same visual axis without the need for eye movement.

The usual Pentacam data are also recorded and populated into the displays already familiar to Pentacam users. The CSP scan is a tear-film independent measurement with automatic release. This ensures the values from the CSP Report are as reproducible as all other measured data. A link to external fitting software for scleral lenses is available.

Find complete [information about Pentacam online](#).

Take the Wider View with New OCT Combination Instrument



Optos launched Monaco, its new compact desk-top ultra-widefield retinal imaging device. Monaco provides greater imaging functionality and is the company's first imaging device to combine optical coherence tomography with ultra-widefield color imaging, 3-in-1 color depth imaging and autofluorescence.

[Click here](#) to learn more about Monaco.

OD Leadership Team Announced



Rev360, the eye care software and business solutions company that serves practices using RevolutionEHR, announced a growing leadership team of seven optometrists:

- Scott Jens, OD, CEO
- Mike Rothschild, OD, Director of Practice Management Initiatives

- Brett Paepke, OD, Director of ECP Services
- Kelly Kerksick, OD, Director of Professional Relations
- Ann Hoscheit, OD, Director of ECP Strategy
- Todd Zarwell, OD, Director of Practice-Facing Technologies
- Ali Khoshnevis, OD, Manager of Consumer-Facing Technologies

Members of the OD leadership team possess deep and unique optometric expertise coupled with years of practice management experience operating their own businesses, all on the RevolutionEHR software platform. They spearhead Rev360's innovation efforts, work to advance the RevolutionEHR software, and deliver business solutions to customers. [Learn more about the team.](#)

Applications Now Being Accepted for Student Mission Trip



The application process is now open for the 2019 Student OneSight clinic to a yet-to-be-determined global location next May. The OneSight organization is focused on bringing both sustainable and urgent vision care solutions to communities around the world. On the OneSight trip, optometry students work under the supervision of Luxottica Retail-affiliated doctors performing comprehensive eye exams. They help support a core team of Luxottica volunteers in the frame fitting, manufacturing and dispensing of new eyewear. For the selected students, Luxottica Retail covers the expenses associated with the clinic, including air fare, accommodations and meals.

Optometry students interested in participating in a 2019 OneSight vision clinic can [apply online](#). Applications will be accepted through Dec. 10, 2018.

ACQUIRED TOXOPLASMOSIS MANIFESTING AS GRANULOMATOUS PANUVEITIS: A TEACHING CASE REPORT

Abstract

Diagnosing and treating panuveitis can be difficult with a variety of differential diagnoses. In this case report, a 62-year-old Caucasian male presented with a unilateral granulomatous panuveitis. His previous exams had revealed no signs of past inflammation. Although acquired toxoplasmosis is atypical, laboratory testing revealed positive IgM and IgG results, which would indicate a positive toxoplasmosis diagnosis. The patient responded to topical treatment with the addition of oral azithromycin and intravitreal clindamycin, followed by oral prednisone. He recovered three months later with only a mid-peripheral chorioretinal scar. Uveitis characteristics and lab test results were key indicators leading to the diagnosis of toxoplasmosis in this case.

Key Words: uveitis, granulomatous uveitis, toxoplasmosis, posterior uveitis, panuveitis

Background

This case report follows the diagnosis and management of a patient with unilateral granulomatous panuveitis including differential diagnosis, diagnostic lab testing and treatment. The case is an unusual presentation of uveitis, and it is a useful educational exercise to consider the differential diagnoses and potential treatment options. The intended audience is third- and fourth-year optometry students and residents.

Case Description

A 62-year-old Caucasian male presented in clinic with a chief complaint of seeing a spot in his right eye that appeared to move with the eye. He wasn't sure how long it had been there. He stated that he had noticed it when bowhunting season started approximately two weeks previously. He had not noted any pain, photopsia or decreased vision. The patient's medical history was significant for diet-controlled diabetes, hypertension, basal cell carcinoma, hypercholesterolemia, and bradycardia. His medications included simvastatin, baby aspirin and vitamin D. His last dilated fundus exam had been two years prior with unremarkable findings.

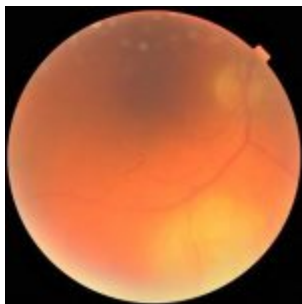


Figure 1. Yellow chorioretinal inflammatory lesion inferior to the optic nerve head in the right eye. [Click to enlarge](#)

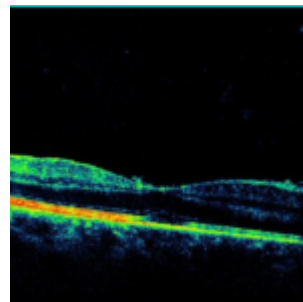


Figure 2. OCT showing diffuse retinal thickening in the area of the inflammatory lesion.

[Click to enlarge](#)

The patient's best-corrected visual acuity (BCVA) on the day of presentation was 20/25- OD, 20/20 OS. Pupils showed a sluggish reaction in the right eye, a normal reaction in the left eye, and anisocoria, with pupils measuring 4 mm in the right eye and 2.5 mm in the left eye. There was no afferent pupillary defect. Goldmann applanation tonometry measured 38 mmHg OD and 14 mmHg OS. The slit lamp exam was remarkable for 3+ mutton fat keratic precipitates on the corneal endothelium with mild corneal edema in the right eye and a moderate anterior chamber reaction with 2-3+ cells and mild to moderate flare. A very mild nuclear sclerotic and posterior subcapsular cataract were noted in each eye. All other anterior and posterior findings were normal OS. There was a poor view of the posterior pole OD, either due to the corneal edema or perhaps vitreal debris.

One drop each of brimonidine, timolol/dorzolamide, and cyclopentolate 2% were instilled in-office in the patient's right eye. It was suspected that posterior synechiae were forming OD due to the larger pupil size and the sluggish pupillary response. One hour after instillation of the drops, intraocular pressure (IOP) decreased to 24 mmHg, and the pupil dilated without signs of synechiae. The patient was started on prednisolone 1% q1h, cyclopentolate 2% bid, brimonidine bid and

timolol/dorzolamide bid OD.

Follow-up 1: two days after initial presentation

The patient returned to the clinic two days later. He had noticed no change with his eyes. His BCVA was 20/50 OD. IOP was 14 mmHg, again measured with Goldmann applanation tonometry. Anterior chamber showed 2+ cells. The view of the posterior pole was much improved, and a 3-4 disc-diameter, slightly elevated, yellow inflammatory chorioretinal lesion was noted inferior to the optic nerve. **(Figure 1)** The optic nerve had a C/D ratio of 0.3 and appeared healthy and well-perfused. OCT showed diffuse retinal thickening in the area of the lesion that extended toward the macula. **(Figure 2)** Vitreal cells appeared mild. The patient reported a history of owning, taking care of, and interacting with cats on a long-term and regular basis. Fluorescent Treponemal antibody absorption (FTA-ABS) and Toxoplasma antibody tests were ordered, and the patient was referred to an ocular inflammatory specialist for further work-up.

Follow-up 2: one week after initial presentation

The patient was seen five days later by the uveitis specialist. He reported having a history of a positive purified protein derivative test 15 years previously, and he had been treated with isonicotinyldiazine for nine months. He stated that he had not traveled recently. His BCVA was 20/30-, his anterior chamber reaction had decreased to 1-2+ cells, and his IOP was 11 mmHg. His ocular findings were otherwise unchanged. His vitreal cell status was graded as 1-2+ with debris. A B-scan ultrasound test was performed and demonstrated questionable mild retinal thickening inferiorly OD.

Initially, due to the appearance of the lesion and the patient's prior history, the uveitis specialist considered tuberculoma to be the most likely diagnosis. Other possible etiologies included Toxoplasma, lymphoma, syphilis, Bartonella, sarcoidosis, human immunodeficiency virus (HIV), Lyme disease and metastasis. Tests for HIV, rapid plasma reagin (RPR), angiotensin-converting enzyme (ACE), quantiferon-gold, complete blood count (CBC), Bartonella and lyme disease were ordered. Prednisolone was tapered to qid, and cyclopentolate, brimonidine and timolol/dorzolamide were continued bid. An anterior chamber tap was not performed at this time, and oral azithromycin and oral prednisone were discontinued pending lab results and further monitoring of the patient.

Follow-up 3: eight days after initial presentation

The patient was seen again the next day, and his BCVA was 20/50 OD. Exam findings were unchanged from the previous day. The patient had discontinued timolol/dorzolamide on his own, but IOP remained acceptable at 9 mmHg. The labs for IgM and IgG toxoplasmosis came back positive. HIV testing was negative, and CBC was normal. Other labs were still pending. The patient was started on oral azithromycin 500 mg daily, and the topical medications were continued unchanged except for the discontinuation of timolol/dorzolamide.

Follow-up 4: 10 days after initial presentation

The patient returned two days later. His BCVA was 20/40 OD, and the anterior chamber reaction had decreased to 1+ cells, but exam was essentially unchanged. No additional lab results were available.

Follow-up 5: 16 days after initial presentation

The patient returned six days later. His exam was stable to slightly improved. His BCVA was 20/50, anterior chamber reaction was stable at 1+, vitreal reaction appeared slightly improved at 1+, the keratic precipitates were resolved, and the fundus lesion appeared stable to slightly smaller. The remainder of the lab results were as follows: Lyme disease negative, RPR/FTA negative, ACE 58 (and considered normal), quantiferon gold positive, and Bartonella negative. Due to the posterior location of the lesion and its relative stability and slow improvement, an intravitreal injection of clindamycin was administered.

Follow-up 6: three weeks after initial presentation

The patient returned five days later with a BCVA of 20/40- OD. He had inadvertently recently run out of prednisolone drops, but his overall ocular inflammation had decreased somewhat with slight improvement in anterior chamber and vitreous cells. The chorioretinal lesion appeared to be slightly smaller. The patient was started on oral prednisone 60 mg daily and resumed topical prednisolone 1% qid. He was to continue brimonidine bid and oral azithromycin 500 mg daily. Cyclopentolate was discontinued because the inflammation had improved significantly.

Follow-up 7: four weeks after initial presentation

The patient returned one week later. His general ocular inflammation had decreased and the chorioretinal lesion showed

marked improvement. It was smaller and partially scarred at the site of the previous inflammation. His visual acuity was 20/25 OD. The patient was to begin tapering oral and topical prednisone. Brimonidine was discontinued because elevated IOP was no longer a concern.

Follow-up 8: two months after initial presentation

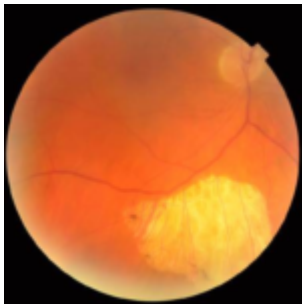

Figure 3. The lesion, 16 months after initial presentation, was inactive and atrophic.
[Click to enlarge](#)

The patient returned a month later. He had run out of azithromycin and had completed the oral prednisone taper. He was still taking topical prednisolone tid. His eye exam showed general improvement, and topical prednisolone was tapered to bid. He was to resume taking oral azithromycin 500 mg once daily.

Follow-up 9: three months after initial presentation

The patient returned a month later. The ocular inflammation appeared resolved. A chorioretinal scar was visible at the site of previous inflammation. A retinal vein occlusion with several dot hemorrhages was noted peripherally, just anterior to the scarred area. Azithromycin was discontinued. The patient was released from the care of the uveitis specialist and instructed to return to his primary eyecare provider in a year.

Follow-up 10: 16 months after initial presentation

The patient returned for a follow-up appointment 16 months after his initial presentation. He was not taking any ocular medications. He reported that he had not noticed any floaters recently. His BCVA was 20/20 OD, 20/20 OS. He had no active ocular inflammation, and the chorioretinal scar in the posterior pole OD appeared inactive and atrophic. **(Figure 3)** OCT showed a completely atrophic retina and choroid in the area of the lesion. **(Figure 4)** Of note, there was a retinal vein occlusion anterior to the lesion, likely a result of the atrophy of the vessels overlying the lesion.

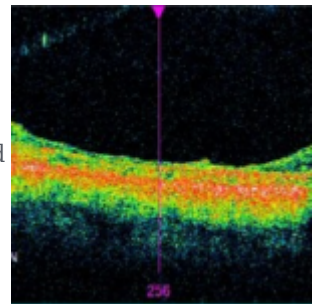


Figure 4. OCT showing completely atrophic retina and choroid at the site of previous inflammation.
[Click to enlarge](#)

Education Guidelines

Key concepts

1. The first step in diagnosing uveitis must be to make careful observations about the patient's symptoms and clinical signs of the uveitis, information gathered from a thorough eye exam that includes a dilated fundus exam and IOP check
2. Classifying the uveitis according to location, laterality, chronicity and type (granulomatous vs. non-granulomatous) is an essential beginning step that aids in developing a list of differential diagnoses
3. Integrating the patient's uveitis symptoms and past history of the uveitis as well as the patient's medical history are another important aspect of considering possible diagnoses
4. Diagnostic testing should be ordered according to the list of possible diagnoses; the sensitivity and specificity of each lab test and the likelihood of disease should be considered
5. Infection or malignancy must be recognized and successfully treated before beginning steroid treatment

Learning objectives

1. To make careful observations about the signs of the uveitis: location, laterality, granulomatous vs. non-granulomatous, and chronicity (acute, chronic, recurrent)
2. To integrate facts about the uveitis symptoms, previous episodes of uveitis, the patient's demographic information and medical history
3. To analyze the observations and facts and develop a list of differential diagnoses

4. To tailor diagnostic testing according to the developed list of differential diagnoses:
 - a. testing should be appropriately matched to the description of uveitis
 - b. sensitivity and specificity of each laboratory test should be considered
 - c. likelihood of disease should be assessed before ordering testing
5. To understand that infection or malignancy must be successfully treated before anti-inflammatory medications are started

Discussion questions

1. Why is it important to first note the location, laterality, type and chronicity of the uveitis as well as patient demographics? How will these observations assist in compiling a list of possible diagnoses?
2. Why is it important to order laboratory testing according to the patient's specific uveitis characteristics?
3. How do the sensitivity and specificity of lab tests and the likelihood of disease affect which testing should be ordered?
4. Why is it important to rule out or treat infection or malignancy before adding anti-inflammatory medication?

Discussion

On the day of presentation, the patient was diagnosed with a unilateral, granulomatous uveitis. The inflammation was clearly anterior, but it was unclear whether there was further involvement due to the poor view of the posterior pole, which was possibly due to the anterior chamber reaction, corneal edema or vitreal cells. Chronicity was uncertain because the patient was not sure how long the spot in his right eye had been present. He had noticed it a couple of weeks earlier, but that was perhaps due to his recent hunting activity with the opening of bow season. His last complete eye exam with dilation had been performed two years prior and was unremarkable. The patient was not symptomatic for pain or photophobia, implying that his condition may have been chronic. Also of note was the larger pupil, the sluggish pupillary response, and the increased IOP in the affected eye. This was likely due to synechiae beginning to form. Cyclopentolate easily dilated the eye without any signs of posterior synechiae remaining.

When he presented for his first follow-up visit, the posterior pole was much easier to view, and a yellow inflammatory chorioretinal lesion could be seen. As inflammation could be seen in the posterior pole as well as in the anterior chamber, this was classified as a case of panuveitis. The patient initially presented with a chief complaint of a spot moving around in his right eye. The symptomatic spot was likely the chorioretinal lesion. Alternatively, it could have been caused by vitreal cells. The chorioretinal lesion and the granulomatous nature of the uveitis could be associated with a number of conditions such as tuberculoma, lymphoma, syphilis, toxoplasmosis, Bartonella or sarcoidosis, most of which can present with variable ocular signs, locations in the eye, laterality and symptoms.

With the patient's history of owning and interacting with cats and the positive toxoplasmosis lab results, that diagnosis moved to the top of the list of possibilities. Due to the patient's history of a positive purified protein derivative test 15 years prior, tuberculoma was also high on the list. The patient was started on azithromycin at that point, one of several possible treatments for toxoplasmosis. After a week on azithromycin, the ocular inflammation appeared stable to slightly improved. The remaining lab results came back negative, decreasing the likelihood that other conditions were the cause of the panuveitis. The only other positive lab result was the quantiferon gold, which is likely to remain positive in patients who have a history of tuberculoma. Because the toxoplasmosis diagnosis seemed even more likely, and because the chorioretinal lesion had not appeared to improve much with treatment, an intravitreal injection of clindamycin was administered at that visit. Five days later, when the infection appeared to be resolved or nearly resolved, oral prednisone was started to help decrease the posterior segment inflammation.

Choosing appropriate laboratory testing in uveitis

TABLE 1
Ocular Manifestations and Characteristics of Different Systemic Diseases

SYSTEMIC DISEASE	OCULAR MANIFESTATIONS	CHARACTERISTICS	LABORATORY TESTS	REMARKS
Systemic lupus erythematosus (SLE)	Anterior uveitis, posterior uveitis, retinitis, chorioretinitis, optic neuritis, retinal vasculitis	Acute, recurrent, bilateral	Antinuclear antibody (ANA), anti-dsDNA, anti-Sm, anti-RNP, anti-SSA, anti-SSB, anti-Scl-70, anti-Jo-1, anti-Ro/SSA, anti-La/SSB, anti-U1-RNP, anti-U3-RNP, anti-U4-RNP, anti-U5-RNP, anti-U6-RNP, anti-U1+2+3+4+5+6-RNP, anti-U1+2+3+4+5+6-RNP, anti-U1+2+3+4+5+6-RNP	Can be bilateral
Rheumatoid arthritis (RA)	Anterior uveitis, posterior uveitis, retinitis, chorioretinitis, optic neuritis, retinal vasculitis	Acute, recurrent, bilateral	Rheumatoid factor (RF), anti-CCP, anti-MMP-1, anti-MMP-2, anti-MMP-3, anti-MMP-4, anti-MMP-5, anti-MMP-6, anti-MMP-7, anti-MMP-8, anti-MMP-9, anti-MMP-10, anti-MMP-11, anti-MMP-12, anti-MMP-13, anti-MMP-14, anti-MMP-15, anti-MMP-16, anti-MMP-17, anti-MMP-18, anti-MMP-19, anti-MMP-20, anti-MMP-21, anti-MMP-22, anti-MMP-23, anti-MMP-24, anti-MMP-25, anti-MMP-26, anti-MMP-27, anti-MMP-28, anti-MMP-29, anti-MMP-30, anti-MMP-31, anti-MMP-32, anti-MMP-33, anti-MMP-34, anti-MMP-35, anti-MMP-36, anti-MMP-37, anti-MMP-38, anti-MMP-39, anti-MMP-40, anti-MMP-41, anti-MMP-42, anti-MMP-43, anti-MMP-44, anti-MMP-45, anti-MMP-46, anti-MMP-47, anti-MMP-48, anti-MMP-49, anti-MMP-50, anti-MMP-51, anti-MMP-52, anti-MMP-53, anti-MMP-54, anti-MMP-55, anti-MMP-56, anti-MMP-57, anti-MMP-58, anti-MMP-59, anti-MMP-60, anti-MMP-61, anti-MMP-62, anti-MMP-63, anti-MMP-64, anti-MMP-65, anti-MMP-66, anti-MMP-67, anti-MMP-68, anti-MMP-69, anti-MMP-70, anti-MMP-71, anti-MMP-72, anti-MMP-73, anti-MMP-74, anti-MMP-75, anti-MMP-76, anti-MMP-77, anti-MMP-78, anti-MMP-79, anti-MMP-80, anti-MMP-81, anti-MMP-82, anti-MMP-83, anti-MMP-84, anti-MMP-85, anti-MMP-86, anti-MMP-87, anti-MMP-88, anti-MMP-89, anti-MMP-90, anti-MMP-91, anti-MMP-92, anti-MMP-93, anti-MMP-94, anti-MMP-95, anti-MMP-96, anti-MMP-97, anti-MMP-98, anti-MMP-99, anti-MMP-100	Can be bilateral
Sjögren's syndrome	Anterior uveitis, posterior uveitis, retinitis, chorioretinitis, optic neuritis, retinal vasculitis	Acute, recurrent, bilateral	Rheumatoid factor (RF), anti-CCP, anti-MMP-1, anti-MMP-2, anti-MMP-3, anti-MMP-4, anti-MMP-5, anti-MMP-6, anti-MMP-7, anti-MMP-8, anti-MMP-9, anti-MMP-10, anti-MMP-11, anti-MMP-12, anti-MMP-13, anti-MMP-14, anti-MMP-15, anti-MMP-16, anti-MMP-17, anti-MMP-18, anti-MMP-19, anti-MMP-20, anti-MMP-21, anti-MMP-22, anti-MMP-23, anti-MMP-24, anti-MMP-25, anti-MMP-26, anti-MMP-27, anti-MMP-28, anti-MMP-29, anti-MMP-30, anti-MMP-31, anti-MMP-32, anti-MMP-33, anti-MMP-34, anti-MMP-35, anti-MMP-36, anti-MMP-37, anti-MMP-38, anti-MMP-39, anti-MMP-40, anti-MMP-41, anti-MMP-42, anti-MMP-43, anti-MMP-44, anti-MMP-45, anti-MMP-46, anti-MMP-47, anti-MMP-48, anti-MMP-49, anti-MMP-50, anti-MMP-51, anti-MMP-52, anti-MMP-53, anti-MMP-54, anti-MMP-55, anti-MMP-56, anti-MMP-57, anti-MMP-58, anti-MMP-59, anti-MMP-60, anti-MMP-61, anti-MMP-62, anti-MMP-63, anti-MMP-64, anti-MMP-65, anti-MMP-66, anti-MMP-67, anti-MMP-68, anti-MMP-69, anti-MMP-70, anti-MMP-71, anti-MMP-72, anti-MMP-73, anti-MMP-74, anti-MMP-75, anti-MMP-76, anti-MMP-77, anti-MMP-78, anti-MMP-79, anti-MMP-80, anti-MMP-81, anti-MMP-82, anti-MMP-83, anti-MMP-84, anti-MMP-85, anti-MMP-86, anti-MMP-87, anti-MMP-88, anti-MMP-89, anti-MMP-90, anti-MMP-91, anti-MMP-92, anti-MMP-93, anti-MMP-94, anti-MMP-95, anti-MMP-96, anti-MMP-97, anti-MMP-98, anti-MMP-99, anti-MMP-100	Can be bilateral
Granulomatous disease	Anterior uveitis, posterior uveitis, retinitis, chorioretinitis, optic neuritis, retinal vasculitis	Acute, recurrent, bilateral	Rheumatoid factor (RF), anti-CCP, anti-MMP-1, anti-MMP-2, anti-MMP-3, anti-MMP-4, anti-MMP-5, anti-MMP-6, anti-MMP-7, anti-MMP-8, anti-MMP-9, anti-MMP-10, anti-MMP-11, anti-MMP-12, anti-MMP-13, anti-MMP-14, anti-MMP-15, anti-MMP-16, anti-MMP-17, anti-MMP-18, anti-MMP-19, anti-MMP-20, anti-MMP-21, anti-MMP-22, anti-MMP-23, anti-MMP-24, anti-MMP-25, anti-MMP-26, anti-MMP-27, anti-MMP-28, anti-MMP-29, anti-MMP-30, anti-MMP-31, anti-MMP-32, anti-MMP-33, anti-MMP-34, anti-MMP-35, anti-MMP-36, anti-MMP-37, anti-MMP-38, anti-MMP-39, anti-MMP-40, anti-MMP-41, anti-MMP-42, anti-MMP-43, anti-MMP-44, anti-MMP-45, anti-MMP-46, anti-MMP-47, anti-MMP-48, anti-MMP-49, anti-MMP-50, anti-MMP-51, anti-MMP-52, anti-MMP-53, anti-MMP-54, anti-MMP-55, anti-MMP-56, anti-MMP-57, anti-MMP-58, anti-MMP-59, anti-MMP-60, anti-MMP-61, anti-MMP-62, anti-MMP-63, anti-MMP-64, anti-MMP-65, anti-MMP-66, anti-MMP-67, anti-MMP-68, anti-MMP-69, anti-MMP-70, anti-MMP-71, anti-MMP-72, anti-MMP-73, anti-MMP-74, anti-MMP-75, anti-MMP-76, anti-MMP-77, anti-MMP-78, anti-MMP-79, anti-MMP-80, anti-MMP-81, anti-MMP-82, anti-MMP-83, anti-MMP-84, anti-MMP-85, anti-MMP-86, anti-MMP-87, anti-MMP-88, anti-MMP-89, anti-MMP-90, anti-MMP-91, anti-MMP-92, anti-MMP-93, anti-MMP-94, anti-MMP-95, anti-MMP-96, anti-MMP-97, anti-MMP-98, anti-MMP-99, anti-MMP-100	Can be bilateral
Idiopathic	Anterior uveitis, posterior uveitis, retinitis, chorioretinitis, optic neuritis, retinal vasculitis	Acute, recurrent, bilateral	Rheumatoid factor (RF), anti-CCP, anti-MMP-1, anti-MMP-2, anti-MMP-3, anti-MMP-4, anti-MMP-5, anti-MMP-6, anti-MMP-7, anti-MMP-8, anti-MMP-9, anti-MMP-10, anti-MMP-11, anti-MMP-12, anti-MMP-13, anti-MMP-14, anti-MMP-15, anti-MMP-16, anti-MMP-17, anti-MMP-18, anti-MMP-19, anti-MMP-20, anti-MMP-21, anti-MMP-22, anti-MMP-23, anti-MMP-24, anti-MMP-25, anti-MMP-26, anti-MMP-27, anti-MMP-28, anti-MMP-29, anti-MMP-30, anti-MMP-31, anti-MMP-32, anti-MMP-33, anti-MMP-34, anti-MMP-35, anti-MMP-36, anti-MMP-37, anti-MMP-38, anti-MMP-39, anti-MMP-40, anti-MMP-41, anti-MMP-42, anti-MMP-43, anti-MMP-44, anti-MMP-45, anti-MMP-46, anti-MMP-47, anti-MMP-48, anti-MMP-49, anti-MMP-50, anti-MMP-51, anti-MMP-52, anti-MMP-53, anti-MMP-54, anti-MMP-55, anti-MMP-56, anti-MMP-57, anti-MMP-58, anti-MMP-59, anti-MMP-60, anti-MMP-61, anti-MMP-62, anti-MMP-63, anti-MMP-64, anti-MMP-65, anti-MMP-66, anti-MMP-67, anti-MMP-68, anti-MMP-69, anti-MMP-70, anti-MMP-71, anti-MMP-72, anti-MMP-73, anti-MMP-74, anti-MMP-75, anti-MMP-76, anti-MMP-77, anti-MMP-78, anti-MMP-79, anti-MMP-80, anti-MMP-81, anti-MMP-82, anti-MMP-83, anti-MMP-84, anti-MMP-85, anti-MMP-86, anti-MMP-87, anti-MMP-88, anti-MMP-89, anti-MMP-90, anti-MMP-91, anti-MMP-92, anti-MMP-93, anti-MMP-94, anti-MMP-95, anti-MMP-96, anti-MMP-97, anti-MMP-98, anti-MMP-99, anti-MMP-100	Can be bilateral

Table 1.
[Click to enlarge](#)

Diagnostic testing should be chosen according to the most likely differential diagnoses. Ordering nonspecific laboratory testing is inefficient, expensive and can provide useless and even misleading information. This can be a challenging process, but it is important to carefully consider which tests would be most helpful in diagnosing the patient. One important concept is estimating the likelihood of disease based on the patient's signs, symptoms and history. Another important factor is understanding the sensitivity and specificity of each test in order to determine how much weight a test result should have in the overall picture of the patient's case. Some individual research may need to be performed by the provider before laboratory testing is ordered, especially when considering a more complicated uveitis. **Table 1** provides a summary of differential diagnoses that were considered in this case along with their specific characteristics and lab tests ordered.¹

Serology testing for toxoplasmosis

When the lab results were received, the positive IgG and IgM results strongly supported the diagnosis of toxoplasmosis. Ocular toxoplasmosis is the most common cause of posterior uveitis.²⁻⁴ A case of acquired toxoplasmosis in a 62-year-old patient, however, is unusual. It is thought that the majority of cases of toxoplasmosis are congenital with later reactivation, especially if ocular disease is present.⁵ It is more common for acquired toxoplasmosis to present unilaterally, while congenital toxoplasmosis infections more often present bilaterally.⁴

The presence of IgM antibodies on serology testing indicates an acute infection and levels remain elevated for about one year following the initial exposure.² On the other hand, IgG antibodies indicate a previous exposure and are detectable for life.² If IgM antibodies against *Toxoplasma gondii* are present, it signals an active infection. While doctors had no previous IgM or IgG testing for this patient to aid in definitively determining whether this case was congenital or acquired, due to the patient's age and the positive IgM results, it was concluded that this was an acquired case. In addition, the patient's previous eye exam showed no remarkable findings, including no signs of past inflammation. The other indication that this case was acquired was the absence of chorioretinal scars, which would indicate a previous episode. Therefore, the patient was diagnosed as having presumed primary acquired toxoplasmosis. An exact mode of transmission for acquiring the toxoplasmosis remained uncertain after discussion with the patient, but interaction with his cats seems quite possible.

Transmission

Toxoplasmosis can be transmitted to humans through a number of avenues. Oocytes are found only in the intestines of cats and may be transmitted to humans or other animals through cat feces. The oocytes develop into tachyzoites and rapidly divide in cells, causing destruction of tissue and spreading the infection. Tachyzoites can also infect the fetus of a pregnant woman. Tachyzoites can form cysts called bradyzoites containing thousands of organisms and are typically found in muscle or neural tissue. Ingestion of undercooked meat contaminated with these cysts is another possible mode of transmission, as is drinking water contaminated with oocytes.^{1,3,5,6}

Signs and symptoms of toxoplasmosis

Ocular symptoms of toxoplasmosis often include floaters, caused by vitreous cells and debris, and decreased vision, typically caused by inflammatory lesions in the macula.^{5,7} Ocular signs include anterior chamber inflammation, elevated intraocular pressure, vitritis, retinitis, vasculitis, disc edema secondary to peripapillary retinitis and, in rare cases, hard exudates in the macular area.⁷ The location of chorioretinal lesions has a significant impact on visual acuity, with macular lesions being the most sight-threatening.⁶ In a study of 248 patients, an outbreak of *T gondii* retinitis was discovered in the residents of Coimbatore, India, in 2004-2005. Among those 248 patients (254 eyes), 230 eyes were found to have unifocal retinitis. The retinal lesions were all raised and yellow with poorly defined borders. They healed over time and resulted in retinal scarring.⁷

Treatment of toxoplasmosis

There are several treatment options for managing toxoplasmosis, with some controversy regarding one antibiotic vs. another, and when corticosteroids should be initiated. Typically prescribed medications include pyrimethamine, sulfadiazine, clindamycin, trimethoprim/sulfamethoxazole, azithromycin and corticosteroids. None of the *T gondii*-specific antibiotics are able to penetrate the cyst walls of the bradyzoite form, but they are thought to limit proliferation of the tachyzoites during active disease. Corticosteroids are used to decrease inflammation and scarring, but due to the risk of increasing parasite proliferation, they must be used in conjunction with antibiotics. In addition, there is some question as to whether corticosteroids could increase the chance of future recurrence of the disease.^{7,8}

Differential Diagnosis

In this particular case, other conditions involving chorioretinitis with corresponding panuveitis that were considered were tuberculoma, lymphoma, syphilis, Bartonella, and sarcoidosis.

Tuberculosis

Ocular tuberculosis most commonly presents as a posterior uveitis, although it can also manifest as granulomatous anterior, intermediate or panuveitis.⁹ If posterior uveitis is present, it often indicates choroidal involvement, which can include subretinal abscess, tubercles and tuberculomas.⁹ Choroidal tubercles are small nodules, less than 1/4 disc diameter, and result in a scar when healed.⁹ Tubercles can also develop into a choroidal tuberculoma that is often associated with an exudative retinal detachment.⁹ The quantiferon gold result was positive in this case, which is consistent with the patient's history of previously testing positive for tuberculoma and undergoing treatment. Our patient was not experiencing any systemic symptoms of active tuberculoma at the time of presentation.

Lymphoma

Primary intraocular lymphoma can also present as a uveitis and vitritis. As with toxoplasmosis, patients often complain of blurred vision and floaters.¹⁰ Fluorescein angiography (FA) is useful in the diagnosis of primary intraocular lymphoma.¹⁰ Window defects on FA indicate tumor infiltrates, and leakage on FA, which indicates inflammation, is not usually present.¹⁰ In this case, an FA was not performed. Once the IgM and IgG test results were known to be positive, the CBC was normal, and the clinical course proceeded as expected, this case was determined to be toxoplasmosis.

Syphilis

Ocular syphilis can present as uveitis, vitritis, retinitis, retinal vasculitis, papillitis or neuroretinitis.¹¹ The uveitis associated with syphilis may present as granulomatous or non-granulomatous.¹¹ Serology testing for syphilis involves both Treponema-specific and non-Treponemal tests.¹¹ The Treponema-specific test, FTA-ABS, was ordered. In this case, the FTA-ABS was negative, so ocular syphilis was ruled out.

Bartonella

Another differential diagnosis considered was Bartonella. The mode of transmission of the bacteria Bartonella to humans is largely through cat fleas.¹² Cats' claws can become contaminated with the Bartonella species via the cat flea feces, and transmission to humans can occur through a cat scratch, bite or cat saliva at an open wound.¹² The different species of Bartonella, of which there are more than 20, have varying ocular manifestations. The most common ocular manifestations of Bartonella include Parinaud oculoglandular syndrome, choroiditis, retinitis, neuroretinitis, vasculitis and anterior and intermediate uveitis.¹² In this case, the lab testing for Bartonella was negative, and the clinical appearance of the uveitis was more consistent with toxoplasmosis than Bartonella.

Sarcoidosis

Sarcoidosis is an inflammatory disease that affects many organs in the body, including the eyes. Its etiology is unknown, and it is characterized by non-caseating granulomas.¹³ Sarcoidosis manifests ocularly as a granulomatous uveitis. It often presents posteriorly and typically presents bilaterally.¹³ In this case, the ACE level was not considered elevated, and the patient did not show systemic signs or symptoms of sarcoidosis, so it was ruled out.

Conclusion

This teaching case report illustrates a case of unilateral granulomatous panuveitis. While uncommon, this case was determined to be one of acquired ocular toxoplasmosis. One valuable point in this case is the importance of dilation in general, and specifically in this episode of panuveitis. Viewing the posterior pole was not only critical for diagnosis but also for follow-up appointments for determining if and how well the patient was responding to treatment. Lab results also played an important role in the diagnosis in this case. This patient was seen in a hospital setting, but if laboratory testing is not readily available at a clinic site, referrals can easily be made. With treatment consisting of topical prednisolone, cyclopentolate, oral azithromycin, intravitreal clindamycin and the later addition of oral prednisone, this patient's chorioretinitis eventually resolved with minimal ocular complication.

References

1. Nussenblatt RB, Whitcup SM. Uveitis: fundamentals and clinical practice: 4th edition. China: Mosby Elsevier, 2010.

2. Saffra NA, Seidman CJ, Weiss LM. Ocular toxoplasmosis: controversies in primary and secondary prevention. *J Neuroinfectious Dis.* 2013;4:4-6.
3. Harrell M, Carvounis P. Current treatment of toxoplasma retinochoroiditis: an evidence-based review. *J Ophthalmol.* 2014 [08/13/2014]. Available from: <https://www.ncbi.nlm.nih.gov/pmc/articles/PMC4147351/>.
4. Delair E, Monnet D, Grabar S, Dupouy-Camet J, Year H, Brezin AP. Respective roles of acquired and congenital infections in presumed ocular toxoplasmosis. *Am J Ophthalmol.* 2008;146:851-855.
5. Balasundaram MB, Andavar R, Palaniswamy M, Venkatapathy N. Outbreak of acquired ocular toxoplasmosis involving 248 patients. *Arch Ophthalmol.* 2010;128(1):28-32.
6. Bass SJ, Sherman J. (1995). Toxoplasmosis. In Marks ES, Adamczyk DT, Thomann KH (Ed.), *Primary eyecare in systemic disease* (2nd ed. pp 484-492). New York, NY: The McGraw-Hill Companies, Inc.
7. Lashay A, Mirshahi A, Parandin N, Esfahani HR, Mazloumi M, Reza M, Leshay MR, Johari MK, Ashrafi E. A prospective randomized trial of azithromycin versus trimethoprim/sulfamethoxazole in treatment of toxoplasmic retinochoroiditis. *J Curr Ophthalmol.* 2016 Dec 28;29(2):120-125.
8. Reich M, Becker MD, Mackensen F. Influence of drug therapy on risk of recurrence of ocular toxoplasmosis. *Br J Ophthalmol.* 2016;100:195-199.
9. Shirodkar A, Albinia T. Tuberculosis: intraocular involvement. *Review of Ophthalmology.* 2010 [03/09/2010]. Available from: <https://www.reviewofophthalmology.com/article/tuberculosis-intraocular-involvement>.
10. Jahnke K, Thiel E, Abrey LE, Neuwelt, Korfel A. Diagnosis and management of primary intraocular lymphoma: an update. *Clin Ophthalmol.* 2007;1(3):247-258.
11. Doris JP, Saha K, Jones NP, Sukthankar A. Ocular syphilis: the new epidemic. *Eye.* 2006;20:703-705.
12. Katogeropoulos C, Koumpoulis I, Mentis A, Pappa C, Zafeiropoulos P, Aspiotis M. Bartonella and intraocular inflammation: a series of cases and review of literature. *Clin Ophthalmol.* 2011;5:817-829.
13. Cunningham ET, Lowder CY, Miserocchi E, Thorne JE, Zierhut M. Sarcoid uveitis. *Ocul Immunol Inflamm.* 2014;22(4):253-6.



Dr. Lucas [Linda.Lucas2@va.gov] is the Optometry Residency Program Supervisor and the Student Externship Coordinator at the Marion, Ill., VA Medical Center. She completed her residency in Primary Care and Low Vision at the Kansas City VA Medical Center and has been a VA staff optometrist for 18 years.

Dr. Vanway completed her residency in Primary Care and Low Vision at Kansas City VA in 2002. She has worked as a preceptor for fourth-year optometry students from the University of the Incarnate Word Rosenberg School of Optometry, the University of Missouri at St. Louis College of Optometry, and New England College of Optometry.

TEACHING OCULAR IMAGING, DISEASE DIAGNOSIS AND MANAGEMENT WITHIN A WORK-INTEGRATED SETTING: A NOVEL MODEL WITHIN AN OPTOMETRIC EDUCATION PROGRAM

Abstract

Optometric educators are currently challenged to teach increasingly complex material (particularly relating to imaging technologies) within the constraints of pre-existing education programs. Innovation in work-based placements may be a solution. Here, we describe a novel clinical placement where students are intensively integrated into a referral-only, advanced ocular diagnostic and imaging clinic. Student involvement promoted practical and non-cognitive skill development among students and improved efficiency of service delivery in the clinic. These outcomes suggest full integration of students into the workplace operation may be an efficient alternative to observation-based or technician-based models.

Key Words: *work-integrated learning, undergraduate, optometry*

Introduction

Technological advancements in ocular imaging are rapidly redefining the way eye diseases such as glaucoma and macular degeneration are diagnosed and managed in optometric practice.

In Australia, the scope of practice of optometrists has expanded with the increasing accessibility of advanced imaging technologies as well as therapeutic endorsement of more than 50% of the profession to prescribe scheduled medicines for the treatment of ocular conditions.¹ There are underlying similarities with the scope of practice in other countries. For example, optometrists in the United States are able to perform enhanced primary care procedures such as the use of lasers in certain states.² With the expanding scope of practice of optometrists and ocular imaging technology becoming increasingly ubiquitous in optometric practice,³ optometric educators currently face the challenge of teaching progressively complex material within the time and resource constraints of pre-existing education programs. These constraints are augmented in new or accelerated optometry programs that aim to maximize teaching and learning in a shortened time frame or within a competitive educational environment.⁴⁻⁸ Consequently, the development of novel teaching models and curricular innovation, both for educating optometry students and upskilling optometrists in clinical practice, have been required to keep pace with these changes.

Specific challenges for optometric educators, community optometrists and optometry students include staying abreast of the plethora of new literature relating to the diagnosis and management of ocular diseases; understanding the application, limitations and interpretation of new imaging technologies such as optical coherence tomography angiography (OCTA); and gaining sufficient hands-on experience using these instruments. Typically, this education for students has taken the form of preclinical and theory-based training followed by clinical examination of patients within college- or university-operated clinics or community-based primary care optometry clinics, or observation-based placements within ophthalmology practices where advanced imaging is conducted by ophthalmic technicians. The length of this practical training varies across optometry programs internationally (average two years in the Australian education system vs. average three years in Doctor of Optometry programs in the United States⁹), but the fundamental goals are the same: to hone students' technical skills and, more importantly, ensure development of the analytical skills necessary to interpret results and render appropriate treatment plans. This is especially critical for current optometric practice where technical elements are increasingly being delegated to technicians.

However, evidence of poor performance in these skill areas by optometrists suggests these placements are not effectively transferring the students' complex theoretical knowledge into clinical skills. For example, Bakkum and Trachimowicz¹⁰ found optometrists in private practice were significantly less likely to correctly identify any of the 10 anatomical layers of the retina compared with optometry students despite this skill being essential for the correct interpretation of OCT images. Similarly, the emergence of "red disease"¹¹ and "green disease,"¹² pertaining to the misclassification of the presence or absence of pathology by the instrument, indicates the consequences of poor understanding relating to the limitations of each instrument and its normative database in clinical decision-making. Thus, implementing new education approaches to address these challenges is essential. Without sufficient training, an optometrist risks misinterpreting results and mismanaging patients.

The aim of this article is to present a novel, practical model for teaching advanced ocular imaging, disease diagnosis and management within a work-integrated setting. This model is implemented as a six-week placement at the Centre for Eye Health (CFEH) for final-year optometry students of the University of New South Wales (UNSW) Sydney, Australia. Students are fully integrated into the clinical pathway for the delivery of intermediate-tier imaging and visual system diagnostic services to patients with, or at risk of, eye disease. Background information about the model and curriculum structure as well as student outcomes and feedback are provided and discussed.

Teaching Model

Setting: Centre for Eye Health

CFEH is a unique optometry-led collaborative initiative of Guide Dogs NSW/ACT and UNSW Sydney, which has been described previously.^{13,14} Briefly, CFEH was established in November 2009 with a mission to reduce preventable blindness by providing diagnostic eye assessments, using state-of-the-art technology, at no cost to patients. CFEH is a referral-only clinic for non-urgent cases and has been validated to reduce unnecessary referrals to ophthalmologists for patients suspected of glaucoma¹³ or macular pathology.¹⁴

Patients presenting to CFEH are a unique cohort who have been identified by their referring optometrist or ophthalmologist as having an ocular abnormality or disease, or being at risk of disease development, but not requiring urgent ophthalmological treatment. Referring practitioners can opt to refer an individual for a comprehensive diagnostic test suite or for imaging tests in isolation. A subset of patients is referred directly to the collaborative care glaucoma clinic, under the oversight of a glaucoma specialist ophthalmologist, for treatment of previously diagnosed glaucoma. Since 2012, CFEH optometrists have examined more than 32,000 demographically diverse patients with the most commonly seen conditions being glaucoma suspect or glaucoma, macular degeneration, other macular pathology, diabetic retinopathy, peripheral retinal degenerations, pigmented lesions or suspected corneal ectasia.

The CFEH clinical team (15 optometrists and a clinical scientist) is responsible for the development, refinement and implementation of CFEH's novel protocols for examining patients, recalling patients to ensure that none is lost to follow-up, and communicating results to co-managing clinicians. Staff optometrists work closely with consultant ophthalmologists from the local public hospital ophthalmology service who provide indirect patient consultations by reviewing images and clinical data collated into a report by the examining optometrists and students. The clinical team is also intrinsically involved in optometric education, providing teaching within the optometry program of UNSW Sydney as well as postgraduate and continuing education for optometrists in clinical practice. Overall, the clinical team has a range of 3-15 years of experience in teaching optometric students.

Curriculum structure

Optometry schools in Australia have adopted various curriculum structures and course lengths ranging from a 3.5-year undergraduate degree, a combined five-year double degree and, most recently, more in line with the United States, a four-year postgraduate OD program. While variation exists among Australian optometric programs, they all essentially consist of at least one year of preclinical training and are followed by at least one year of practical clinical training.

TABLE 1
Curriculum Structure Overview*

Week	Learning/Practical Topics	Feedback Assessment	Notes
Prior to placement	View 10 one-hour digital video lectures Review clinically relevant papers		Familiarization with clinically relevant literature
1	Day 1 Two-hour orientation session Introduction to the technical operation of ocular imaging equipment Practice using equipment	One-on-one feedback	Outline details and expectations of placement Introduce students to the use and analysis of the latest commercially available equipment in ocular imaging Students to demonstrate competency in patient interaction and instrument operation
	Day 2 Observe a maximum of two staff optometrists assessing patients for a total of eight hours Individuals obtain images from a maximum of 10 test subjects on each test event	One-on-one feedback Practical assessment on key instruments at the end of day block	
	Day 3 Perform advanced imaging and functional testing on actual CFEH patients	Direct on-site supervision of a staff optometrist Report writing Individual feedback	Provides a hands-on practical component in using ocular imaging to assess patients Provides exposure to ocular disease patient assessment Develop confidence and knowledge in the diagnosis and management of ocular diseases Develop understanding of technical aspects of image interpretation, disease diagnosis and key grading scales
2	Four-hour block of seeing patients either in the morning or afternoon	Header test of 10 multiple choice questions at Week 2 Day 10	
3-6	Looping schedule where students alternate seeing every second patient for five-day (night hours block) period	Two-on-one supervision of a staff optometrist Report writing Individual feedback	Maximize efficiency in scheduling of patients Encourage time management and maximize staff development
Throughout the placement	Interactive case studies Problem-based learning cases Weekly grand round lectures Review of past patient records in "teaching cases" database Small group face-to-face tutorials Presentation of clinical analysis of emerging research	Immediate individual feedback with interactive digital learning materials and face-to-face general feedback and tutorial	Provides a range of learning materials to create a blended learning experience

*Note: A four-week curriculum was originally implemented where weeks 5 and 6 were not performed

Table 1. Click to enlarge

With regard to this model, students are enrolled in the combined Bachelor of Optometry/Bachelor of Science undergraduate course at UNSW Sydney, where they undertake a placement at CFEH as a mandatory requirement of the Clinical Ocular Therapy subject during Stage 5 (final year) of the program. **Table 1** gives an overview of the curriculum structure for this placement.

Overall aims of the placement are to improve the students' technical facility relating to advanced imaging modalities and to help them develop appropriate integrative and application skills in using these technologies. Students entering Stage 5 have already completed four years of optometry-specific undergraduate training and are equipped with a sound theoretical knowledge of the anatomy and physiology of the eye, ocular diseases and ocular therapeutics. Students have completed a year of practical hands-on training in the general optometry clinic at UNSW, gaining proficiency in clinical skills such as tonometry, pachymetry, gonioscopy, indirect ophthalmoscopy, funduscopy, and have had some exposure to specialized clinics in areas including contact lens, red eye and color vision.

Prior to beginning their placement, students are required to view 10 one-hour video lectures primarily focused on the differential diagnosis of ocular disease using advanced imaging modalities. They also familiarize themselves with clinically relevant literature related to image interpretation, disease diagnosis and management, and key grading scales such as the AREDS AMD severity scale.¹⁵ Students are scheduled to attend CFEH from 8:30 a.m. to 5 p.m., five days per week, for a total of six weeks. They attend in groups of 8-10 depending upon the total number of students enrolled in that year.

During the first three days, the details of the placement including expectations of professionalism and excellence in patient care delivery and the novel CFEH patient care pathway^{13,14} are outlined to the students. Referral forms and clinical protocols are discussed, and navigation of the customized electronic medical record system (VIP.net, Houston Medical) is demonstrated. The technical aspects of the imaging technologies are demonstrated using an apprenticeship approach. Students familiarize themselves with instrument operation and testing protocols through observing and interacting with supervising optometrists. The range of instruments includes Cirrus OCT (Zeiss), Spectralis OCT (Heidelberg), HRT3 (Heidelberg), Pentacam HR (Oculus), WX 3D non-mydratic stereo photography (Kowa), Optomap 200TX widefield imaging (Optos), E300 corneal topography (Medmont), IRX3 wavefront aberrometry (Imagine Eyes), Retinomax autorefraction, automated blood pressure measurement, and Humphrey visual field analysis. Instruction is provided on downloading images and reports from the instruments and importing them into the corresponding medical record, with the specific combination of images and/or reports tailored to the referral type and the number of previous visits. Orientation is concluded with a hurdle practical assessment to confirm student competency in providing clear and empathetic patient instructions, operating the instruments, troubleshooting image artifacts and technological issues, and obtaining high-quality images.

TABLE 2
Teaching Methodologies Used Within the CFEH Placement

Teaching Methodology	Description
Observation and practice (Apprenticeship approach)	<ul style="list-style-type: none"> Observe, remember and understand the technical operation of instruments demonstrated by clinical staff Apply and refine skills of operating equipment and assessing patients
Digital material (Blended teaching)	<ul style="list-style-type: none"> 10 one-hour video lectures produced by clinical staff (e.g., "When macula disease is not age-related macular degeneration" and "When does a glaucoma suspect convert to glaucoma?") 66 interactive case studies created by clinical staff CFEH "interesting cases" database with more than 2,500 patients categorized into different areas of pathology such as macula, glaucoma, optic nerve
Face-to-face learning (Blended teaching)	<ul style="list-style-type: none"> Problem-based learning case studies discussion with clinical staff Weekly interactive grand round lecture presentations by clinical staff Small group tutorials with "rapid-fire" question and answer sessions
Team presentation (Blended teaching)	<ul style="list-style-type: none"> Students work in pairs to present critical analysis of a current research paper in optometric literature to clinical staff followed by question and answer session
Higher-order thinking	<ul style="list-style-type: none"> Develop trouble-shooting skills for problems arising while examining patients Analyze and evaluate clinical test results to create a suitable report
Reflective practice	<ul style="list-style-type: none"> Reflecting on learning experiences from each case One-to-one discussion with supervising optometrist

Table 2. [Click to enlarge](#)

For the remainder of their placement, students perform advanced imaging and a range of functional testing on patients under the direct supervision of a staff optometrist. In a manner typical of fieldwork placements in other health professions,¹⁶ staff optometrists play an educative, supportive and administrative role in supervising students throughout the placement. Contact procedures (gonioscopy, ultrasonic pachymetry and applanation tonometry), funduscopy and ophthalmoscopy are performed by the staff optometrists. Students are offered the opportunity to examine patients with these techniques where it is deemed likely to further their understanding of the ocular pathology.

Following each patient assessment, students import relevant images and reports into the patient's medical record. Using custom report templates (**Appendix A**) students analyze the results of the patient consultation, list differential diagnoses, propose a diagnosis, discuss a suitable management plan, and reflect on the lessons garnered from the case. Student reports must be submitted within two days to the supervising optometrist (to simulate a true work environment) and individualized written feedback is provided. Final patient reports are written by supervising optometrists and co-signed by a second optometrist or a consultant ophthalmologist, as an additional means of quality control. Students are encouraged to review final reports to complete their learning experience. By the end of the placement, students have been exposed to a wide range of teaching strategies. (**Table 2**)

Student Outcomes

Student outcomes from the model were assessed from its implementation in 2014 to the end of 2016. Quantitative data included analysis of students' patient exposure and student feedback via a paper-based survey. Qualitative data were collected informally through discussion with supervisors and an open-ended comments section in the student survey. Note that there was a change in the curriculum described in Table 1 between 2016 and the previous years where weeks five and six were not performed because students were available only for a four-week period.

Number of patients seen

Individual students, on average, examined 88 patients during a six-week placement at CFEH. As CFEH is a referral-based centre, most patients had signs of ocular disease or were 'non-textbook' cases of diseases. Examinations lasted 30 minutes to two hours per patient and included the opportunity to conduct multiple tests, e.g., students conducting a glaucoma assessment performed visual acuity measurement, autorefraction, blood pressure measurement and Humphrey 24-2 perimetry, obtained retinal photographs, OCT and HRT3 images and assisted with patient history, tonometry, gonioscopy, pachymetry, funduscopy and slit lamp examination. The application of multiple teaching strategies (**Table 2**) meant students were also potentially exposed to a further 550 cases through peer discussions, tutorials, interactive case studies, digital video lectures, problem-based learning cases, grand rounds lectures presented by staff, and review of patient records.

Views from student supervisors

Informal discussions with supervising optometrists were used to determine impressions of student performance within the work-integrated student teaching model. Supervising clinicians commonly noted that student skills relating to the technical aspects of using advanced imaging devices improved over the course of placement. Examples of this improvement included fewer instances of images needing to be retaken by the supervisor or student due to poor quality and an overall reduction in the time taken to acquire images at later stages of the placement. Clinical skills relating to image interpretation and differential diagnosis were also reported to be improved. Specifically, supervising optometrists observed that students developed a greater understanding of how to recognize image artifacts, interpret results from patients who have anatomical or demographic features that fall outside the instrument-based normative database, and provide a cohesive diagnosis and management plan based on their patient reports.

Student survey results

Formal student feedback was collected through a 15-question survey at the end of each placement. Students were asked to rate the level of agreement that most accurately reflected their opinion on a 5-point Likert scale ranging from strongly agree (5) to strongly disagree (1). A summary of the results is provided in **Table 3**. An optional written comments section was also provided. Examples of student quotations are shown in **Table 4**.

TABLE 3
Student Survey Results

	2014 n=76	2015 n=65	2016 n=65	Average
Non-cognitive factors				
1. The CFEH clinical rotation helped motivate me to learn	4.5	4.7	4.9	4.7
2. The hands-on CFEH clinical rotation was useful in helping me improve my clinical confidence and understanding of testing protocols	4.4	4.5	4.9	4.7
Assessment methods				
3. I received helpful feedback on how I was doing in the CFEH clinical rotation	4.1	4.3	4.7	4.4
4. I found writing the CFEH patient summary reports helpful	4.2	4.5	4.6	4.4
Teaching methodologies				
5. The tutorials held during the rotation were useful both for clinical knowledge and the CFEH rotation itself	N/A	4.7	5.0	4.9
6. The course materials provided for the CFEH clinical rotation were useful (speakers, problem-based learning cases, etc.)	4.4	4.6	5.0	4.7
7. The CFEH teaching staff showed an interest in the needs of the students	4.7	4.6	4.8	4.7
8. I found the CFEH clinical update presentations useful (Tuesday lunchtime)	4.4	4.5	4.8	4.6
9. The volume of work in the CFEH clinical rotation was appropriate	3.2	4.0	4.4	3.9
Learning outcomes				
10. The CFEH clinical rotation was useful in helping me improve my differential diagnostic capabilities	4.3	4.7	4.9	4.6
11. The CFEH clinical rotation improved my knowledge and understanding of the role and interpretation of ocular imaging and other diagnostic tests	4.7	4.9	4.9	4.8
12. The CFEH clinical rotation helped deepen my understanding of ocular disease diagnosis and management	4.3	4.5	4.9	4.7
13. I had a clear understanding of what was expected of me in the CFEH clinical rotation	4.3	4.5	4.6	4.5
Satisfaction				
14. Overall, I was satisfied with the quality of the CFEH clinical rotation	4.4	4.6	4.9	4.7
15. Overall, I was satisfied with experience provided during the CFEH clinical rotation	4.5	4.6	5.0	4.8
Average score over all aspects	4.3	4.6	4.8	4.6

Each question was answered on a 5-point Likert scale. Numbers represent the average score where strongly disagree = 1; disagree = 2; neutral = 3; agree = 4; and strongly agree = 5.

Table 3. Click to enlarge

In terms of teaching methodologies, the tutorials were most highly rated, followed by the course materials and quality of the teaching staff. (**Table 3**) Summary reports and feedback were also helpful, achieving a score of 4.4 out of 5 each. Written comments regarding teaching methodologies also indicated that students valued face-to-face interaction with their supervisors such as in tutorials, discussions of problem-based learning cases, individual feedback and weekly grand round lectures and clinical

A total of 183 students across the three years (2014-2016) participated in the survey, which had a 100% response rate. Overall, an average of 4.6 out of 5 (strongly agree) was achieved for all aspects of the students' rotation at CFEH with a notable improvement in the survey scores across all aspects in each successive year. Students showed strong motivation to learn and rated the clinical rotation highly in assisting improvements in clinical confidence and understanding testing protocols (average score of 4.7 out of 5). Cultivation of non-cognitive factors such as self-learning, motivation and embracing challenges was also commonly noted by students in written comments (11 out of 53 comments).

TABLE 4
Examples of Student Written Feedback

1. General comments	<ul style="list-style-type: none"> I enjoyed the rotation and learned a lot - made me more knowledgeable and concise I found all components of the course very helpful I think I would have had a better learning experience if I was placed at the start of the semester rather than the end
2. Non-cognitive factors	<ul style="list-style-type: none"> ... I gained a lot of confidence in terms of imaging and management ... made me feel motivated to be a better clinician ... I was always extremely motivated to learn and study
3. Assessment methods	<ul style="list-style-type: none"> Too many reports at times ... I had trouble keeping up with the work load due to having lots of assignments due from other courses Summary reports were very helpful, however there was a stage of struggle with the work load (not a fault of CFEH rotation, but rather everything was due at the end of the rotation) ... initial days practicing with the machines helped us with confidence, professionalism and interpretation of results
4. Teaching methodologies	<ul style="list-style-type: none"> PBLs were great for learning and staff were enthusiastic to teach and help Tutorials were some of the best learning experiences. Maybe a quick MCQ occasionally would be good ... It's good that we got 1 on 1 feedback ... The staff really catered to our needs and inspired to help us learn Having more one on one time with supervisors to answer questions ... Perhaps more PBLs. Learn most from these (PBLs) and clinical updates Clinical updates (in particular the webinars) were very useful and broadened my knowledge. They provided good review and reinforced/filled any gaps in our knowledge
5. Learning outcomes	<ul style="list-style-type: none"> Loved if it really improved my knowledge on ocular diseases ... It has definitely helped to build my knowledge of the imaging machines and how to interpret them

Comments were analysed for common themes and grouped as general comments, comments on non-cognitive factors, assessment methods, teaching methodologies and learning outcomes
PBL = problem-based learning case; MCQ = multiple-choice question

Table 4. Click to enlarge

update meetings presented by staff. **(Table 4)** The appropriateness of the volume of work was rated the lowest (3.9 out of 5) with a number of written comments about the work load being too high (8 out of 53 comments). Forty percent of these comments, however, clarified that high work load was due to other assignments being due during the placement. Overall, survey scores and comments indicated students' perception of the placement was useful, helpful and enjoyable with students gaining confidence in ocular imaging and being motivated to learn.

Figure 1 depicts the number of patients examined per equivalent full-time (EFT) staff optometrist at CFEH before and following student model implementation. Prior to student integration, the two-year average was 673 patients/EFT optometrist. This was improved to 901 (134% increase) and 980 (146% increase) with the introduction of the four- and six-week placements respectively. This increase in efficiency was achieved in combination with scheduling changes that were allowed by the availability of students to participate in patient management. As students became more efficient in their technical skills, an initial one-on-one supervision was replaced by two-on-one supervision of a staff optometrist, which optimized staff and time resources within the clinic.

Discussion

The rapidly changing scope of optometric practice due to advances in ocular imaging technology means increasingly complex competencies are now required from optometrists.¹⁷ Australian optometric education is constantly evolving in response to the expanding scope of practice, in particular the incorporation of advanced technology and prescribing of therapeutic agents,^{1,17} as well as a changing educational landscape from the traditional mode of classroom teaching and learning to more flexible, self-directed, blended teaching and learning modalities. The challenge for optometric educators is to efficiently and effectively develop and deliver this material and provide students an environment where they can apply and translate their textbook knowledge to practical skills and learn to troubleshoot when challenges arise. At the same time, efficient use of clinic time and resources is required due to central fiscal demand. Here, we have described a successful, work-integrated teaching model enhanced by a range of teaching methodologies, where final-year students are intensively integrated into the clinical pathway within a unique workplace setting for six weeks. A discussion of the advantages and disadvantages of the model follow.

The model appears highly effective for teaching complex materials such as advanced ocular imaging and diagnosis

The advantages of work-integrated learning are well-established and include promotion of knowledge development, professional attitudes and communication.¹⁸ For example, community-based optometric placements have been successful in providing students with a broad range of experiences,¹⁹ promoting cultural competency²⁰ and community outreach.²¹ These placements also address entry-level competency standards for the profession of optometry in Australia,¹⁷ and similarly the New Professional Optometric Degree Standards as outlined by the Accreditation Council on Optometric Education (ACOE)²² by providing a platform for students to consolidate, integrate and apply their theoretical knowledge, hence ensuring essential clinical experience and competency to “independently practice contemporary optometry.” The resource-intensive nature of placements, however, is often cited as a limitation to implementing and extending these activities in curricula.^{20,23} Consequently, many placements utilize an observation-based approach, which limits the quantity, quality and variety of student interaction and practical skill development.

In this model, although a resource-intensive training period of three days was required at the beginning of the placement, the use of a range of teaching methodologies, direct involvement of students in patient care, and examination of a high volume of patients all seemed to be useful in promoting self-directed learning among students and reducing the teaching and resource load during the remainder of the placement. This may be of particular use to new or accelerated optometric programs that are faced with the additional challenges of developing sustainable clinical placement programs within a competitive educational space and shortened time frame. Examples of such programs offered in optometry schools include the 3.5-year undergraduate degree at Deakin University in Victoria, Australia, and the 36-month Accelerated Scholar's Program at Pennsylvania College of Optometry at Salus University in the United States, which emphasize early clinical

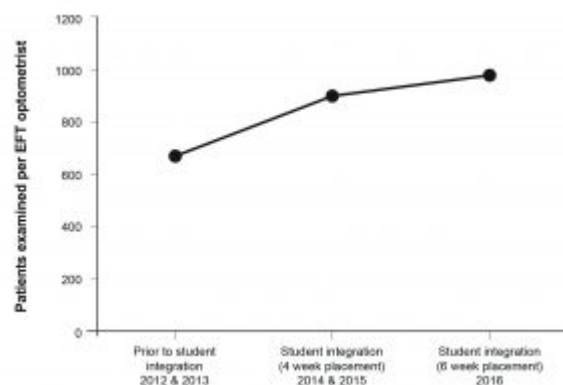


Figure 1. Number of patients seen per equivalent full-time (EFT) staff optometrist at the Centre for Eye Health prior to and following implementation of the teaching model.

[Click to enlarge](#)

exposure and extended clinical placements to allow students to continuously build on their clinical skills. However, specific challenges associated with an accelerated model in Australia include recruiting practices that are adequately equipped to accommodate students and overcoming clinic inefficiencies of students slowing down appointments.⁴ In particular among Australian optometrists, there is moderate support for extended clinical placement programs. The burden on time and decrease in number of patients examined are the top perceived disadvantages.²⁴ The CFEH model design led to outcomes that were beneficial for both the student and workplace, overcoming most of the challenges and perceived disadvantages of clinical placements.^{4,24} Student feedback indicated development of practical capabilities for using, interpreting and applying results from diagnostic imaging technologies within the six-week time frame. Concurrently, student integration allowed for greater service delivery by the clinic. Considering that the ability to interpret and apply results from diagnostic imaging technologies is now considered an entry-level competency by the main professional body for optometrists in Australia,¹⁷ this model demonstrates usefulness towards efficiency in learning these technologies.

The model promoted skills associated with lifelong learning, essential in the optometric profession

Optometry students are required, at a minimum, to attain a competent level of professionalism before they can enter the workforce, whereby they are able to consciously interpret available data and adjust management plans for specific patients or clinical situations. Optometry Australia, the leading professional body, has published detailed entry-level competency standards.¹⁷ Among a range of professional responsibilities, the ability to “continue to expand and update skills and knowledge for safe and evidence-based practice through adoption of a lifelong approach to learning” is deemed essential. The importance of embracing research and evidence-based practice and prioritizing these elements in curricular planning within schools and colleges of optometry has also been highlighted.²⁵ Student survey results indicated this teaching model promoted non-cognitive skills associated with critical reflection, self-learning and motivation, factors known to be essential to students’ success beyond university as they embark on their careers^{25,26} and in alignment with Faucher’s²⁷ description of professional expertise development.

Raising the standards of new graduates may have a beneficial flow-on effect of contributing to the prevention and reduction of eye diseases within the community. Furthermore, the uniqueness of this optometry-led clinic, its patient cohort and highly skilled optometric staff with a dedicated interest in diagnosis and management of ocular diseases also provides an adaptive learning environment. This environment and the ability to diagnose and manage eye disease more confidently, particularly in light of the increasing scope of optometric practice, could translate to improved career satisfaction when combined with effective programs to upskill the profession and train new graduates.

Student outcomes from this model were used to guide, refine and implement improvements and changes to the teaching methodologies and content

Student surveys and feedback were an important element in guiding and refining the teaching methodologies and materials with enhancements made to the instructional delivery and content. Such changes have resulted in improvements to the student survey scores across all aspects in each successive year. (**Table 3**) As students indicated that they valued face-to-face interactions, teaching methodologies were refined to place an emphasis on delivering these learning opportunities such as the implementation of weekly grand round lectures, tutorials and discussions of problem-based learning cases. Clinical update meetings and grand rounds-style lectures were also modified from a lecture mode presented by staff to “rapid-fire” question and answer sessions, resulting in greater student participation and interaction with their supervisors, as well as cultivating higher-order thinking. Tutorials were also updated to concentrate on areas where students showed the weakest knowledge based on student-supervisor discussions, performances on their hurdle test of 30 multiple-choice questions (MCQs), and other clinical performances such as communication, report writing and analyzing results, addressing both technical and, more importantly, analytical skills with an emphasis on management and diagnosis. Another aspect measured was volume of work, which garnered the lowest survey scores, although this was possibly confounded by other assignments that were due at the same time. Based on such feedback, report templates were streamlined to adjust the volume of work. This resulted in an improvement of survey scores from 3.2 to 4.4 out of 5, with summary report templates implemented at the final two weeks of the program. These summary report templates encouraged students to integrate relevant results in constructing a concise report and allowed clinical supervisors to prioritize students who needed more guidance in analyzing and integrating results. As evaluating teaching and learning methods are an important responsibility among education providers to ensure delivery of quality teaching and optimize student learning,²⁸⁻³² this model has measured outcomes using strategies such as student surveys and feedback as well as supervisor impressions. These methods have shown to be useful in refining teaching methodologies and content, as demonstrated by an increase in student satisfaction scores, and can be implemented in a variety of clinical settings to evaluate the effectiveness of teaching strategies and materials and to guide refinements.

This model may be enhanced by the integration of technological solutions to optimize clinical efficiency and extend the student learning experience

We acknowledge that areas within the current model may be improved by implementing technological solutions to transform current manual procedures and optimize the use of resources, in turn enhancing the student learning experience and creating a sustainable learning environment. Specifically, the use of tracking software such as Meditrek (Morrisville, Pa.) to capture the clinical supervisors' impressions of the progress of students will allow for more quantitative analysis of such information. Other enhancements that can be implemented include an electronic portfolio with the potential to allow students and supervisors to track their learning and competencies, expand feedback and interaction modalities, and build learning communities by enabling questions and case discussion with peers and supervisors via a digital platform. As teaching procedural and operational skills related to a vast range of ocular imaging equipment can place considerable burden on time and staff resources, digitizing certain aspects of instructional delivery may be beneficial. For example, instrument demonstration videos disseminated to and completed by students prior to their placement may be useful in allowing flexible, self-directed learning and optimizing use of face-to-face time with supervisors over the orientation period to refine techniques, discuss difficulties and learn to troubleshoot when problems arise. Such enhancements may be implemented in a variety of clinical placements requiring tracking of student-supervisor interaction, competency-based teaching and flexibility of the learning environment.

This model may be limited by the specific scope of the workplace environment

A potential limitation of this teaching model is the workplace setting: CFEH is an optometry-led, referral-only clinic for patients who have or are suspected of having ocular disease. The clinic is also based at a teaching and research institution and therefore staff knowledge is highly specialized and current with specific continuing education practices embedded within the workplace. We acknowledge that most optometry-driven clinics may not operate under such specific clinical protocols. However, most optometry education programs throughout the world are likely to include placements at clinics that utilize advanced ocular imaging technologies and have unique clinical pathways. For example, in most U.S. colleges, students undergo externships at various ocular disease specialty clinics during the final year of the program⁹ such as those offered by Nova Southeastern University.³³ In the United Kingdom, observation-based clinical placements at the Moorfields Eye Hospital are offered by the City University of London.³⁴ In this case, strategies used within the model, specifically the full integration of students into the workplace to perform service delivery and patient management with advanced imaging and the use of a variety of teaching methodologies should be applicable to a wide range of other clinical settings and contribute to positive outcomes such as those seen in this placement.

Conclusion

This article highlights the potential benefits of intensively integrating optometry students into a unique workplace environment dedicated to advanced ocular imaging and disease management. Survey results collated over three years show increasingly positive feedback from students in regard to various aspects of the model and cultivation of higher-order thinking and non-cognitive factors. The model also shows benefit to the workplace through improved efficiency in service delivery. Considering the increasing level of theoretical knowledge that needs to be taught to optometry students and the consequent pressure this places on finding opportunities to translate the knowledge into practical skills, models such as this may represent efficient methods of addressing these challenges.

References

1. Kiely PM, Cappuccio S, McIntyre E. Optometry Australia Scope of Practice Survey 2015. *Clin Exp Optom*. 2017;100(3):260-269.
2. Hepp R. Scope of practice battle rages in NC. *Review of Optometry*. 2017;154(3):4.
3. Ly A, Nivison-Smith L, Zangerl B, Assaad N, Kalloniatis M. Self-reported optometric practise patterns in age-related macular degeneration. *Clin Exp Optom*. 2017 Nov;100(6):718-728.
4. Weisinger HS, Prideaux D. Modernizing optometric education in Australia: ideas from medical education. *Optometric Education*. 2011;37(1):28-35.
5. Wang-Harris S. Optometric education in Trinidad and Tobago: developing a new program in the West Indies. *Optometric Education*. 2013;39(1):20-27.
6. Loughman J, Chan VF, Moodley VR, Bilotto L, Naidoo K. Student educational background, perceptions and expectations towards optometry: an emerging eye health profession Mozambique. *Optometric Education*. 2015;40(2):104-109.
7. Nehmad L, Appel J. The integrative track at SUNY State College of Optometry. *Optometric Education*. 2011;36(3):146-151.
8. Pennsylvania College of Optometry Accelerated Scholars Program. Accessed: 10 May 2017. Available from: [http://www.salus.edu/Colleges/Optometry-\(1\)/Doctor-of-Optometry-%E2%80%93-Accelerated-Scholars-Program.aspx](http://www.salus.edu/Colleges/Optometry-(1)/Doctor-of-Optometry-%E2%80%93-Accelerated-Scholars-Program.aspx).

9. Association of Schools and Colleges of Optometry (ASCO) Admissions Requirements Handbook. Accessed: 10 May 2017. Available from: <https://optometriceducation.org/wp-content/uploads/2013/08/ASCO-Admission-Requirements-Handbook-2013.pdf>.
10. Bakkum BW, Trachimowicz RA. Retention of knowledge of retinal microanatomy by optometric students, faculty and practitioners. *Optometric Education*. 2015;40(2):77-82.
11. Chong GT, Lee RK. Glaucoma versus red disease: imaging and glaucoma diagnosis. *Curr Opin Ophthalmol*. 2012;23(2):79-88.
12. Sayed MS, Margolisa M, Lee RK. Green disease in optical coherence tomography diagnosis of glaucoma. *Curr Opin Ophthalmol*. 2017;28(2):139-153.
13. Jamous KF, Kalloniatis M, Hennessy MP, Agar A, Hayen A, Zangerl B. Clinical model assisting with the collaborative care of glaucoma patients and suspects. *Clin Exp Ophthalmol*. 2015;43(4):308-319.
14. Ly A, Nivison-Smith L, Hennessy MP, Kalloniatis M. Collaborative care of non-urgent macular disease: a study of inter-optometric referrals. *Ophthalmic Physiol Opt*. 2016;36(6):632-642.
15. Age-Related Eye Disease Study Research Group. A simplified severity scale for age-related macular degeneration: AREDS Report No. 18. *Arch Ophthalmol*. 2005;123(11):1570-1574.
16. Stagnitti K, Schoo A, Welch D. Clinical and fieldwork placement in the health professions, page 164. Oxford University Press, Australia and New Zealand; 2010.
17. Kiely P, Slater J. Optometry Australia entry-level competency standards for optometry. *Clin Exp Optom*. 2015;98(1):65-89.
18. Ferns S, Moore K. Assessing student outcomes in fieldwork placements. *Asia-Pacific Journal of Cooperative Education*. 2012;13(4):207-224.
19. Wilson R, Sharda V. History of community health center affiliations with the New England College of Optometry. *Optometry*. 2008;79(10):594-602.
20. Truong M, Bentley S, Napper GA, Guest DJ, Anjou MD. How Australian and New Zealand schools of optometry prepare students for culturally competent practice. *Clin Exp Optom*. 2014;97(6):540-549.
21. Davis JG. In clinical optometric education, does extern outreach training produce outreach providers? *Optometric Education*. 2011;37(1):22-27.
22. Professional Optometric Degree Standards. American Optometric Association. Accessed: 10 May 2017. Available from: https://www.aoa.org/Documents/students/od_manual_08_2014.pdf.
23. Billett S. Curriculum and pedagogic bases for effectively integrating practice-based experiences. Final Report. Sydney, Australia: ALTC; 2011.
24. Bentley SA, Cartledge A, Guest DJ, Cappuccio S, Woods CA. Practitioner perspectives on extended clinical placement programs in optometry. *Clin Exp Optom*. 2016;99(3):248-257.
25. Adams AJ. The role of research, evidence and education in optometry: a perspective. *Clin Exp Optom*. 2007;90(4):232-237.
26. Nagaoka J, Farrington CA, Roderick M, Allensworth E, Keyes TS, Johnson DW, Beechum NO. Readiness for college: the role of noncognitive factors and context. *Voices in Urban Education* 2013. Accessed: 10 January 2017. Available from: <https://consortium.uchicago.edu/publications/readiness-college-role-noncognitive-factors-and-context>.
27. Faucher C. Development of professional expertise in optometry. *Optometry*. 2011;82(4):218-223.
28. Irby D, Rakestraw P. Evaluating clinical teaching in medicine. *Acad Med*. 1981;56(3):181-186.
29. Ramsey PG, Gillmore GM, Irby DM. Evaluating clinical teaching in the medicine clerkship: relationship of instructor experience and training setting to ratings of teaching effectiveness. *J Gen Intern Med*. 1988;3(4):351-355.
30. Beckman TJ, Ghosh AK, Cook DA, Erwin PJ, Mandrekar JN. How reliable are assessments of clinical teaching? A review of the published instruments. *J Gen Intern Med*. 2004;19(9):971-977.
31. Beckman TJ, Lee MC, Mandrekar JN. A comparison of clinical teaching evaluations by resident and peer physicians. *Med Teach*. 2004;26(4):321-325.
32. Snell L, Tallett S, Haist S, et al. A review of the evaluation of clinical teaching: new perspectives and challenges. *Med Educ*. 2000;34(10):862-70.
33. Nova Southeastern University College of Optometry. Doctor of Optometry Program. Externship Site List. Accessed: 10 May 2017. Available from: <https://optometry.nova.edu/od/externships/sites.html>.
34. City University of London Undergraduate Optometry Course. Accessed: 10 May 2017. Available from: <http://www.city.ac.uk/courses/undergraduate/optometry>.

Appendix A
Centre for Eye Health Glaucoma Suite Student Report Template

Glaucoma Suite

Supervisor:

Student name:

Date patient seen:

Patient name and ID:

Disc appearance (Kowa stereo photos)	Disc size, shape, orientation: NRR: PPA: Drance: RNFL:	Disc size, shape, orientation: NRR: PPA: Drance: RNFL:
Cirrus Is there asymmetry or areas of reduction? Is this relevant to glaucoma? Why/why not? Is the segmentation correct?		
Spectralis Are there any notable areas of anomalies in retinal architecture?		
HRT3 Does the color disc profile match the stereo disc appearance? MRA sectors flagged – does this correlate with other findings?		
Visual fields Are the fields reliable? Describe defects? Is this relevant to glaucoma?		
Case summary	Glaucoma specific historical risk profile? IOPs and pachymetry within norms/high/low/thick/thin? Angles open/narrow? Evidence of secondary glaucoma risk factors? Do the NRR appearance, imaging and visual fields correlate? If yes, what are the correlating features?	
Diagnosis and differentials (consider conditions other than glaucoma)	Diagnosis Differential diagnoses	
Management		
What have you learned from this case? In terms of the two major areas: 1. Patient interaction 2. Clinical case (write 1 point each)		
Supervising optometrist's comments		

NRR = neuroretinal rim; PPA = peripapillary atrophy; MRA = Moorfields regression analysis; RNFL = retinal nerve fiber layer

[Click to enlarge](#)

 Follow

 Share

Jaclyn Chiang [JChiang@cfeh.com.au] is a Senior Staff Optometrist at the Centre for Eye Health in Sydney, Australia, and is involved in developing continuing education material and clinical research in optic disc pathology.

Paula Katalinic is a Principal Optometrist at Centre for Eye Health in Sydney, Australia, and the part-time Professional Services Manager at Optometry Australia (NSW Division).

Dr. Nivison-Smith is a Senior Research Associate at the Centre for Eye Health and the School of Optometry and Vision Science at University of New South Wales Sydney. She researches retinal disease using basic science and clinical approaches and contributes to academic teaching.

Michael Yapp is the Chief Staff Optometrist at the Centre for Eye Health in Sydney, Australia. He also contributes to both undergraduate and postgraduate optometric education.

Dr. Zangerl is a Research Associate at University of New South Wales Sydney School of Optometry and Vision Science in Australia. After completing her education in medicine and genetics, she dedicated more than 15 years to the research of blinding disorders, maintaining a strong focus around differential diagnosis, prevention and treatment of various degenerative eye diseases applying advanced technologies. Her current position allows her to integrate current research outcomes into a contemporary curriculum for medical professionals and evaluate its effectiveness in clinical practice.

Dr. Khuu is Director of Teaching at the School of Optometry and Vision Science, University of New South Wales Sydney, in Australia and pursues research in cognitive and visual neuroscience.

Kathleen Watt is Clinic Director at the Optometry Clinic of the School of Optometry and Vision Science, University of New South Wales Sydney, in Australia.

Professor Kalloniatis is Director of the Centre for Eye Health in Sydney Australia. He also holds positions at optometry schools at the University of Melbourne, University of Auckland, University of Houston, Australian College of Optometry and University of New South Wales Sydney.

OCULAR CHRYSIASIS: A TEACHING CASE REPORT

Abstract

Ocular chrysiasis is a deposition of gold in ocular structures secondary to gold salt therapy, which is primarily used in infectious, rheumatoid and psoriatic arthritis. Gold therapy has become an extremely rare treatment due to the advent of rheumatologic medications with better safety profiles. However, any patient who has undergone gold therapy could potentially have ocular chrysiasis. Therefore, it must be included as a differential in the presence of corneal or lenticular changes in these patients. Additionally, it is important to include ocular chrysiasis as a differential in the presence of crystalline keratopathies. A detailed medical history and thorough ocular examination can assist clinicians in making a correct diagnosis.

Key Words: gold salts, ocular chrysiasis, autoimmune disease, cornea

Background

The following case report is meant to be used as a guide in teaching optometry students and residents. It is relevant to all levels of training. Ocular chrysiasis is a deposition of gold in ocular structures following chrysotherapy, which is the medical use of gold salts. Chrysotherapy was primarily used to treat infectious, rheumatoid and psoriatic arthritis. This therapy has become an extremely rare treatment due to the advent of rheumatologic medications with better safety profiles. Any patient who has undergone gold therapy could potentially have ocular chrysiasis. Therefore, it must be included as a differential in the presence of corneal or lenticular changes in these patients. This case illustrates the importance of history-taking skills, examination and decision-making in effectively diagnosing this condition.

Case Description

A 54-year-old Caucasian female presented for an annual eye examination. She reported a haze to her vision in bright conditions, as if she were continually looking through “dirty glasses.” She was wearing progressive lenses, primarily for reading. Ocular history was positive for dryness, seasonal allergies, bilateral LASIK in 1999, and past bouts of iritis. The patient was using a fish oil supplement and artificial tears as needed for dry eye. Her allergies were being treated with olopatadine hydrochloride ophthalmic solution (Pataday) and prednisolone acetate (Pred Forte), as needed, as prescribed by her previous optometrist.

Family ocular history was positive for dry age-related macular degeneration on her mother’s side. Her medical history was significant for high blood pressure controlled with hydrochlorothiazide and triamterene, migraines controlled with rizatriptan, diastolic dysfunction and heart block controlled with a pacemaker, and occasional oral herpes simplex treated with valacyclovir. In addition, she had a history of psoriasis, psoriatic arthritis and iritis, currently treated with etanercept (Enbrel) injections and calcipotriene (Dovonex) ointment. She reported no recurrences of iritis since starting Enbrel injections in 2000. She was a non-smoker and had no drug allergies. She was oriented to person, place and time.



Figure 1. Image of the patient's cornea, showing gold deposits, captured at the slit lamp using an iPhone 5.

[Click to enlarge](#)

Best-corrected vision was 20/15 OD with +0.25-0.50×030 and 20/15 OS with +0.50-0.50×015 at distance and 20/20 OU at near with a 2.50 add. Cover test was measured to be orthophoria at distance and 4 exophoria at near. Extraocular motility was full with no pain or diplopia. Pupils were equal, round and reactive to light with no afferent defects. Visual field was full based on screening with frequency doubling perimetry. HRR (Hardy Rand and Rittler) color vision screening was normal in each eye. Slit lamp examination revealed yellow-brown glistening gold deposits in the stroma of each cornea. **(Figure 1).** No discoloration of the skin of her face or elsewhere was noted. The anterior chamber was clear, without cells or flare. Goldmann applanation tonometry was 11 mmHg in each eye. Dilated fundus examination was performed using one drop of 1% tropicamide in each eye. Crystalline lenses of both eyes showed trace nuclear sclerosis. The vitreous humor was clear in each eye. Optic nerves were a healthy pink color, and cup/disc ratios were 0.30/0.30 in the right eye and 0.35/0.35 in the left eye with distinct margins. Maculae were normal without degenerative or pigmentary changes. Retinal blood vessels showed no hypertensive changes. Peripheral retinae were flat with no holes, breaks or tears.

Upon further questioning, the patient reported originally being diagnosed with rheumatoid arthritis in 1985. Treatment with the gold injection Solganol was initiated at that time. After a year of treatment, injections were switched to Myochrysine until therapy was discontinued in 1987 due to pregnancy. A short Myochrysine treatment course of a couple of months was administered after the conclusion of the pregnancy in 1988. The oral gold medication Ridaura was also tried during chrysotherapy but was immediately discontinued due to gastrointestinal intolerance.

In total, the patient had received 1935 mg of gold salt injections. However, the severity of the arthritis decreased drastically during a second pregnancy and never returned to its pre-pregnancy severity. In 1992, plaque-like seborrhea of the scalp developed and the diagnosis was changed to psoriasis with psoriatic arthritis.

Educators Guide

Key concepts

- Recognize clinical findings of ocular chrysiasis
- Differential diagnosis of ocular chrysiasis
- Treatment and management considerations in patients with ocular chrysiasis

Learning objectives

At the conclusion of the case, participants should be able to:

- Know the systemic conditions for which gold salt treatment may be used
- Know the typical cumulative dose of gold salts that may result in ocular chrysiasis
- Describe the signs of chrysiasis
- Understand the physiology behind gold deposition in ocular structures
- Provide proper patient education on management and long-term prognosis of ocular chrysiasis

Discussion questions/points

- What is the definition of chrysiasis vs. ocular chrysiasis?
- Describe the signs and symptoms of ocular chrysiasis
- What conditions have gold salts (chrysotherapy) been used to treat?
- How would you educate patients with chrysiasis about their condition and prognosis?

- Should a patient with ocular chrysiasis discontinue gold salt treatment?
- What is the natural course of ocular chrysiasis?
- Discuss the differential diagnoses of ocular chrysiasis
- How would you manage the ocular symptoms for the patient in the case report?
- What history questions should be asked of patients presenting with anterior segment crystalline deposits?

Learning assessment

- Incorporate the case into clinical or didactic discussion to achieve learning objectives
- Assess clinical skills using application of anterior segment photography and corneal topography
- Use photography and topography to facilitate understanding by identifying normal vs. abnormal findings
- Further assess knowledge by use of student-directed presentations to compare and contrast differential diagnoses

Discussion

Chrysiasis is derived from the Greek word chrysos, meaning “golden flower.”¹ It is due to the deposition of gold salts throughout tissue in the body, most noticeably on the skin.¹ The use of gold salts in medical therapy dates back thousands of years. In the late 19th and early 20th centuries, gold cyanide was used to treat tuberculosis. Physicians at that time believed that rheumatoid arthritis was a form of tuberculosis. Jacques Forestier, a French physician, was the first to find that gold salts improved the condition of patients with rheumatoid arthritis.²⁻⁵ Gold salt administrations were common in the treatment of rheumatoid arthritis until the advent of alternative treatments with better safety profiles, such as methotrexate, in the 1990s. Chrysotherapy (gold salts) has also been used to treat Sjögren’s Syndrome and systemic lupus erythematosus.⁶

Gold salts were primarily given by intramuscular injection or orally. Doses started at 10 mg to determine patients’ ability to tolerate the therapy. Doses were slowly increased to 50 mg at weekly intervals until a total of 2000-3000 mg was given. The patient was reassessed at that time. If inflammation persisted, another course of treatment was started in 6-8 weeks. Patients were monitored closely for signs and symptoms of toxicity, which included itching, mouth ulcers, jaundice and digestive upset. Urinalysis was conducted at every visit to check for protein in the urine, the presence of which indicated kidney damage. If protein was found in a urine sample, gold salt administration was immediately paused until a subsequent urine sample was found to be free of protein. Blood sedimentation rates were performed approximately every six weeks during therapy to track inflammatory signs and treatment progress.^{3,5}

The exact mechanism of action of gold salts is not entirely understood. Prevailing theories suggest that gold ions and their metabolites serve an inhibitory role in inflammation. This inhibition is believed to act on immune cells such as macrophages and T-lymphocytes, immunoglobulins and inflammatory cytokines as well as at other points along the inflammatory cascade. In addition, gold ions may interfere with antigen processing and recognition of T-cell receptors.⁵

Chrysiasis typically begins with a mauve discoloration of the skin around the eyes, which changes to a grayish/slate blue or gray and extends to other sun-exposed areas of the body.^{1,7} Ocular chrysiasis can involve the cornea, conjunctiva and lens. Deposition of gold in the cornea has typically been seen in cumulative doses higher than 1-1.5 grams.^{7,8}

Ocular chrysiasis is a common finding in patients undergoing chrysotherapy. One study found that 62% of chrysotherapy patients developed corneal chrysiasis during treatment.⁸ Other studies have produced estimates that between 45% and 97% of patients receiving a total of 1 gram of gold salts develop corneal chrysiasis.⁹⁻¹¹ Lenticular chrysiasis has also been reported with variability in the frequency of manifestation. Overall, lenticular chrysiasis is believed to be rare. One study found that 36% of gold salt-treated patients displayed lenticular chrysiasis.¹¹ Another suggested 55% of patients develop lenticular chrysiasis.⁹

The underlying mechanism of gold deposition is unknown. Gold is believed to circulate and be deposited by the aqueous humor because it is primarily found in the posterior half of the inferior cornea and often spares the superior and peripheral cornea.^{9,12} Although some investigators have reported that most ocular gold salts deposit in the posterior stroma, a 2010 confocal microscopy study revealed gold deposits throughout all layers of the cornea, with the largest deposits in the anterior stroma. Histopathology and in vivo confocal microscopy showed no associated inflammation.^{7,13} However, two variants of corneal chrysiasis have been described. Most commonly, it presents as asymptomatic deposition of fine brown

or purple granules in the central posterior corneal stroma, sparing the periphery. Other patterns include peripheral deposition with extension toward the central cornea, superficial, and deep axial deposition. These findings are not an indication to stop gold therapy.¹² The second corneal variant is rare but may present with inflammatory signs and symptoms such as marginal interstitial keratitis that may ulcerate, with white subepithelial limbal infiltration and deep, brush-like stromal vascularization. Crescent-shaped marginal ulcers 2-3 mm in length may also be present. This variant is thought to be an idiosyncratic reaction. It may be unilateral or bilateral and is considered an indication to stop gold therapy.¹²

Overall, ocular chrysiasis after systemic gold administration is considered inert.¹⁰ However, Raj et al. reported a case of a patient who received a chemical injury when a gold/amine compound exploded and caused gold particles to embed in the cornea bilaterally. After cataract extraction 40 years later, he developed a localized ulcerative keratitis adjacent to embedded gold in the cornea and recurrent bouts of stromal erosion.¹²

Lenticular chrysiasis appears as fine, dust-like, yellowish glistening deposits in the anterior capsule or in the anterior suture lines. Gold can collect in the conjunctiva as well, forming irregular brown deposits. However, conjunctival changes typically resolve after cessation of therapy.¹⁰ A study published in the *Annals of the Rheumatic Diseases* by Prouse, Kanski and Gumpel explored ocular chrysiasis as a predictor for clinical improvement or systemic toxicity. However, the study found no such association.⁸

In the absence of inflammation, there is no necessary treatment or management for ocular chrysiasis as the deposits typically do not cause decreased visual acuity or other symptoms. UV protection may assist with reducing glare. However, it is necessary to monitor for changes and differentiate the condition from other corneal pathology. Although this condition can be noticed visually, it should not be detrimental to vision.

The key to diagnosis is thorough patient history to identify any autoimmune conditions or history of chrysotherapy. Location of the deposits is likewise important for ruling out other corneal pathologies. Ocular chrysiasis should be considered in any patient who has undergone chrysotherapy if abnormalities within the cornea or lens are noted.

Differential diagnosis

Several differential diagnoses should be considered if corneal deposits are observed. The appearance and location of the deposits will aid correct diagnosis.

Pigment dispersion syndrome is a condition that results from mechanical rubbing of the posterior iris epithelium on the lens zonules due to mid-peripheral bowing of the iris. This rubbing results in shedding of the pigment into the posterior chamber. Following the aqueous currents, this pigment travels into the anterior chamber and is deposited on the corneal endothelium. Pigment deposits form a characteristic vertical line called Krukenberg spindle. In these cases, the anterior chamber is typically deep, and melanin may be floating within the chamber during active pigment dispersion. Anterior chamber angles are open, and the trabecular meshwork is hyperpigmented. Patients with pigment dispersion syndrome may develop elevated intraocular pressure leading to pigmentary glaucoma.¹⁴

Wilson's disease is a degenerative liver condition that causes copper to be deposited in tissues, including the cornea. Copper deposits in the cornea within Descemet's membrane in a peripheral ring, called a Kayser-Fleischer ring. The appearance of this ring can change color based on illumination type. Patients may present with corresponding liver disease, basal ganglia dysfunction and psychiatric disturbances.¹⁴

Bietti's corneoretinal crystalline dystrophy, an autosomal recessive condition primarily affecting those of East Asian ancestry, results in slow, progressive vision loss. Onset of this condition occurs in the third to fourth decade of life. Patients develop crystals in the superficial peripheral cornea as well as in all retinal layers of the posterior fundus. They also develop atrophy in the macular retinal pigment epithelium and choriocapillaris.¹⁴

Conclusion

Ocular chrysiasis is a condition associated only with use of gold salts for treating autoimmune conditions. It is becoming increasingly rare as newer and safer therapies for rheumatoid arthritis are developed. It is important to include ocular chrysiasis as a differential in the presence of crystalline keratopathies whenever gold therapy has been administered. A detailed medical history and thorough ocular examination can assist in arriving at the correct diagnosis.

References

1. Ahmed SV, Sajjan R. Chrysiasis: a gold “curse”! BMJ Case Reports 2009. Available from: <http://casereports.bmj.com/content/2009/bcr.07.2008.0417.full>.
2. Norn S, Permin H, Kruse PR, Kruse E. History of gold-with Danish contribution to tuberculosis and rheumatoid arthritis. Dan Medicinhist Arbog 2011;39:59-80.
3. Crawford JCC. Chrysotherapy in the treatment of rheumatoid arthritis. Ulster Journal of Medicine. 1937 Jan;6(1):29-32, 33-34.
4. Devaux G. From photography to chrysotherapy: Fordos and gelis salt. Revue d'Histoire de la Pharmacie. 1999;47(323):347-54.
5. Eisler R. Chrysotherapy: a synoptic review.” Inflammation Research. 2003 Dec;52(12):487-501.
6. Tierney DW. Ocular chrysiasis. J Am Optom Assoc. 1988 Dec;59(12):960-2.
7. Singh AD, Puri P, Amos RS. Deposition of gold in ocular structures, although known, is rare. A case of ocular chrysiasis in a patient of rheumatoid arthritis on gold treatment is presented. Eye. 2004;18:443-444.
8. Prouse PJ, Kanski JJ, Gumpel JM. Ocular chrysiasis and clinical improvement with chrysotherapy in rheumatoid arthritis. Ann Rheum Dis. 1981 Dec;40(6):564-6.
9. McCormick SA, DiBartolomeo AG, Raju VK, Schwab IR. Ocular chrysiasis. Ophthalmology. 1985 Oct;92(10):1432-5.
10. Bartlett JD, Jaanus SD. Clinical ocular pharmacology fifth Edition. St. Louis: Butterworth-Heinemann, 2008. Pgs. 710, 713.
11. Gottlieb NL, Major JC. Ocular chrysiasis correlated with gold concentrations in the crystalline lens during chrysotherapy. Arthritis Rheum. 1978 Jul-Aug;21(6):704-8.
12. Raj A, Williams GP, Hawksworth NR. Ulcerative keratitis following particulate elemental gold deposition. J Ocul Pharmacol Ther. 2012;28(3):323-325.
13. Paladini I, Menchini U, Mencucci R. Corneal chrysiasis: in vivo confocal microscopy analysis. Eur J Ophthalmol. 2010;20(4):776-779.
14. Kanski JJ, Bowling B. Clinical Ophthalmology: A Systematic Approach 7th Edition. St. Louis, GB: Saunders, 2011. ProQuest ebrary. Web. 22 February 2017. Pgs. 230, 357-359, 660.



Dr. Larson [mlarsonod@gmail.com] is an independent optometrist practicing in Colorado. He is a graduate of the Indiana University School of Optometry, where he also completed a residency in Primary Care and Ocular Disease. His areas of interest include primary care and the treatment and management of infections and uveitis.

Dr. Klemencic is an Associate Professor at the Illinois College of Optometry/Illinois Eye Institute.

Dr. Peabody is an Associate Clinical Professor, Associate Dean of Institutional Advancement, and Director of Continuing Education at the Indiana University School of Optometry.

THANK YOU!

ASCO extends its sincere thanks to the following sponsors of the Ophthalmic Optics Educators Special Interest Group and the Low Vision Educators Special Interest Group!

OPHTHALMIC OPTICS EDUCATORS SIG



Michelle J. Hoff, OD, ABOAC, FNAO, Associate Clinical Professor at the University of California - Berkeley School of Optometry, is an individual contributor to the SIG.

LOW VISION EDUCATORS SIG

Visionaries' Circle (\$5,000 and above)



Bioptic Club (\$2,000 - \$4,999)



Magnifier Club (\$1,000 - \$1,999)



ASCO's SIGs are the vehicles for faculty interchange and the sharing of ideas, resources and experiences. The groups provide forums for professional staff, administrators and faculty with common responsibilities to communicate directly with each other about issues related to common areas of interest and expertise. SIGs encourage interaction, cooperation and the sharing of best practices. They also develop guidance in areas of focus and expertise. These collaborative efforts dramatically advance optometric education.



@ OUR WIT'S END WITH UNPROFESSIONAL STUDENT E-MAILS

Traditionally, out-of-class communication between students and faculty involved meetings during office hours or informal meetings. These meetings have been shown to contribute to a positive student outcome.¹⁻³ Today, e-mail communication between students and faculty is common at all levels of education. It provides students with a convenient and efficient method of interacting with faculty outside of class and can be a means of discussing information they may not feel comfortable discussing face-to-face. However, e-mail communication differs from face-to-face communication because it does not allow the participants to clarify information on-the-spot or to interpret nonverbal cues and feedback. Stephens et al. identified that overly casual e-mails from students to instructors created a less than positive attitude toward the message and significantly impacted student credibility and an instructor's willingness to comply with a simple request for a face-to-face meeting.⁴



Aurora Denial, OD, FAAO

Faculty are Inundated

According to the New York Times, student e-mails that are unprofessional with regard to etiquette, grammar and content are overwhelming faculty.⁵ Attributes of unprofessional e-mails include an inappropriate salutation such as "hey," use of first names, or use of Mr./Miss./Ms. Other contributors to unprofessional e-mails are poor grammar, lack of capitalization, inappropriate abbreviations, lack of subject line information, no signature, grade-begging, negotiating work assignments, or an unprofessional tone. Studies have indicated that grade-begging — asking for a higher grade without a legitimate reason — occurs more frequently in e-mails than in face-to-face meetings.^{6,7}

TABLE 1
E-Mail Guidance for Students

A sampling of tips for professional e-mailing, from various sources, that can be shared with students
E-mail is forever, once it is sent you cannot get it back.
Think about the content. Would you feel comfortable discussing the e-mail content in a face-to-face meeting?
Always use subject lines. This can help a professor identify the importance of the e-mail.
Address professors correctly with proper titles and salutations.
Be polite and concise.
Never send an e-mail while you are angry or upset. This includes being upset about a grade. Wait until you are calm and can compose a professional e-mail.
Don't use texting abbreviations or otherwise inappropriate abbreviations.
Do not write in all capital letters. This can be interpreted as shouting.
Grammar and spelling matter. Use spell-check and review the e-mail again, before sending.

Table 1. [Click to enlarge](#)

Anecdotal reports from faculty in optometric education confirm they are receiving a large amount of unprofessional e-mails. Recently, I received an e-mail from a student that referred to me as "Mrs. Denial" and included "Im having trouble with a topic u covered in class. Can u meet at 11 tomorrow." I've had students use idk (I don't know) in an e-mail to me as well. In another example, a student contacted me with a legitimate concern about a quiz taken with the college's learning management system. I was sympathetic to the concern until I read the last sentence of the e-mail: "if this issue is not resolved I will have to take it to a higher power." I'm not sure if the student would have used the same phrase in a face-to-face meeting, but my level of sympathy towards the student changed immediately.

Generational or Not, Inappropriate E-mail is Unacceptable

Can generational differences account for the unprofessional nature of students' e-mails? Perhaps the issues are related to the types of expectations held by Millennial students, which include a quick response, the right to have a voice, informality, negotiation, and the use of titles as inauthentic.⁸ It's worth asking, too, whether students ever formally learn how to compose an e-mail. One might assume that most students learn informally and from e-mailing peers. Aquilar-Roca et al. studied whether a two-minute training class significantly increased the use of professional e-mails in student-to-faculty correspondence.⁷ The study demonstrated "a significant increase in overall professional quality of student e-mails in the trained class due to more frequent use of proper salutations, appropriate capitalization and a class-specific subject line."⁷ However, no difference was detected in professional content or grade-begging between the trained and untrained group.⁷

Unprofessional e-mails should not be tolerated by faculty. Discussing unprofessional e-mails with students can help to alter the behavior. A plethora of websites offer tips for composing professional e-mails. (**Table 1**) Faculty often include these guidelines in course syllabi. Providing students with some common-sense tips may help to guide them toward more professional e-mailing and maintaining a positive relationship with faculty.

I welcome optometric faculty and administrators to share their experiences and ideas on this important topic.

References

1. Dobransky ND, Frymier AB. Developing teacher-student relationships through out of class communication.

- Communication Quarterly. 2004 May;52(3)211-223.
2. Jaasma MA, Koper RJ. Out-of-class communication between female and male students and faculty: the relationship to student perceptions of instructor immediacy. *Women's Studies in Communication*. 2002 Nov;25(1)119-137.
 3. Martin MM, Myers SA. Students' communication traits and their out-of-class communication with their Instructors. *Communication Research Reports*. 2006 Dec;23(4)283-289.
 4. Stephens K, Houser ML, Cowan RL. R U able to meat me: the impact of students' overly casual e-mail messages to instructors. *Communication Education*. 2009;58(3):303-326.
 5. Glater JD. To: professor@university.edu Subject: why it's all about me. *The New York Times*, Feb. 21, 2006.
 6. Jones S, Johnson-Yale C. Professors online: the Internet's impact on college faculty. *First Monday*. 2005 Sept 5;10(9). Available from: <http://firstmonday.org/ojs/index.php/fm/article/view/1275/1195>.
 7. Aguilar-Roca N, Williams A, Warrior R, O'Dowd D. Two-minute training in class significantly increases the use of professional formatting in student to faculty e-mail correspondence. *International Journal for the Scholarship of Teaching and Learning*. 2009;3(1). Available from: <https://doi.org/10.20429/ijstl.2009.030115>.
 8. Espinoza C. Millennial values and boundaries in the classroom. *New Directions for Teaching & Learning*. 2012;2012(131):29-41. Available from: <https://onlinelibrary.wiley.com/doi/abs/10.1002/tl.20025>.



Dr. Denial [deniala@neco.edu], Editor of *Optometric Education*, is a Professor and Chair of the Department of Primary Care at the New England College of Optometry and a Clinical Instructor at a community health center in Boston.

