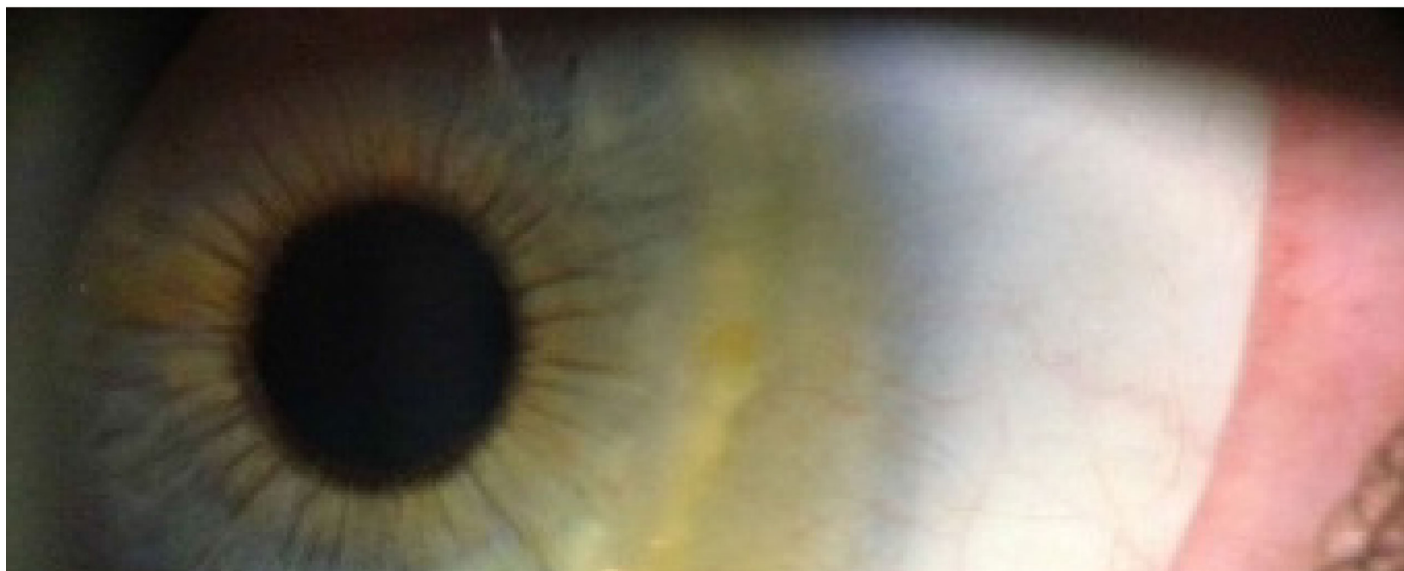


OPTOMETRIC EDUCATION

The Journal of the Association of Schools and Colleges of Optometry

Volume 41, Number 1
Fall 2015



Terrien's Marginal Degeneration:
A Teaching Case Report

Planning Ahead for Corneal Epithelial
Dystrophy: A Teaching Case Report

A Test of a Blended Method for Teaching
Medical Coding

ALSO INSIDE

Editorial: Should We Require Class Attendance?

Educator's Podium: Using Writing Assignments to Improve
Student Engagement and Learning

Invitation to Participate: Call for Papers on the Theme of
International Optometric Education - Global Expansion and
Transformation

Invitation to Participate: Call for Papers on the Theme of
Cultural and Linguistic Competence

ASCO ASSOCIATION of
SCHOOLS and COLLEGES
of OPTOMETRY

Table of contents

A TEST OF A BLENDED METHOD FOR TEACHING MEDICAL CODING	1
PLANNING AHEAD FOR CORNEAL EPITHELIAL DYSTROPHY: A TEACHING CASE REPORT	8
CALL FOR PAPERS FOR UPCOMING DIVERSITY AND CULTURAL COMPETENCE THEME EDITION	16
DON'T MISS IT	17
INDUSTRY NEWS	18
SHOULD WE REQUIRE CLASS ATTENDANCE?	25
USING WRITING ASSIGNMENTS TO IMPROVE STUDENT ENGAGEMENT AND LEARNING	28
TERRIEN'S MARGINAL DEGENERATION: A TEACHING CASE REPORT	31
DR. HOPPE DELIVERS KEYNOTE ADDRESS AT SUMMER INSTITUTE FOR FACULTY DEVELOPMENT	37
DEADLINE EXTENDED FOR UPCOMING INTERNATIONAL OPTOMETRIC EDUCATION THEME EDITION	38

A TEST OF A BLENDED METHOD FOR TEACHING MEDICAL CODING

Abstract

Background: Evaluation and Management (E/M) codes are used by all healthcare providers to bill third-party payers for their services. The purpose of this study is to determine whether providing education about E/M coding to third-year optometry students in a blended teaching format leads to improved coding accuracy.

Methods: Optometry student participants ($N = 53$) had the traditional classroom and clinical education in E/M coding throughout the first 2 years of the curriculum. Students were randomly divided into two groups. One group (the Experimental Group) received education regarding E/M coding in an online format as well as two interactive practice cases. The other group did not. All students were then asked to determine the E/M code on 5 standardized cases. Approximately 8 weeks later, a second set of 4 standardized cases was given to all participants to determine whether knowledge acquired was long-lasting.

Results: By generalized linear mixed models, it was found that students in the Experimental Group were much more likely to indicate the correct E/M code than the students in the Control Group, with an odds ratio of 9.55 (95% confidence level 2.05-72.52; $P = 0.01$). After 7-9 weeks, the treatment effect was still significant, but it was reduced, and the odds ratio was 3.23 (95% confidence interval 1.05-10.68, $P = 0.01$).

Conclusions: A blended format of teaching E/M coding is at least initially effective in improving coding ability. However, without further intervention, the effect decreases over time. Because of this, additional reinforcement of coding is needed, likely in both the didactic curriculum and the clinic.

Key Words: CPT codes, evaluation and management codes, blended teaching

Introduction/Background

According to the American Optometric Association, in 2013 more than half of the gross income in private optometric practices was derived from third-party insurance plans.¹ This revenue could be further subdivided into almost an even split between payments from public plans, such as Medicare and Medicaid, and those from private insurance programs, including managed care and preferred provider networks. As the patient population ages, and with the full implementation of the Affordable Care Act (i.e., "ObamaCare"), the percentage of optometric revenue attributed to third-party plans seems certain to rise. Thus, an important aspect of preparing optometry students to transition successfully from the teaching clinic to private practice is ensuring they are trained to code and bill third-party payers efficiently and accurately.

While we are unaware of any published reports for optometry, studies from other health professions show that documentation and appropriate coding and billing are important skills in clinical practice.²⁻⁵ The Accreditation Council for Graduate Medical Education now lists awareness of and responsiveness to the larger system of health care as 1 of 6 general competencies required for resident development.⁶ In other words, medical residents, like other healthcare providers must be knowledgeable about coding and reimbursement.^{2,7,8,10}

Current Procedural Terminology, or CPT, codes are an elaborate system of individual Evaluation and Management (E/M) codes used by all healthcare providers to bill third-party payers for their services. Determining the correct E/M code to be applied to a specific clinical case from the array of CPT codes requires the clinician to understand complex Medicare rules and to know what must be recorded in a patient's records to justify billing under a particular code. Despite the importance of learning accurate documentation and coding, there currently are no evidence-based accepted standards for teaching these skills in either optometric or medical education programs. Although there is no literature indicating how optometry students are taught coding, informal discussions with optometric educator colleagues indicate that, as in medical residency programs, coding and billing education typically involves a limited number of formal lectures (<4 hours) followed by the informal provision of additional information during patient care encounters.

While it would seem logical to teach E/M coding as part of everyday clinical teaching, previous studies suggest that this can be difficult. Teaching coding requires that time be allocated for this task. This inevitably erodes the time allotted for patient care, which has the potential to reduce the number of patient encounters. This is supported by previous studies showing that teaching E/M coding during patient care has a negative impact on student evaluations of clinical teaching and on the delivery of patient care.^{9,12-14} Finally, while it might be suggested that acquiring the skill of coding and billing

accurately can be put off until patient care has been mastered, evidence shows substantial error rates in billing are found even in highly experienced clinicians, including clinical faculty members and community doctors.^{10,11,15,16}

As the cost for health care rises, third-party payers are experiencing increasing political and financial scrutiny to control their costs by insisting that caregivers bill accurately and have the appropriate supporting documentation. When billing errors — either over- or under-billing — are discovered, they can have significant financial repercussions. Each type of mistake is considered Medicare fraud and can result in costly audits and legal consequences.¹⁷ Coding's importance to financial success in private practice, the heightened concerns of third-party payers about eyecare costs and coding errors, and the financial losses that can result from these errors, all provide a strong rationale for strengthening the teaching of coding in professional optometry programs. However, given the curricular time demands of professional training, it is important to identify the most effective methods for teaching coding.

The hypothesis is that utilization of a blended format of teaching (where at least part of the delivery of content and instruction is via computer-mediated activities in addition to the traditional teaching) will significantly improve the accuracy with which optometry students code patient cases. The purpose of this study was to determine whether providing education about coding to third-year optometry student interns in a blended teaching format leads to improved coding accuracy for a set of standardized cases when compared to the traditional method. (The traditional method has typically involved roughly 2-3 hours of formal lecture combined with informal discussion at the conclusion of patient care.) Longevity of acquired knowledge was assessed approximately 8 weeks after the initial blended instruction, by asking subjects in this project to code a second set of standardized cases.

Methods

This study was conducted with approval from the Institutional Review Board Committee of the University of California – Berkeley (protocol 2013-07-5502). The design of the study began with the creation of 10 “standardized” patient cases that were subsequently used to assess the ability of students to assign E/M procedure codes properly. After the authors drafted these cases, they were reviewed by clinical faculty members to assess their completeness and their authenticity in representing actual patients. The draft cases were revised after this initial review and then pilot-tested on a second group of faculty members. After a final set of revisions, all 10 cases were sent to 3 expert external reviewers, who were asked to determine their E/M procedure codes independently. These reviewers, who donated their time and effort to the study, were nationally recognized optometric CPT coders, each of whom has more than 15 years of experience in medical coding. All have lectured and published extensively on medical coding for optometrists. In evaluating these 10 cases, the experts disagreed on the correct E/M procedure codes that should be assigned to 4 of them. In 3 of these, 2 out of the 3 experts provided the same code, which was subsequently used as the correct code for the purposes of the study. The fourth case (with a diagnosis of trichiasis) resulted in a three-way split among the experts and, as a result, it was eliminated from the study.

The study utilized third-year students at the University of California – Berkeley School of Optometry who had been exposed to the traditional curriculum. They had received previous instruction on coding delivered in the traditional format: approximately 3 hours of classroom lecture in a second-year pre-clinic course, and informal case-based instruction during a minority of approximately 50 primary care patient care encounters they experienced as clinical interns during summer semester following the second year and the initial part of the fall semester of the third year. In addition, at the beginning of the fall semester of the third year, all students received a one-page E/M coding flow-sheet, which was designed to help them determine the level of E/M code based on the standard Medicare rules. The sheet explained how to assign a code by first determining the level of the 3 major coding components (history, physical examination and medical decision-making), and then provided a guide to choosing the level of procedure code that should be used to bill a particular case.

To begin the study, all students completed a survey that utilized a Likert scale to indicate:

1. whether the students understood what an E/M code is
2. the level of confidence they had in determining the E/M code correctly
3. whether they believed knowledge of coding was important to their careers
4. the total extent of their prior education on E/M coding (within and outside of the optometry curriculum)
5. whether they believed their previous education was adequate to prepare them for a future job
6. the mode of practice to which they aspired after graduation.

After all students had answered the questions, they were randomly assigned to either the Control (N = 30) or Experimental Group (N = 29). Those in the Experimental Group were introduced to evaluation and management (medical) coding via a 1-hour online program that incorporated streaming video and a concurrent PowerPoint presentation. During this program, students were introduced to the different components of the E/M coding flow-sheet and then presented with 2 different teaching cases (diabetic retinopathy and dry eye). In both cases, the flow-sheet was used to guide students through the thought process involved in determining the E/M code. To gain more hands-on experience in E/M coding, the Experimental Group was then assigned to participate in a 15-minute, interactive, computer training program, where they were presented with sample written cases. One of these was a follow-up evaluation of a dry eye case that had been introduced earlier, during the 1-hour online program. The second was the evaluation and management of a patient with glaucoma. In this interactive exercise, the students were presented with a patient history, findings and assessment, and plan for each case. The students were then tasked with determining the E/M code. Because the final procedure code is based on the level of the patient history, physical examination and medical decision-making, students completed multiple-choice questions for each of these 3 components, selecting the answer they believed gave the appropriate coding level for each component. Upon choosing a level for a component, students were given immediate feedback. For example, if a question regarding a component level was answered incorrectly, they were presented with a message that indicated why the answer chosen was incorrect and referred to the E/M flow-sheet for additional guidance. Students were allowed to re-answer the question until the correct answer was selected. Once the question was answered correctly, they were able to proceed to the next component. The final multiple-choice question required students to select the correct overall E/M procedure code for the case. Time spent viewing the instructional video and performance on the multiple-choice questions during the interactive program were tracked to ensure students completed this component of the study before progressing to the next.

After the Experimental Group watched the video and practiced the interactive cases, the students in both the Experiment and Control groups were to assign a procedure code to each of the first 5 standardized cases. These cases were chosen to simulate typical patients encountered in an optometric setting that utilizes medical coding: glaucoma suspect, allergic conjunctivitis, cataracts, new onset of floaters (posterior vitreal detachment) and blepharitis. Students in both groups were allowed to use any resources they wished (other than consulting each other or faculty), including books, guides, the internet or the flow-sheet given to them at the beginning of the study, to help them determine the correct coding. This initial exercise was designed to establish whether exposure to the interactive training regimen described above resulted in members of the Experimental Group coding cases more correctly than members of the Control Group.

The second phase of the study was designed to assess the extent to which the knowledge the Experimental Group gained from the interactive online training was long-lasting. For this phase, 7-9 weeks after coding the first set of 5 standardized cases, students in both the Experimental and Control groups reviewed and provided E/M procedure codes for the remaining 4 standardized cases. These cases included follow-up for glaucoma, flap retinal tear, diabetic eye evaluation and dry age-related macular degeneration. All 4 cases were labeled as new or established, and the 5 possible CPT codes were provided as choices for selection. For example, codes 99201-99205 would be the possible choices in the case of new patients. Once again, students were allowed to consult the resources listed above to assist them in coding.

The difference in determining the correct E/M code between the Control and Experimental groups was tested by a Fisher exact test. A generalized linear model was then employed to quantitatively assess whether the blended learning treatment had a significant effect on students in the Experimental Group. The analysis utilized an "odds ratio" to allow comparison of the performance of students in the Experimental Group to those in the Control Group.¹⁸ An odds ratio is a measure of association between a treatment (in this case exposure to blending learning) and an outcome (accuracy of E/M coding). The odds ratio represents the odds that an outcome will occur given a particular treatment (Experimental Group) compared to the odds of the outcome occurring in the absence of that treatment (Control Group).

Results

Sixty-two third-year optometry students enrolled in a fall semester course on advanced clinical procedures were invited to participate in the study. Of those 62 students, 59 volunteered and 3 declined. During the testing, 6 students did not indicate an answer for either all 5 cases in the first survey or all 4 cases in the second survey. Because of this, their results were removed from the data analysis, which left 53 participants.

TABLE 1
Initial Responses to Professional Survey on Knowledge, Confidence, Education and Employer Expectance (n=53)

Responses	Control	First Survey Experiment	P value	Control	Second Survey Experiment	P value
Question: I understand what an E/M code is.						
Agree	13	18	0.41	17	36	0.84
Uncertain	8	13		4	0	
Disagree	8	4		5	3	
Question: I feel confident in my ability to determine the appropriate E/M code for care.						
Agree	4	1	0.39	7	13	0.11
Uncertain	8	12		12	12	
Disagree	14	14		7	2	
Question: Knowledge of coding will be important in my career.						
Agree	28	27	0.49	26	26	1.88
Uncertain	8	8		0	1	
Disagree	1	8		0	0	
Question: I received education regarding E/M coding based upon medical documentation.						
Agree	7	8	0.65	11	23	0.894
Uncertain	11	8		9	3	
Disagree	8	8		4	1	
Question: The education I received in E/M coding is adequate to prepare me for a future job.						
Agree	1	1	0.96	7	12	0.83
Uncertain	8	8		5	11	
Disagree	18	18		13	4	
Total number of hours of education:						
0-2 (including 2)	8	8	0.65	2	3	0.78
3-9 (including 9)	21	18		22	30	
10	8	8		2	4	
Question: Within 5 years, my goal is to be working in each year first choice:						
WHD, hospital and medical health services	3	3	1.00	4	5	0.98
Sole or group OED private practice	21	22		22	21	
OED private practice	1	1		0	2	
Other	1	1		0	1	

[Click to enlarge](#)

TABLE 2
Odds Ratio of Treatment Effect on the Outcomes of at Least 50% of Responses Being Correct During the First Survey

Variables	Effect Estimation	95% Confidence Interval	P values
Intercept	0.42	0.00-1.12*10 ³	0.91
Treatment	9.55	2.05-72.52	0.01
Gender	0.52	0.08-3.21	0.86
Age	1.05	0.64-2.04	0.46

[Click to enlarge](#)

Seven to nine weeks after both groups evaluated the initial set of cases, a second set of E/M coding cases was administered to both groups. The second survey found that 59% (16 of 27 participants) of the Experimental Group answered the cases correctly $\geq 50\%$ and the time. In comparison, 31% (8 of 26 participants) of the Control Group answered the same cases correctly $\geq 50\%$ of the time. At this point in the study, the generalized linear mixed model of the data showed the Experimental Group (who watched the instructive video and the interactive program) had an odds ratio of 3.23 (95% confidence interval 1.05-10.68). (**Table 3**) This indicates that, while the training program initially had a positive effect on coding accuracy, after 7-9 weeks this effect was greatly reduced. Both in the initial and second set of coding cases, neither gender nor age was significant in the responses of students to the coding practice.

Discussion

Because some students may have had additional experience either in clinic or from prior work experience that would put them at an advantage for E/M coding, a survey checking knowledge and attitudes regarding E/M coding was done to characterize students' background. The survey questioned students on the number of hours of education received in coding, knowledge, confidence and whether they felt E/M coding was important to their careers.

Through a Chi Square test or Fisher exact test, it was found that at the onset of the study (before the Experimental Group received extra training), there was no difference between the Control and Experimental groups in terms of understanding what an E/M code is, confidence in coding, feeling that coding would be important in their future career, or the amount of education received prior to the study (P values = 0.29-0.41). (**Table 1**) Seven to nine weeks after the first E/M cases were completed, and immediately before the second set of E/M cases was given, the initial knowledge and attitudes survey was given again. In this instance, the Experimental Group had been shown the online lecture material and there were significant differences between the two groups in terms of understanding what an E/M code is (P value = 0.04), having received training (P value = 0.004) and feeling that the education received was adequate (P value = 0.03). In terms of the other factors (confidence in coding and recognizing the importance of coding), there were no differences between the Experimental and Control groups.

One to two weeks after the Experimental Group viewed the video, all participants reviewed and then indicated the E/M procedure code for the first set of 5 standardized cases. When the results for all 5 cases were tabulated, it was found that 92% (24 of 26 participants) of the Experimental Group coded the cases correctly $\geq 50\%$ of the time. In comparison, in the Control Group 58% (14 of 24 participants) coded the same cases correctly $\geq 50\%$ of the time. According to the generalized linear mixed model of this data, the Experimental Group (who watched the instructive video and completed the interactive program) had an odds ratio of 9.55 (95% confidence interval 2.05-72.52), indicating the training program had a positive effect on coding accuracy. (**Table 2**)

TABLE 3
Odds Ratio of Treatment Effect on the Outcomes of at Least 50% of Responses Being Correct During the Second Survey

Variables	Effect Estimation	95% Confidence Interval	P values
Intercept	1.23	0.00-8.05*10 ³	0.91
Treatment	3.23	1.05-10.68	0.01
Gender	1.01	0.25-3.97	0.99
Age	0.96	0.68-1.35	0.81

[Click to enlarge](#)

Traditionally, optometric education has focused on teaching clinical care of patients, with very little time being allocated to educating students about the role of proper documentation and determining the correct E/M procedure code. As optometry students enter the workforce, one of the responsibilities they will face is E/M coding. Good E/M coding ability can be critical to success, and poor E/M coding can result in serious legal and financial consequences. The purpose of the study was to evaluate a new technique for teaching E/M coding and then determine whether this technique led to improved accuracy.

Determination of the correct code for standardized cases

The E/M coding system is complex, and coding can be challenging for novice and experienced clinicians alike. In this study we attempted to ensure the correct coding for each standardized case by utilizing 3 optometric coding experts to determine the code. The experts agreed on the E/M code for 6 of the 10 cases. Interestingly, in 4 of the 10 cases there was disagreement, although the chosen E/M codes were typically very close (e.g., one expert chose 99212 while another chose 99213). It seems likely that disagreement over E/M codes arose because there was a certain amount of interpretation about the complexity of the case and/or the prognosis for the condition — both of which can affect the final level of E/M code. In the cases where there was disagreement, the final code was determined by choosing the code that the majority of experts agreed upon. Unfortunately, in one of the cases, there was complete disagreement between the experts and this clinical case was eliminated from the results pool. The lack of consensus between the CPT coding experts in the study was initially troubling; however, other studies have shown that this type of disparity is common. One group¹¹ found agreement among CPT experts to range from 50% to 71%. This lack of consensus among experts is a complicating factor in teaching students to code correctly and a challenge of coding for practitioners who want to be confident about the accuracy of their billing.

Techniques for teaching coding

What is the best way to teach E/M coding? We are aware of 3 previous studies that examined teaching techniques that led to improvements in coding ability. In one, an instrument consisting of a flow-sheet with a concise set of notes for quick reference was used to determine a final code based on the standard Medicare rules for billing levels.¹⁹ The investigators concluded that the flow-sheet was a reliable tool for correctly assessing coding. In a second study,⁷ clinical cases that had been managed by residents were reviewed in a problem-based teaching format and used to learn coding basics, review previous coding assessments and reinforce proper coding by pointing out errors made by the residents. The authors reported that residents demonstrated an increase in accuracy of coding and a decline in under-coding. In a third study,²⁰ subjects were provided with a single, 90-minute session taught by a coding specialist. The session was presented to residents who had been coding, and the results showed that even a single informational session improved coding ability for inexperienced coders. Unfortunately, this study did not show significant improved coding ability in the more senior residents who were also experienced coders. While all of the above studies show an improvement in coding accuracy in novice clinicians, each was limited by a relatively small number of participants (11 to 20), and none provided follow-up to determine whether learned E/M coding concepts were retained over time.

The technique employed to teach coding in this study used 2 approaches: video and a brief interactive program that walked students through an E/M flow-sheet. Results from the study provide evidence that a blended format of teaching does lead to improved coding ability, with the treatment effect being 9.55 (95% confidence level 2.05-72.52; $P = 0.01$) within 2 weeks of watching the video. This initial improvement in coding ability did however decrease to 3.23 (95% confidence interval 1.05-10.68; P value = 0.01) 7-9 weeks after the training session.

Student perceptions regarding prior education and importance of coding

Although this is the first study involving optometry student clinicians, results of the survey are in agreement with previously published reports of other healthcare profession trainees' attitudes towards the importance of coding. Surveys of residents in surgery and emergency and internal medicine show that most believe the amount of training for E/M coding is inadequate, yet the overwhelming majority (~90% or more) feel that coding ability is important.²⁻⁵ The present survey of optometry students shows a similar result: 98% (52 of 53) agreed that coding will be important to their future careers and 71% (37 of 53) agreed that the education they had received regarding coding was not adequate. Studying a 1-hour video and 2 practice cases was enough to make students feel more knowledgeable about what an E/M code was (P value = 0.04) and that they had received adequate education in coding to prepare them for a future job (P value = 0.03). Compared to the Control Group, their confidence in E/M coding also had improved, but this result was not statistically significant (P value = 0.11).

Limitations of the current study

A limitation of this study is that only 7-9 weeks elapsed between when the students were exposed to the training video and cases and when they assessed the second set of cases, which were designed to examine the permanence of their new knowledge. However, even with this short interval, the data reveal a decrease in performance, suggesting that without additional training at regular intervals the significant gains acquired during the initial training may disappear. Future studies should test knowledge at longer intervals (e.g., 6, 12 and 18 months after the initial videos and exercise) to examine the rate at which the skills gained in E/M coding decline to pre-training levels. It seems likely that, while the use of interactive video and hands-on practice may be a good first step for teaching the basics of E/M coding, this new knowledge has to be reinforced in the clinical setting for it to become permanent.

Conclusion

Optometry students believe that learning coding is very important and that the current level of their education in this area is inadequate. A blended format of instruction in coding techniques is effective in improving these important skills in third-year optometry students. An advantage of the blended format is that it can be utilized throughout the optometry curriculum, even when fourth-year optometry students are away from their home institutions on external rotations. Some of the initial beneficial effects of this training early in the third professional year decreased over time. However, in addition to providing initial instruction, online interactive training could be an effective and practical method for reinforcing and consolidating this new knowledge if it was offered at regular intervals during the remainder of the professional curriculum.

Acknowledgements

The research for this paper was supported by a Starter Grant for Educational Research from the Association of Schools and Colleges of Optometry (M. Whiteside) with funding provided by Vistakon, division of Johnson & Johnson Vision Care, Inc., and an NIH Center Core Grant (P30EY003176; Richard Kramer, PI). The authors are very grateful to Drs. Chuck Brownlow, John McGreal and John Rumpakis, who kindly served as CPT coding experts. In addition, materials used in this study were donated by Primary Eyecare Network (PEN).

References

1. American Optometric Association Research & Information Center Executive Summary, Income from Optometry from the 2013 Survey of Optometric Practice March 2015. [cited 2015 Oct 17]. Available from: <http://www.aoa.org/Documents/ric/2014%20Income%20From%20Optometry%20Executive%20Summary%20FINAL%20073015.pdf>.
2. Adiga K, Buss M, Beasley BW. Perceived, actual and desired knowledge regarding Medicare billing and reimbursement: a national needs assessment survey of internal medicine residents. *J Gen Intern Med*. 2006;21(5):466-470.
3. Pines JM, Braithwaite S. Documentation and coding education in emergency medicine residency programs: a national survey of residents and program directors. *Cal J Emerg Med*. 2004;5(1):3-8.
4. Dawson B, Carter K, Brewer K, Lawson L. Chart smart: A need for documentation and billing education among emergency medicine residents? *West J Emerg Med*. 2010;11(2):116-119.
5. Fakhry SM, Robinson L, Hendershot K, et al. Surgical residents' knowledge of documentation and coding for professional services: an opportunity for a focused educational offering. *Am J Surg*. 2007 Aug;194(2):268-9.
6. Moskowitz EJ, Nash DB. Accreditation Council for Graduate Medical Education Competencies: Practice-Based Learning and Systems-Based Practice. *Am J Med Qual*. 2007 Sep-Oct;22(5):351-82.
7. As-Sanie S, Zolnoun D, Wechter ME, et al. Teaching residents coding and documentation: effectiveness of a problem-oriented approach. *Am J Obstet Gynecol*. Nov;193(5):1790-3.
8. Sprtel SJ, Zlabek JA. Does the use of standardized history and physical forms improve billable income and resident physician awareness of billing codes? *South Med J*. 2005; May 98(5):524-7.
9. Brett AS. New guidelines for coding physicians services - a step backward. *N Engl J Med*. 1998 Dec 3;339(23):1705-8.
10. King MS, Sharp L, Lipsky MS. Accuracy of CPT evaluation and management coding by family physicians. *J Am Board Fam Pract*. 2001 May-Jun;14(3):184-192.
11. King MS, Lipsky MS, Sharp L. Expert agreement in current procedural terminology evaluation and management

coding. Arch Intern Med. 2002 Feb 11;162(3):316-20.

12. Kassierer JP, Angell M. Evaluation and management guidelines – fatally flawed. N Engl J Med. 1998 Dec 3;339(23):1697-8.

13. McLean SA. The impact of changes in HCFA documentation requirements on academic emergency medicine: results of a physician survey. Acad Emerg Med. 2001;8(9):880-885.

14. McConville JF, Rubin DT, Humphrey H, Carson SS. Effects of billing and documentation requirements on the quantity and quality of teaching by attending physicians. Academic Medicine. 2001 Nov;76(11):1144-7.

15. Horner RD, Paris JA, Purvis JR, Lawler FH. Accuracy of patient encounter and billing information in ambulatory care. J Fam Pract. 1991 Dec;33(6):593-8.

16. Duszak R, Blackham W, Kusiak G, Majchrzak J. CPT coding by interventional radiologists: a multi-institutional evaluation of accuracy and its economic implications. J Am Coll Radiol. 2004 Oct;1(10):734-740.

17. False Claims Act (31 U.S. Code § 3729) [cited 2015 Oct 17]. Available from:
<http://www.gpo.gov/fdsys/pkg/USCODE-2011-title31/pdf/USCODE-2011-title31-subtitleIII-chap37-subchapIII-sec3729.pdf>.

18. Szumilas M. Explaining odds ratios. J Can Acad Child Adolesc Psychiatry. 2010 Aug;19(3):227-229.

19. Kapa S, Beckman TJ, Cha SS, et al. A reliable billing method for internal medicine resident clinics: financial implications for an academic medical center. J Grad Med Educ. 2010 Jun;2(2):181-7.

20. Benke JR, Lin SY, Ishman SL. Directed educational training improves coding and billing skills for residents. Int J Pediatr Otorhinolaryngol. 2013 Mar;77(3):399-401.



Dr. Whiteside is an Associate Clinical Professor and Chief of Primary Care at the University of California – Berkeley School of Optometry.

Dr. Ge is a Senior Biostatistician at the University of California – Berkeley School of Optometry.

Dr. Fong is on the clinical faculty at the University of California – Berkeley and specializes in ophthalmic optics solutions and the use of electronic health records.

Dr. DiMartino is a Professor of Clinical Optometry at the University of California – Berkeley School of Optometry and has a private practice in Lafayette, Calif.

PLANNING AHEAD FOR CORNEAL EPITHELIAL DYSTROPHY: A TEACHING CASE REPORT

Abstract

Epithelial basement membrane dystrophy (EBMD) is an anterior corneal dystrophy that can be asymptomatic or cause blurred vision, recurrent corneal erosion or both. Management of EBMD ranges from monitoring at annual exams to aggressive treatment. Recent developments allow clinicians to treat EBMD patients with a variety of in-office techniques. This case report discusses the presentation of EBMD and treatment for the various severities of this potentially sight-threatening condition.

Key Words: *epithelial basement membrane dystrophy, recurrent corneal erosion, epithelial debridement, diamond burr polishing, phototherapeutic keratectomy, photorefractive keratectomy, anterior stromal puncture, alcohol delamination*

Background

Epithelial basement membrane dystrophy (EBMD) is the most common corneal dystrophy seen in clinical practice.¹⁻⁶ Its appearance varies, which leads to frequent misdiagnosis, but presentation most often includes dot-like epithelial opacities, whorl-like fingerprint lines and circumscribed gray map-like patterns.⁴ It is for this reason that EBMD is also referred to as a map-dot-fingerprint dystrophy. A consistent feature in all presentations is the formation of microcysts in the corneal epithelium with alterations in the basement membrane. Histology shows thickening of the basement membrane with fibrillary protein deposited between the basement membrane and Bowman's layer. The absence of hemidesmosomes within the basal epithelial cells is responsible for faulty epithelial adhesion to the underlying basement membrane, which results in recurrent corneal erosion (RCE).¹ Management of EBMD focuses on maintaining patient comfort and treating situational RCE. Typical initial onset of EBMD is in the second decade of life. Approximately 10% of patients develop RCE in the third decade, while the remainder do not develop symptoms associated with RCE.^{1,2}

This teaching case report highlights diagnostic tools and appropriate management of the patient with EBMD, both symptomatic and asymptomatic. It is intended for third- and fourth-year optometry students actively involved in clinical patient care. As this condition is the most common corneal dystrophy encountered in clinical practice, a solid knowledge base about the condition and the appropriate steps for management and treatment is essential for the practicing optometrist in any clinical setting. This case can be used as a teaching tool in a didactic setting during anterior segment discussion, and it can be utilized in seminars focused on patient care in the clinical environment. The techniques discussed in this report can aid in familiarizing the new optometrist with methods used for diagnosing and managing patients with anterior segment abnormalities.

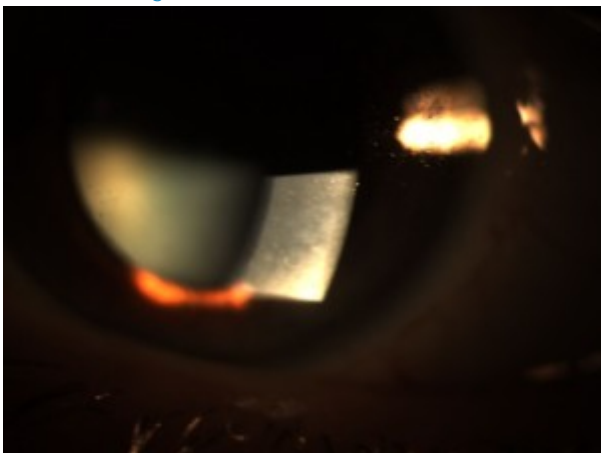
Student Discussion Guide

Case description



Figure 1A and 1B. Diffuse subepithelial map-like geographic patterns consistent with corneal epithelial basement membrane dystrophy.

[Click to enlarge](#)



[Click to enlarge](#)

A 51-year-old Caucasian female nurse practitioner presented to the clinic with complaints of blurred vision in both eyes at distance and near that had worsened over the past year. She reported that using reading glasses purchased over-the-counter provided relief. She also reported that her last eye exam was approximately one year ago. Her ocular history included a long-standing diagnosis of EBMD with no reported symptoms of RCE, and her medical history included genital herpes controlled with oral medication as needed. Family ocular history was positive for age-related macular degeneration (aunt and mother). Family medical history included pancreatic cancer (father), hypertension (mother), high cholesterol (sister) and stroke (maternal grandmother). The patient's social history was positive for occasional alcohol consumption, and she denied tobacco or recreational drug use. Her blood pressure was 123/70 mmHg, right arm sitting at 4:18 p.m. Her height was 66 in., and her weight was 145 lbs. with a BMI of 23.4. Her medications included 2 mg lorazepam (Ativan) as needed for a sleep aid, and artificial tear supplements as needed. She reported medical allergies to celecoxib (Celebrex) and penicillins. She was oriented to time, place and person, and her mood was appropriate.

Entering uncorrected visual acuity was OD 20/30⁻² distance and 20/100 near, and OS 20/30⁺¹ distance and 20/80 near. Pupils were equal, round, reactive to light, with no signs of an afferent pupillary defect. Extraocular motilities exhibited full range of motion OU. Cover test revealed orthophoria at distance and 4-prism-diopter exophoria at near. Confrontation visual fields were full to finger-counting in each eye. Vision was correctable to 20/20 in each eye at distance and at near with manifest refractions of OD +1.00 DS, and OS +1.00-0.25×070 with 1.50 near add. Intraocular pressures measured with Goldmann applanation tonometry were within normal range, 11 mmHg OD and 10 mmHg OS at 4:18 p.m.

Slit lamp biomicroscopy of the anterior segment exam revealed normal adnexa, lids, lashes, puncta and bulbar and palpebral conjunctiva in both eyes. EBMD was confirmed in both eyes by the observation of diffusely scattered subepithelial map-like geographic patterns (**Figure 1A and 1B**). There was no evidence of ocular surface disruption with

fluorescein dye and no sign of previous or current corneal erosion. Anterior chambers were deep and quiet without evidence of cells or flare. Chamber angles were 1:1/2 nasally and temporally using the van Herick method. Pupils were dilated using 1 drop 1% tropicamide and 1 drop 2.5% phenylephrine in each eye. Examination of the posterior segment was unremarkable: clear vitreous OU, clear crystalline lens OU, flat macula OU, attached peripheral retina OU, normal vasculature OU and optic nerve cup-to-disc asymmetry (0.60/0.60 OD and 0.45/0.45 OS), which was noted to be long-standing.

Because the patient's vision was correctable to 20/20 in each eye, recommendations for treatment to control her fluctuating blurry vision were progressive addition lenses for full-time wear and tear supplements as needed. This presentation represents a typical EBMD clinical scenario.

Educational Guidelines

The following includes discussion points and a review of the literature to help facilitate discussion of the case and methods of managing EBMD. Additional information regarding pathophysiology and clinical presentation of EBMD is also included to further educate the clinician about the condition.

Learning objectives

At the conclusion of this case discussion, students should be able to:

- 1) recognize the signs and symptoms of epithelial basement membrane dystrophy
- 2) be familiar with the differential diagnosis associated with anterior corneal dystrophies
- 3) understand the histological process that results in epithelial basement membrane dystrophy
- 4) educate the patient about the condition, associated symptoms and treatment options
- 5) be familiar with in-office management techniques and recognize when surgical techniques are more beneficial for relief of symptoms

Key concepts

- 1) recognition of clinical signs and reported symptoms associated with epithelial basement membrane dystrophy
- 2) the importance of knowing current methods and indications for treatment of epithelial basement membrane dystrophy and its complications

Discussion points

- 1) Knowledge of corneal epithelial dystrophies
 - identify the corneal epithelial dystrophies
 - describe basic clinical signs of each epithelial dystrophy
 - what symptoms are associated with patients with epithelial basement membrane dystrophy?
 - describe the various clinical presentations of epithelial basement membrane dystrophy
 - discuss the structural abnormalities of a cornea affected by epithelial basement membrane dystrophy
 - describe the symptoms associated with recurrent corneal erosion
- 2) Clinical management and treatment
 - discuss the appropriate clinical management of the asymptomatic and symptomatic patient with epithelial basement membrane dystrophy
 - discuss the indications for procedural intervention for the symptomatic patient
 - describe each method of treatment and compare the contraindications and advantages associated with each
 - discuss the methods of treatment that can be performed by the primary care optometrist in a typical clinical setting
- 3) Patient education

- what pertinent information should the optometrist discuss with the patient?
- discuss educating the patient about the methods of treatment
- propose a treatment plan for the symptomatic patient with epithelial basement membrane dystrophy

4) Critical thinking

- in the absence of spectral domain optical coherence tomography, what clinical techniques can be used to aid in the diagnosis of epithelial basement membrane dystrophy?
- discuss a treatment plan for a noncompliant patient with recurrent corneal erosion and extensive epithelial damage and associated visual impairment
- discuss questions a patient may have when first diagnosed with epithelial basement membrane dystrophy

Discussion

Pathophysiology

EBMD is characterized by bilateral and frequently asymmetric subepithelial fingerprint lines, geographic map-like lines and epithelial microcysts. Clinically, there are at least three (or any combination thereof) epithelial configurations that may be observed: 1) groups of tiny, round or comma-shaped, grayish-white superficial epithelial opacities of various sizes in the pupillary zones of one or both eyes; 2) a fingerprint pattern of translucent lines best seen with retroillumination; and 3) a map-like or geographic pattern best seen on oblique illumination.⁷ A thickened basement membrane is one of the most important features of this condition, and it is caused by abnormal epithelium turnover, maturation and production of the basement membrane that leads the basal epithelial cells to extend superficially into the epithelium.⁶ Histology shows thickening of the basement membrane with deposition of fibrillary protein between the basement membrane and Bowman's layer.¹ Histologically, there are also corresponding patterns to the grayish dots, fingerprint pattern and map-like pattern observed with biomicroscopy. The grayish dots represent small cystoid spaces in the epithelium into which other superficial corneal epithelial cells desquamate. The fingerprint pattern is formed by both normally positioned and inverted basal epithelial cells producing abnormally large quantities of basement membrane. The map pattern is produced beneath the epithelium by basal epithelial cells and keratocytes that have migrated from the superficial stroma to elaborate both multilaminar basement membrane and collagenous material.⁷ The absence of hemidesmosomes of the basal epithelial cells can be responsible for the typical RCE.¹ EBMD typically presents during the second decade of life, and RCE tends to present during the third decade. Although presentation is most commonly sporadic, EBMD can present with an autosomal dominant method of inheritance.^{1,2,6,7} It has been considered to be an age-dependent degeneration of the cornea.^{1,6} As was the case with this patient, EBMD generally is asymptomatic. Approximately 10% of patients will develop RCE, and many will manifest visually significant epithelial irregularity resulting in irregular astigmatism.^{1,2,6}

RCE has an unknown pathophysiology, but the underlying etiology is the presence of abnormal corneal epithelial basement membrane adherence to Bowman's layer, whether by abnormal adhesion complexes or a reduplication of the basement membrane itself.⁸ Various hypotheses exist to explain the defective adhesion of the epithelium to the underlying basement membrane: abnormality of the basement membrane, absent or abnormal hemidesmosomes, or increased activity of matrix metalloproteinases (MMP), especially MMP-2 and MMP-9.⁹

While EBMD is the most common corneal dystrophy encountered in clinical practice, it is important to be aware of other dystrophies that can affect the corneal epithelium and other layers of the cornea. This discussion focuses on the anterior corneal dystrophies that target the epithelium, including Meesmann, Lisch and Reis-Bückler's dystrophies. Meesmann dystrophy is a rare, nonprogressive epithelial dystrophy that is observed during the first years of life but generally remains asymptomatic until middle age. Retroillumination reveals tiny intraepithelial cysts of uniform size but variable density throughout the cornea, usually centrally concentrated extending out toward but never reaching the limbus. Treatment for Meesmann dystrophy is usually not required, but a bandage soft contact lens or superficial keratectomy may be beneficial if photophobia is present or if visual acuity is severely affected.^{1,2} Lisch epithelial dystrophy was originally thought to be a variant of Meesmann, but is now believed to be a genetically distinct condition. Gray bands with a whorled configuration are observed during slit lamp examination, and retroillumination shows densely packed microcysts scattered diffusely across the cornea.¹ Reis-Bückler's epithelial dystrophy presents with subepithelial gray reticular or polygonal opacities that are seen primarily in the central cornea. Corneal sensation is decreased, and visual impairment may occur secondary to scarring of Bowman's layer. Patients with Reis-Bückler's epithelial dystrophy suffer from severe episodes of recurrent erosion that require treatment and may ultimately require corneal transplantation, but the dystrophy often recurs in the

graft.^{1,2}

Diagnosis

Diagnosing EBMD can be challenging given its variable appearance. Most diagnoses can be made by careful patient history and slit lamp examination, but there are techniques available for confirming or ruling out a potential case. Patients may describe a constant foreign body sensation, recurrent eye pain upon awakening, decreased vision, monocular diplopia, or shadow images. Frequency and severity of these symptoms can indicate an irregularity of the corneal epithelium. Vigilant slit lamp examination will reveal the typical signs associated with EBMD, and the clinician can observe the diffuse gray map-like patches, white dots or fine refractile fingerprint lines in the corneal epithelium. These findings can be seen best with retroillumination or a broad slit-lamp beam angled from the side.² Performing retroillumination while the patient is dilated may also highlight additional corneal irregularities that may have been too subtle to notice with a broad beam. Negative fluorescein staining defects are also observed in patients with EBMD. The elevations in the ocular surface associated with EBMD result in an immediate tear film break-up over the corresponding area.¹⁰ Positive fluorescein staining is observed when a recurrent corneal erosion is present.

In vivo confocal microscopy has proven to be a helpful tool for examining the morphologic anomalies associated with EBMD, especially when the features are atypical. Corneal confocal microscopy can provide a qualitative morphological description and it can quantify pathology, making it useful for detection and management of pathologic and infectious conditions, detection and management of corneal dystrophies and ectasias, monitoring contact lens-induced changes, and pre- and post-surgical evaluations. The magnification and resolution provided by confocal microscopy allows for an extremely detailed evaluation of the corneal layers when suspected defects are not visible at the slit lamp.¹¹ This technique does require direct contact with the cornea, and it could inadvertently cause more damage to the anterior surface.

The recent development of spectral-domain optical coherence tomography (SDOCT) has dramatically improved imaging not only for the retina but for the cornea as well. SDOCT can provide valuable diagnostic information when a corneal abnormality is suspected.⁶ According to a study conducted by Sanharawi et al. to determine the features of EBMD and the reliability of SDOCT in evaluating it, eyes with the condition demonstrated an irregular, thickened basement membrane with greater hyper-reflectivity when compared with the epithelial basement membrane in a normal control eye. The thickened epithelial basement membrane was sometimes compromised with the appearance of small hyper-reflective elevations associated with a protrusion of the basement membrane into the corneal epithelial layer. These protrusions into the epithelium usually corresponded to the map-like or fingerprint lesions observed during slit lamp examination.⁶ Another striking feature observed in SDOCT scans of patients with EBMD was the presence of hyper-reflective dots, which are thought to be epithelial cysts, beneath the abnormal epithelial basement membrane. In cases with normal basement membranes, the cysts were observed to be more superficial, but in cases where an abnormal basement membrane protrusion was found, the dots were always beneath the abnormal epithelial basement membrane. It is believed that maturing epithelial cells migrating from the deeper layers to the more superficial layers of the epithelium become trapped beneath the abnormal epithelial basement membrane and are prevented from surfacing and discharging from the corneal surface.¹² The cells can then become vacuolated and liquefied to form the intra-epithelial cysts seen on slit lamp exam and SDOCT scans.¹²

Sanharawi and colleagues also noted separation between the corneal epithelial layer and Bowman's layer in patients with a history of RCE. The epithelial detachments corresponded to the map-like lesions. All scans were repeated to determine the reproducibility and repeatability of this technique. Agreement between two corneal specialist observers was perfect for all SDOCT features with the exception of detection of a thickened basement membrane for which agreement was substantial but not perfect. Additionally, SDOCT results were compared to in vivo confocal microscopy evaluations and found to be as reliable and much less invasive in the diagnosis of EBMD.⁶

Treatment

Treatment for EBMD focuses on maintaining patient comfort and treating situational RCE. Approximately 10% of patients will develop RCE, and the remainder of patients will not develop symptoms.¹ Patient education regarding the basic pathophysiology of EBMD and RCE is important for managing the condition and symptoms appropriately. Patients should have a clear understanding of the condition itself, symptoms to be alert for, how EBMD could potentially affect vision, and the different modes of treatment available for both EBMD and situational RCE.

The treatment of RCE can include a cycloplegic drop for pain management, a prophylactic antibiotic solution/ointment 4-6 times daily, and 5% sodium chloride hypertonicity ophthalmic ointment (Muro 128) 4 times daily. After the epithelial defect has healed, artificial tears and bland ointments are recommended along with Muro 128 ointment for at least 3-6 months to

prevent recurrence. In the absence of an ointment, an adjunctive bandage contact lens with the topical cycloplegic/prophylactic antibiotic solution have proven effective in some cases.² A recent development in treatment for RCE is the application of autologous serum eye drops. These drops administered to treat ocular surface disease often produce better results than antibiotics, corticosteroids or tear supplements.¹³ Autologous serum therapy is considered effective for treating ocular surface disease because fibronectin within the autologous serum is thought to promote epithelial migration and anchorage. Additional growth factors and anti-inflammatory mediators provide additional comfort and potential long-term relief for the patient.¹⁴

Medical therapy has also been found effective compared with standard lubrication therapies to reduce symptoms and frequency of RCE. Oral doxycycline and topical corticosteroids, alone or in combination, have proven beneficial for managing RCE by inhibiting extracellular matrix degradation by matrix metalloproteinases.^{8,15} Doxycycline inhibits MMP-9 and also exhibits properties thought to facilitate lipases from bacteria present on lid margins, which ultimately improves meibomian gland dysfunction and leads to stable tear film quality.⁸

If corneal erosions persist, surgical intervention is indicated. The two most commonly employed procedures for management of patients with significant corneal epithelial irregularity associated with EBMD are epithelial debridement with diamond burr polishing of Bowman's layer (ED+DBP) and phototherapeutic keratectomy (PTK).¹⁶ ED with diamond burr polishing of Bowman's layer is especially common for larger defects and for defects along the visual axis.² It is typically performed at the slit lamp with topical anesthesia and placement of an eyelid speculum. A cellulose sponge or blunt spatula is used to debride 7-10 mm of central corneal epithelium, and then a hand-held battery-driven diamond burr is used to gently and uniformly polish Bowman's membrane in the entire area of epithelial defect in a vertical fashion for approximately 10 seconds.⁹ A bandage soft contact lens is placed on the treated eye and removed following resolution of the epithelial defect, and prophylactic antibiotic drops are given 4 times a day for 1 week.⁹ Several studies have indicated that ED+DBP is superior to ED alone because it may be associated with a decreased risk of future development of RCE and recurrent EBMD.¹⁶

Results have been mixed regarding long-term effectiveness of ED alone and ED+DBP. Whereas both procedures produce a statistically significant improvement in best-corrected visual acuity, Itty et al. reviewed results using ED alone and found that approximately one quarter of the treated eyes developed recurrent dystrophic epithelial disruption over an average follow-up period of 33 months.¹⁷ Tzelikis et al. examined the results of ED+DBP and reported that none of the treated eyes demonstrated recurrent epithelial changes over an average follow-up of 22 months.¹⁸ Aldave and coworkers performed a retrospective case series study and concluded that ED+DBP should be considered the procedure of choice as it eliminated RCE in 96% of treated eyes and successfully treated visually significant epithelial irregularity in 100% of treated eyes in this series. Postoperative complications from ED are minor but can include photophobia, foreign body sensation, spontaneous corneal erosion, persistent epithelial irregularity or subepithelial haze. Visually significant recurrences are uncommon, but repeat ED can provide a successful outcome.¹⁷

While PTK is also an effective treatment for the management of both RCE and visually significant epithelial irregularity, ED+DBP is a more convenient treatment option because it can be performed at the slit lamp or in a minor procedure room without the need for access to an excimer laser.^{9,16} PTK and ED are similarly effective. PTK uses an excimer laser to ablate the superficial stroma and simultaneously remove the abnormal epithelium, allowing a potentially more stable epithelium to regenerate.^{2,19} In treating the stroma and Bowman's layer, a new bed for the migrating epithelium cells is formed, the anterior stroma is stimulated to form new anchoring fibrils, and, consequently, an improved hemidesmosome adhesion can be formed.²⁰ In a retrospective case review comparing PTK and ED+DBP, Sridhar et al. found that both groups obtained symptomatic relief; however, patients treated with ED+DBP had a lower incidence of postoperative haze and a lower recurrence rate.²¹

While ED+DBP and PTK are the most common procedures employed to treat EBMD and RCE, additional treatment options include surface ablation, anterior stromal puncture (ASP), and alcohol delamination of epithelium. For the visually symptomatic patient with EBMD, photorefractive keratectomy (PRK) is the procedure of choice to treat refractive error, while PTK may be performed to treat RCE or irregular astigmatism.¹⁹ PRK may have an additional therapeutic effect due to the removal of abnormal epithelium. PRK was identified as a safer alternative for the correction of refractive error when compared to laser-assisted in situ keratomileusis (LASIK) because the faulty attachments between the epithelial basement membrane and Bowman's layer make for an unstable corneal surface that is susceptible to sloughing during LASIK. For this reason, LASIK is contraindicated in patients with EBMD because they are predisposed to epithelial ingrowth, flap melting, flap distortion and exacerbation of symptoms.²¹ PRK in combination with PTK is a safe and reliable treatment for the correction of refractive error and alleviation of symptoms associated with EBMD.²¹

ASP can be performed with a needle or with neodymium-yttrium aluminum garnet (Nd:YAG) laser. ASP is effective for treating RCE because it prevents erosions by inducing fibrosis that causes epithelium to adhere tightly to the underlying basement membrane.⁹ Although it is a recognized treatment for managing RCE, it is generally not a treatment option for visually significant epithelial irregularity because it is associated with a greater risk of permanent corneal scarring.^{2,9,16} ASP is generally used in symptomatic, refractory cases, and most often reserved for traumatic erosions with focal areas of abnormal epithelium outside of the visual axis as the scars it will induce can cause visual disturbances.^{2,9}

Two other in-office treatments, alcohol delamination and topical cocaine, have been proven effective recently for EBMD. During alcohol delamination, the cornea is swabbed with alcohol and thoroughly washed, and the affected epithelium is peeled loose. Afterwards, an unpreserved antibiotic drop is given, and a bandage contact lens is applied until the epithelial defect has resolved.^{22,23} Sayegh et al. treated symptomatic EBMD patients with 4% topical cocaine followed by epithelial debridement and achieved results comparable with studies using ED+DBP and PTK.²⁴ Their results indicated a significant improvement in mean visual acuity, a total recurrence rate of 9%, and a rate of recurrences that needed subsequent intervention of 3%. Topical cocaine acts as an effective topical anesthetic and, because of its adrenergic effect, causes vasoconstriction that retards its own absorption. It enables an approximately 20-minute anesthetic effect. Cocaine likely acts similarly to alcohol by cleaving the anchoring fibrils between Bowman's layer and the corneal epithelial basement membrane, removing the abnormal basement membrane, including any sub-basal cellular debris, and leaving behind a smooth surface that enables a firmer adhesion of new epithelial cells.^{23,24}

Conclusion

This teaching case report describes the management of symptomatic and asymptomatic EBMD. Diagnosis based on an attentive case history and astute slit lamp examination is critical for appropriate treatment. Fortunately, there are several methods of treatment for the complication of RCE in patients who are burdened with EBMD. It is important to remember that while only 10% of patients with EBMD will present with clinical RCE complaints, this population of patients can have morphologic characteristics that can induce significant visual impairment. It is essential for the primary eyecare provider to understand the etiology of EBMD and the various management options available in order to provide the most appropriate treatment.

Acknowledgements

I extend my special thanks to Janene Sims, OD, PhD, FAAO, and Elizabeth Steele, OD, FAAO, for offering their time and professional critiques through review of this case report. I also wish to express great appreciation to Caroline Pate, OD, FAAO, for her constant motivation, encouragement and support throughout my residency.

References

1. Kanski J, Bowling B. Clinical ophthalmology: a systematic approach. 7th ed. China: Elsevier Limited; 2011.
2. Ehlers J, Shah C. The Wills Eye Manual: office and emergency room diagnosis and treatment of eye disease. 5th ed. Philadelphia, PA: Lippincott Williams and Wilkins; 2008.
3. Webvision: The Organization of the Retina and Visual System; Map-Dot Fingerprint Dystrophy [Internet]. Webvision; c2015 [cited 2015 April 4]. Available from: <http://webvision.med.utah.edu/2012/04/map-dot-fingerprint-dystrophy/>.
4. Veire E. IC3D: Classifying Corneal Dystrophies [Internet]. Review of Cornea and Contact Lens; c2010 [cited 2015 April 4]. Available from: <http://www.reviewofcontactlenses.com/content/d/disease/c/21310>.
5. Hereditary Ocular Disease: Corneal Dystrophy, EBMD [Internet]. The University of Arizona: Arizona Board of Regents; c2015 [cited 2015 April 4]. Available from: <http://disorders.eyes.arizona.edu/category/alternate-names/ebmd>.
6. Sanharawi ME, Sandali O, Basli E, et al. Fourier-domain optical coherence tomography imaging in corneal epithelial basement membrane dystrophy: a structural analysis. Am J Ophthalmol. 2015;159(4):755-763.
7. Yanoff M, Fine BS. Ocular pathology. 5th ed. St. Louis, MO: Mosby, Inc.; 2002.
8. Mark E, Hammersmith KM. Review of diagnosis and management of recurrent erosion syndrome. Current Opinion in Ophthalmology. 2009;20(4):287-291.
9. Suri K, Kosker M, Duman F, et al. Demographic patterns and treatment outcomes of patients with recurrent corneal

erosions related to trauma and epithelial and Bowman layer disorders. *Am J Ophthalmol.* 2013;156(6):1082-1087.

10. Ramsey AC. Vital Stains: What You Really Need to Know [Internet]. *Review of Cornea & Contact Lenses*; c2011 [cited 2015 September 24]. Available from: http://www.reviewofcontactlenses.com/content/d/irregular_cornea/c/27820/.
11. Tavakoli M, Hossain P, Malik RA. Clinical applications of corneal confocal microscopy. *Clin Ophthalmol.* 2008; 2(2):435-445.
12. Waring GO III, Rodrigues MM, Laibson PR. Corneal dystrophies. I. dystrophies of the epithelium, Bowman's layer, and stroma. *Surv Ophthalmol.* 1978;23(2):71-122.
13. Azari AA, Rapuano CJ. Autologous serum eye drops for the treatment of ocular surface disease. *Eye & Contact Lens: Science & Clinical Practice.* 2015;41(3):133-140.
14. Kronemyer B. Autologous serum drops relieve dry eye over long term [Internet]. *Ocular Surgery News: Cornea/External Disease*; c2015 [cited 2015 April 4]. Available from: <http://www.healio.com/ophthalmology/cornea-external-disease/news/print/ocular-surgery-news/%7B21800779-6871-4a21-9f16-bcd1297c64af%7D/autologous-serum-drops-relieve-dry-eye-over-long-term>.
15. Mencucci R, Favuzza E. Management of recurrent corneal erosion: are we getting better? *Br J Ophthalmol.* 2014;98:150-151.
16. Aldave AJ, Kamal KM, Vo RC, Fei Y. Epithelial debridement and Bowman's layer polishing for visually significant epithelial irregularity and recurrent corneal erosions. *Cornea Clinical Science.* 2009;28(10):1085-1090.
17. Itty S, Hamilton SS, Baratz KH, Diehl NN, Maguire LJ. Outcomes of epithelial debridement for anterior basement membrane dystrophy. *Am J Ophthalmol.* 2007;144(2):217-221.
18. Tzelikis PF, Rapuano CJ, Hammersmith KM, Laibson PR, Cohen EJ. Diamond burr treatment of poor vision from anterior basement membrane dystrophy. *Am J Ophthalmol.* 2005;140(2):308-310.
19. Woreta FA, Davis GW, Bower KS. LASIK and surface ablation in corneal dystrophies. *Surv Ophthalmol.* 2015;60(2):115-122.
20. Dedes W, Faes L, Schipper I, Bachmann LM, Thiel MA. Phototherapeutic keratectomy (PTK) for treatment of recurrent corneal erosion: correlation between etiology and prognosis – prospective longitudinal study. *Graefes Arch Clin Exp Ophthalmol.* 2015;253(10):1745-9.
21. Sridhar MS, Rapuano CJ, Cosar CB, Cohen EJ, Laibson PR. Phototherapeutic keratectomy versus diamond burr polishing of Bowman's membrane in the treatment of recurrent corneal erosions associated with anterior basement membrane dystrophy. *J Ophthalmol.* 2002;109(4):674-679.
22. Chan E, Jhanji V, Constantinou M, et al. A randomised controlled trial of alcohol delamination and phototherapeutic keratectomy for the treatment of recurrent corneal erosion syndrome. *Br J Ophthalmol.* 2014;98(2):166-71.
23. Dua HS, Lagnado R, Raj D, et al. Alcohol delamination of the corneal epithelium: an alternative in the management of recurrent corneal erosions. *J Ophthalmol.* 2006;113(3):404-411.
24. Sayegh RR, Kouyoumjian PB, Vedula GG, et al. Cocaine-assisted epithelial debridement for the treatment of anterior basement membrane dystrophy. *Cornea.* 2013;32(6):889-892.



Dr. Chinn is a Clinic Faculty Instructor at the University of the Incarnate Word Rosenberg School of Optometry.

CALL FOR PAPERS FOR UPCOMING DIVERSITY AND CULTURAL COMPETENCE THEME EDITION

Optometric Education announces that a future edition of the journal will focus on the theme of Diversity and Cultural and Linguistic Competence. The edition will focus on the diversity of our students, faculty and profession and all aspects of cultural and linguistic competence, including professional, organizational and individual responsibility.

The deadline to submit articles for this theme edition is Dec. 31, 2016. For additional information, contact [Gary Chu, OD](#), or journal Editor [Aurora Denial, OD, FAAO](#).



DON'T MISS IT

Stay tuned to your Inbox for the announcement that the Winter 2015 issue of *Eye on Education* — the online newsletter from the Association of Schools and Colleges of Optometry (ASCO) — is available.

The issue will include a report on “Charting Your Career in Academic Optometry and Research: A Session for Optometry and Graduate Students,” a workshop co-created by ASCO’s Academic Affairs Committee and the American Academy of Optometry. The event brought together highly accomplished clinician/scientists from academia and industry to discuss their experiences and share suggestions for success.

For more information about the session, contact ASCO’s Manager of Professional Affairs [Carol Brubaker](#).

Also: Visit [ASCO’s website](#) to view “Career Opportunities for ODs in Academia: Teaching & Research Needs,” a PowerPoint module that explores the need for increasing the faculty ranks at optometric institutions.



INDUSTRY NEWS



Company Makes “Change the World” List



Fortune magazine has named Essilor to its first-ever “[Change the World](#)” list. In including the company on the list of 51 companies it sees as making “genuine efforts to change the world for the better,” Fortune notes the progress Essilor is making in addressing the issue of visual health as part of its core business strategy. It also cites Essilor’s business division, “2.5 New Vision Generation,” which pioneers profitable business models in emerging countries across Asia, Latin America and Africa in order to bring good vision to people in need.

Visit [Essilor’s website](#) for more information about the company and its products.

Fourth-Year Students Win Scholarship Competition



VSP Global and the American Optometric Foundation (AOF), an affiliate of the American Academy of Optometry (AAO), are distributing more than \$165,000 among top-performing fourth-year optometry students who were winners in the 2015 Practice Excellence Scholarship program.

The winners are: Eva Patel, Brianne Scanlon (Illinois College of Optometry); Michelle Brown, Christina Welling (Indiana University School of Optometry); Alyssa Ng, Nicholai Perez (Inter American University of Puerto, School of Optometry); Gloria L. Wu, Prathik M. Philip (MCPHS University School of Optometry); Elyse Kleifgen, Michael DeWit (Michigan College of Optometry at Ferris State University); Darren Phillips, Julie McCutcheon (Midwestern University Arizona College of Optometry); Danielle Goldberg, Kathryn A. Hannis (New England College of Optometry); Kevin Tomasu, Ashley Zinser (Northeastern State University Oklahoma College of Optometry); Shelly Lomax, Sophie Robinson (Nova Southeastern University College of Optometry); Janet Harawa, Whitney Territo (The Ohio State University College of Optometry); Kathryn Dailey, Brooke Harkness (Pacific University College of Optometry); Janelle Engel, Nicole Rist (Salus University Pennsylvania College of Optometry); Dmitriy S. Zike, Desirae Brinkley (University of the Incarnate Word Rosenberg School of Optometry); Patty Durongwong, Bitu Asghari (Southern California College of Optometry at Marshall B. Ketchum University); Feyisayo Aworunse, Dahlia Haddad (Southern College of Optometry); Samantha Rao, Tracy Borst (State University of New York College of Optometry); Kayla Egner, Heather Cain (University of Alabama at Birmingham School of Optometry); Catherine Huang, Alise Gentry (University of California – Berkeley, School of Optometry); Leanne Roach, Roberto Saenz (University of Houston College of Optometry); Shannon Niere, Jamie Weiser (University of Missouri at St. Louis College of Optometry); Audrey Daoust, Carolyn Perugino (University of Montreal School of Optometry); Morgan Welburn, Wylie Tan (University of Waterloo School of Optometry & Vision Science); and Clarissa Prieto-Ayala, Kaitlin Hash (Western University of Health Sciences College of Optometry).

The scholarships are funded through VSP Global's [Eyes of Hope Global Charitable Fund](#) in collaboration with [FYi Doctors](#) in Canada and are administered through the AOF. Criteria for selecting the scholarship recipients included the student's commitment to enter the independent practice of optometry and clinical and academic performance. In addition to the scholarship funds, this year's winners received travel grants that enabled them to attend the AAO annual meeting in New Orleans.

Student Scholarship Competition Returns



Project Foresight, the Walmart and Sam's Club Health & Wellness optometry scholarship competition, has returned for the 2015-2016 academic year. The national business plan competition highlights the vision of Walmart & Sam's Club Health and Wellness to provide quality, affordable, accessible health care for everyone. Students create their own two-member teams to compete for a \$1,500 team scholarship in their region and the chance to travel to the 2016 American Optometric Association meeting in Boston to compete for the grand prize (first place – \$15,000 team scholarship; second place – \$5,000 team scholarship).

Teams are asked to design an optometric practice that impacts their community. The practice must demonstrate how it will promote the profession of optometry as well as respect for the individual, service to customers, excellence and integrity. Project Foresight is open to students at all Association of Schools and Colleges of Optometry (ASCO) member institutions who are enrolled in their first, second or third year of school during the 2015-2016 academic year. Detailed information about the competition is being sent to each ASCO member school and college of optometry.

Device Streamlines Slit Lamp Imaging



At this year's Vision Expo West meeting, Marco unveiled its Ion Imaging System, an all-in-one anterior segment imaging device that combines an intra-optics beam-splitter/camera adapter with the computing and imaging power of the latest Apple technology to create a highly sophisticated "mainstream" imaging system that emphasizes image quality, simplicity and efficiency. The Ion combines all of the components (digital camera, adapter, computer, monitor, multiple cables, keyboard, mouse, etc.) of the traditional photo slit lamp, into one streamlined device.

Marco says the Ion enables eye doctors to "capture, integrate and educate" with every diagnosis. It includes an app dedicated to anterior segment imaging that consists of patient demographics, pre-set photography modes for maximizing various lighting techniques for video or still images, and auto storage to the Cloud or to a local network for EMR or for PACS integration. [Find more information online.](#)


Gel Drops a New Option for Dry Eye Sufferers



[Refresh Optive Gel Drops](#), a new aqueous gel for patients who need or desire a more viscous artificial tear to relieve dry eye symptoms, are now available from Allergan. Gel Drops are designed to bind to the surface of the eye to provide long-lasting relief from dry eye discomfort, day or night. According to Allergan, in a multicenter, double-masked, randomized study, dry eye patients using Refresh Optive Gel Drops showed a statistically significant reduction in symptoms at day 30.

Also: Partnering with the U.S. First Responders Association to launch the Refresh America campaign, Allergan is helping the nation's first responders, who often work in conditions that expose them to heat, smoke, wind and dust, to alleviate dry eye symptoms and perform at their best. Until July 31, 2016, every purchase of a specially-marked package in the company's Refresh Optive product line will lead to donations of Refresh eye drops to select first responder groups nationwide.

OCT Learning Portal Now Available



Optovue has launched Optovue Academy, an online learning portal offering clinical education, technician training and practice development tracks related to spectral domain optical coherence tomography (OCT). The portal includes video PowerPoint presentations, recordings of live presentations, a library of research documents, a forum where learners can comment and a calendar of live events supported or hosted by Optovue Academy.

"Optovue Academy was created to give eyecare professionals the clinical knowledge they need to offer a higher level of medical eye care with OCT," said Larry Alexander, OD, FAAO, Sr. Director of Clinical Education for Optovue. "In addition, this program supports the practice as a whole by providing training for technicians and resources for growing the practice with advanced imaging technology."

Optovue Academy will be updated continually with new video courses, articles and discussion threads. [Click here](#) to learn more or to register for the site.

Study Suggests Usefulness of Ultrawide-Field Angiography



The results of a [recently published study](#) conducted by researchers at Joslin Diabetes Center in Boston indicate that retinal nonperfusion as detected by ultrawide-field fluorescein angiography is associated with predominantly peripheral lesions and the severity of diabetic retinopathy. Investigators reported that eyes with diabetic lesions that were predominantly located in the peripheral retina had a 4.7-fold increased risk of progression to proliferative diabetic retinopathy and a 3.2-fold increased risk of a ≥ 2 -step progression in diabetic retinopathy severity. They noted that the results were statistically significant and independent of baseline retinopathy severity and prior hemoglobin A1C.

According to the senior author of the paper, Lloyd P. Aiello, MD, PhD, "These data re-affirm the importance of evaluating the entire retina when managing diabetic retinopathy and demonstrate the increased risk of retinopathy progression that could be missed if the peripheral retina is not carefully examined. If currently ongoing large multicenter trials confirm these results, then the status of the peripheral retina may need to be included in diabetic retinopathy grading scales to optimally define the risks of retinopathy progression in an individual."

Dr. Hamada Appointed to Professional Affairs Position

Johnson & Johnson

VISION CARE, INC.

Johnson & Johnson Vision Care Inc. (JJVCI) recently appointed Weslie M. Hamada, OD, FAAO, as the Associate Director of Professional Affairs North America. In this role, Dr. Hamada is responsible for strengthening and enhancing partnerships with state and national professional associations as well as helping to support key projects that elevate the profession.

Dr. Hamada, a graduate of Southern California College of Optometry at Marshall B. Ketchum University, joined the Global Astigmatism Platform at JJVCI in 2013, where she was the research clinician responsible for the clinical development of astigmatism products. She is an active member of Johnson & Johnson Women's Leadership Initiative and has more than 11 years of extensive clinical experience. While in private practice, she worked on numerous clinical studies with JJVCI and other eyecare companies.

Dr. Hamada served as the president of the Hawaii Optometric Association from 2009-2011 and is currently a member of the American Optometric Association's Public Affairs Committee. In 2004 and 2010, respectively, she was named Hawaii's Young Optometrist of the Year and Hawaii's Optometrist of the Year. This year, she was named one of Vision Monday's Most Influential Women in Optical.

Professional Strategy Team Expands

BAUSCH + LOMB

See better. Live better.

Bausch + Lomb appointed Brian Rosenblatt, OD, to the position of Director, Professional Strategy. Dr. Rosenblatt joins Jill Saxon, OD, and Todd Love, also Directors of Professional Strategy, in coordinating the company's Eye Care Professional (ECP) outreach efforts across Vision Care. The company says this addition to the Professional Strategy team will help strengthen Vision Care's support of the optometry community through a wide range of initiatives involving ECPs and students across the country.

Also: The FDA has accepted for review a New Drug Application from B+L and Nicox S.A. for latanoprostene bunod ophthalmic solution 0.024% (Vesneo), an intraocular pressure-lowering single-agent eye drop dosed once daily for patients with open angle glaucoma or ocular hypertension. If approved, Vesneo would be the first nitric oxide-donating prostaglandin receptor agonist available for this indication.

Dry Eye Diagnostics in One Report



The JENVIS Dry Eye Report is a new way for eyecare professionals to create a convenient one-page overview of the exam results generated by the Oculus Keratograph 5M, a corneal topographer with a built-in real keratometer and a color camera optimized for external imaging. In addition to the meibography, NIKBUT, tear meniscus height, lipid layer and bulbar redness information from the Keratograph 5M, data collected from other tests, such as tear osmolarity, blink rate and the OSDI Dry Eye Questionnaire can be entered into the report.

The Dry Eye Report, which includes the practice logo, combines screening and consultancy. For the patient, it also provides the doctor's treatment recommendations and easy-to-understand explanations of abbreviations and technical terms. [Click here](#) to see an example of the report.

New Retina Camera is Fully Automated



Topcon has unveiled its new, fully automatic TRC-NW400 Non-Mydriatic Retinal Camera. Using the TRC-NW400, operators do not need to spend time aligning, centering, focusing or capturing color retinal images because the unit automatically performs these steps once the camera is positioned in front of the eye. It also automatically travels from one eye to the other when both eyes are being imaged. The instrument can be operated from any angle because it incorporates a rotating touch panel monitor. This feature lets the photographer be in front, behind or at either side of the patient, optimizing space savings.

The TRC-NW400 can also take photographs of the anterior segment. Fully DICOM-compliant, it can be connected to a digital capture system or used as a stand-alone instrument. [Click for more information.](#)

Survey Highlights Need for Vision Awareness and Care among Hispanic Americans



A survey recently commissioned by Transitions Optical Inc. showed that nearly eight out of 10 Hispanic Americans are experiencing vision problems, but only four out of 10 reported visiting an eye doctor within the past year. Top vision-related complaints among Hispanic Americans who responded to the survey included trouble seeing up-close or far away, trouble seeing at night and blurry vision. Eight out of 10 Hispanics also report experiencing visual disturbances as a result of bright light or glare, such as squinting, eyestrain or fatigue and headaches.

The survey, conducted by Wakefield Research among a representative sample of 1,000 American adults, also revealed that half of Hispanic Americans don't know that their ethnicity could put them at an increased risk for several sight-threatening eye conditions, and nearly half incorrectly believe that protecting the eyes from UV rays is only necessary in the spring and summer.

To help raise awareness about the importance of regular eye care for at-risk, diverse populations, Transitions offers a number of education resources through its Transitions Cultural Connections initiative. Several materials, including a "What to Expect: Hispanic Eyes" brochure are available - in English and Spanish - free-of-charge at MyMulticulturalToolkit.com.

Expo Programs for Schools, Students and Alumni



This September at the International Vision Expo & Conference in Las Vegas, attendees were able to take advantage of a new onsite program, Job Link, which was designed to convey information about job searching, resume building, interviewing techniques, and more. Speed interviewing (like speed dating) sessions were held each day for optometry and opticianry students, optometrists and opticians. According to the Vision Council's Professional Relations Manager Kristen Reynolds, a fourth-year optometry student received a job offer onsite.

Another programming first for Vision Expo West in 2015 was the opportunity for optometry and opticianry students to learn side-by-side. The "Choose Your Own Adventure" program enabled them to attend a course that best aligned with their interests and encouraged them to use industry as an additional resource, fostering valuable connections for the future. In addition, nightly networking events allowed students to connect with peers and industry professionals, and five optometry schools took advantage of alumni receptions.

Vision Expo West plans to work closely with the schools and colleges of optometry to identify challenges that prevent students from attending the conference. For information related to school, student or alumni programs at International Vision Expo, [e-mail Reynolds](mailto:Reynolds).

SHOULD WE REQUIRE CLASS ATTENDANCE?



Aurora Denial, OD, FAAO

A few weeks ago, I walked by a large lecture hall and observed approximately 15-20 students in the room. I thought it must have been an elective course that just happened to be scheduled in a lecture hall, but it was actually a core course for second-year students. (Total enrollment in the second-year class is 125 students.) The lecture format represents an efficient way to deliver information, knowledge, concepts and ideas and remains one of the most frequently used methods of delivering optometric education. But discussions with colleagues revealed that absenteeism from lecture is a major concern for educators and administrators. A review of the literature demonstrates that this concern traverses educators in many different healthcare professions. Our concerns may be based on the assumption that poor class attendance will negatively impact academic achievement. However, the evidence linking attendance to academic achievement is inconclusive. McCarey et al. demonstrated that attendance was a significant predictor of performance in nursing students, with absenteeism being associated with poorer grades.¹ However, several studies indicate no relationship between attendance and academic performance.²⁻⁴

Do Formats Other than Live Lecture Leave Something to be Desired?

Alternative teaching methods, such as video-recorded lectures, webcasts, blogs, etc., have provided students with different ways to obtain lecture content. But, is watching a video recording of a lecture the same learning experience as being present and engaged in class? Are students missing an important component of learning by not attending lectures? When students attend a lecture in person, they have the opportunity to ask questions and clarify concepts to help them apply information to relevant clinical scenarios. There is the potential for an exchange of information between classmates, exposure to new perspectives and learning from each another. This of course is based on the assumption that the classroom time is spent on more than just dispensing facts and information. A good lecture should foster an atmosphere that is conducive to student participation and engagement.

Faculty, too, can benefit from the live lecture format because immediate feedback from students can allow them to assess the effectiveness and understandability of their lectures. Several colleagues have indicated that looking at a student's confused expression gives them the opportunity to immediately clarify a concept, give an example or change teaching strategies. Consider also that a classroom of students, who are all together in one room learning their chosen profession, may be a very different learning experience than sitting alone at home watching a video. Does a sense of belonging to a profession and collegiality occur when students attend and participate in class? Are we changing the learning environment? Studies have associated student absenteeism with a negative impact in the classroom community by creating a sluggish environment.⁵⁻⁷

I hypothesize that most students would not favor a policy that requires attendance at all classes. They may argue that adult learners should be responsible for deciding how and when to acquire the needed information, that not all classes have equally important content, or that a specific class isn't given at a time that is conducive to their schedule. Additionally, students may argue that if a class is perceived as valuable, they will attend. This of course is based on the assumption that students are in a position to accurately assess the worth of a course in relationship to their future profession. If my hypothesis is correct, could an attendance requirement negatively impact the admissions process, student retention or participation in future alumni activities?

The Harvard Medical School Approach

It is obvious that being physically present in a classroom does not ever guarantee learning. Therefore, should our expectations for learning include not only being physically present but also cognitively engaged? Engagement refers to the "positive energy invested in one's own learning, evidenced by meaningful processing, attention to what is happening in the moment and involvement in learning activities."⁸ Harvard Medical School requires attendance and active engagement in all components of the curriculum, as stated in the student handbook:⁹

"Students pursuing the MD degree at Harvard Medical School (HMS) are physicians in training who must meet standards of professional conduct and responsibility to develop into effective physicians. As a professional school, HMS requires attendance and active participation in all components of the curriculum, as defined by course and clerkship directors. Active participation in the School's course and clerkship activities indicates the student's understanding and mastery of professional responsibilities. The granting of the MD degree attests to the fact that the student has demonstrated a commitment to his/her professional responsibilities through participation in all aspects of the curriculum as defined by the faculty. ... The Pathways MD curriculum is designed to promote active engagement of each student in all components of the curriculum with the following goals for students: to develop a sense of professionalism, to promote collegiality, to engage students in teaching one another, and to give students experience working in teams where different backgrounds and expertise are represented. Meeting these goals requires each student to be present and actively engaged; consequently, attendance is required at all sessions of each course. ... Attendance at and participation in learning activities in all four years of the curriculum, whether classroom or clinical, is considered critical for the professional development of the physician. ... The integrated curriculum of the Pathways MD program in the foundational preclerkship phase and in the integrated advanced science/clinical courses post-clerkships is designed to promote an engaging, collegial interchange of ideas among students and faculty in all sessions, including large group formats such as lectures. Students are required to attend all sessions and to participate."

What Message are We Sending Our Students?

With its approach, Harvard is setting a high expectation for its future doctors. It is conveying a message that when students arrive at HMS, they are considered doctors in training who are professionals. As such, they must act in a professional manner, which includes actively engaging in all classes including lecture classes. Additionally, students have a responsibility to their future colleagues and to the faculty to actively participate in all activities including discussions. This message transcends a more superficial learning of content and reflects a deeper understanding of the material along with the development of other elements such as professionalism, collegiality, etc.

What message are we sending our students? I welcome optometric faculty and administrators to share their opinions on this important topic. Should attendance be required?

References

1. McCarey M, Barr T, Rattray J. Predictors of academic performance in a cohort of pre-registration nursing students. *Nurse Educ Today*. 2007;27(4):357-64.
2. Hunter S, Tetley J. Lectures. Why don't students attend? Why do students attend? In proceedings of HERDSA Annual International Conference held in Melbourne, Australia, July 12-15, 1999. Available from <http://www.herdsa.org.au/wp-content/uploads/conference/1999/pdf/Hunter.PDF>.
3. Rodgers JR. Encouraging tutorial attendance at university did not improve performance. *Australian Economic Papers*. 2002;41(3):255-266.
4. Grabe M. Voluntary use of online lecture notes: correlates of note use and note use as an alternative to class attendance. *Computers and Education*. 2005;44(4):409-421.
5. Brauer J. Correspondence : should class attendance be mandatory? *Journal of Economic Perspectives*. Summer 1994;8(3):205-207.
6. White FC. Enhancing class attendance. *NACTA Journal*. December 1992;36(4):13-15.
7. Longhurst RJ. Why aren't they here? Student absenteeism in a further education college. *Journal of Further and Higher Education*. 1999;23(1):61-80.
8. Schreiner LA, Louis MC. The engaged learning index: implications for faculty development. *Journal on Excellence in College Teaching*. 2011;22(1):9.
9. Harvard Medical School. Student Handbook. Boston, Mass. 2015. [cited October 15, 2015]. Available from: <http://hms.harvard.edu/departments/office-registrar/student-handbook/2-academic-information-and-policies/202attendance>.





Dr. Denial, Editor of *Optometric Education*, is a Professor and Chair of the Department of Primary Care at the New England College of Optometry and a Clinical Instructor at a community health center in Boston.



USING WRITING ASSIGNMENTS TO IMPROVE STUDENT ENGAGEMENT AND LEARNING

Active engagement of students can be helpful in enhancing learning and improving critical-thinking skills.¹ Writing is one method of active engagement that has been used in optometric education²⁻⁴ and other applied science disciplines, such as engineering.⁵ Kidder and Todd⁶ observed that "Writing remains the best route we know toward clarity of thought"

I have assigned writing projects in a number of basic science and clinical courses in my 35 years of teaching at Northeastern State University (NSU) and Indiana University (IU). Here, I briefly describe five different writing assignments I have required, some of which are likely unique.

Critical Abstracts

The ability to read and critically evaluate the optometric literature is a valuable skill for our students to possess. In ocular motility and visual optics courses at NSU, I required students to summarize and critically evaluate one or two published papers. This project was similar to one required by Hofstetter.² I asked students to write an abstract of the article, no longer than one single-spaced page. They were asked to briefly summarize the hypothesis, methods, results and conclusions of the study. Then they were to give their evaluation of the methods and conclusions of the paper, note their thoughts on whether there might be any alternative explanations for the results, and give their suggestions for clinical implications of the paper. In some years I gave them a list of articles to pick from; in other years they chose their own articles after doing their own search for articles pertinent to course topics. Topics of ocular motility articles used for the assignment included relation of accommodative facility to symptoms, effect of proximity cues on accommodation, variables affecting fixation disparity curves, dissociated phoria distribution curves, convergence accommodation, effect of training on vergence parameters, innervation to accommodation, vestibulo-ocular reflex, and latent nystagmus.

Letter to a Visual Optics Pioneer

In a few of the years I taught visual optics, a first-year course, I asked the students to imagine they could write a letter to a person from the early 20th century or before who had made important discoveries or did classic studies in the optics of the eye and its application to vision care. They could choose from Airy, Badal, Donders, Fincham, Gullstrand, Helmholtz, Javal, Kepler, Placido, Purkinje, Scheiner, Tscherning, Ware or Young. Once they made their choice, I gave them a packet of information about that individual and his work. The students were asked to write about how that person's theories had been proven, disproven, expanded or modified since they were proposed and how the discoveries had been applied in clinical techniques, instrumentation or methods of diagnosis. The length of the papers was to be between one and a half and four double-spaced pages. Some of these papers were entertaining and inventive and showed the beginnings of an appreciation for how basic science can translate to improvements in clinical care. For example, among the matters discussed in one letter to Thomas Young were his double slit experiment and the fact that laser interferometry has since been used to predict visual acuity after cataract surgery; his experiments on accommodation and that he was correct about many aspects of accommodation; and that the cornea was a greater contributor to astigmatism than Young had thought.⁷

Binocular Vision Case Reports

I have taught courses on analysis of accommodation and vergence disorders at both NSU and IU. Each time, I required some type of written case report. The course as currently structured at IU includes the learning of testing procedures as well as the diagnosis and management of non-strabismic accommodative and vergence disorders. For the case report project, the students were required to work in pairs and perform the tests they learned in the course on each other. In the case report, they submitted their test results and indicated which test findings were within normal ranges and which were not. They were asked to write a brief narrative about their accommodation and vergence diagnosis, especially the steps in their thinking that led them to the diagnosis. Their report also was to include their treatment plan and the rationale behind it. Students were advised that normal was an acceptable diagnosis and that for grading purposes a reasonable rationale was more important than their particular diagnosis.

Refractive History Paper

For several years at IU, I taught a course that included the nature and development of refractive error as a major topic. In that course, I required students to write a paper, two to four double-spaced pages, about their own refractive care as a patient and relate that to the trends, studies and theories discussed in class. They were instructed to explain how they first became aware they had a refractive problem, their symptoms before wearing spectacles, their first experiences with

spectacles, how what they were able to see and do changed with spectacles, etc. They were encouraged to ask their optometrist for records of their own refractive errors. Students with myopia could then compare their own rates of progression to the rates from various studies covered in the course. They could also discuss their family history of refractive error and other hypothesized risk factors. Students who were emmetropic and had little previous optometric care had to be a little more inventive, but could, for example, write about the refractive history of a family member. This course was given before students had entered clinic, and I believe this project made some of the information covered somewhat less abstract, as they related course material to their own experiences.

Report on “Fixing My Gaze”

For three of the years in which I was one of the instructors in the vision therapy course at IU, I required the students to read the book “Fixing My Gaze” by Susan Barry,⁸ a neurobiologist who first experienced stereopsis after undergoing vision therapy in her 40s. In the book, Barry writes about the impact of improved binocular function on visual experience, challenges dogma on critical periods, and discusses the importance of detecting and treating binocular disorders for school performance. I asked students to write answers to specific questions about the book in about one single-spaced page. I changed the questions from year to year. Questions included what about the book they found surprising, what lessons for patient care they learned, why they would or would not recommend the book to others (almost all did recommend it), what they learned from the book that would affect how they would practice optometry in the future, and some ways in which vision therapy improved quality of life and visual performance that were discussed in the book. This was a popular assignment with many students as they found the book enjoyable to read and inspiring. For example, one student wrote that because of reading the book, he had a “new appreciation of our impact as optometrists.”⁹ Several students commented that it was interesting to read about the patient’s perspective.

Comments

Even though optometry students are busy with heavy course loads, I believe their reactions to these writing assignments were in balance positive. Also, the level of thought that was apparent in many papers suggested that students gained more insight than they would have if they had been only studying for tests. I attempted an objective evaluation of one of the assignments in December 2014. In a brief survey, more than 80% of the 64 responding students agreed or strongly agreed that the case report project helped them to correlate different concepts presented in the course and that they learned enough from it to recommend it should be done by students taking the course the next year.

References

1. Bean JC, Weimer M. Engaging Ideas: The Professor’s Guide to Integrating Writing, Critical Thinking, and Active Learning in the Classroom, 2nd ed. San Francisco: Jossey-Bass, 2011.
2. Hofstetter HW. Journal preferences among our beginning students. Optometric Education. 1979;4(4):28-30.
3. Carlson NB, Chu G, Denial A, Lyons S. Using reflective journal writing in optometric clinical education. Optometric Education. 2007;32:43-47.
4. Bartlett JD. Critical Thinking. In: Think Tank. Optometric Education. 2011;36:116-117.
5. Wheeler ED, Balazs GG, McDonald RL. Writing as a teaching and learning tool in engineering courses. Proceedings of the IEEE Frontiers in Education Conference, 1997.
6. Kidder T, Todd R. Good Prose: Art of Nonfiction. New York: Random House, 2013:xviii.
7. Lewis T. Letter to Thomas Young. Assignment for Optometry 3164, Visual System I: Optics, Northeastern State University, 1989.
8. Barry SR. Fixing My Gaze: A Scientist’s Journey into Seeing in Three Dimensions. New York: Basic Books, 2009.
9. Alavanja J. Fixing My Gaze report. Assignment for Optometry V666, Binocular Vision, Indiana University, 2011.



Dr. Goss is a Professor at the Indiana University School of Optometry.



TERRIEN'S MARGINAL DEGENERATION: A TEACHING CASE REPORT

Abstract

Terrien's marginal degeneration (TMD) is a rare disease with an unknown cause. This teaching case report highlights the presentation, differential diagnosis and management and treatment of TMD. It is intended to help eyecare providers recognize the condition and provide proper patient education and management.

Key Words: Terrien's, cornea, ectasia, anterior segment

Background

Terrien's marginal degeneration (TMD) is a rare, slowly progressive, peripheral corneal ectasia of unknown etiology. The condition is most commonly seen in males past the age of 40. Initially, TMD presents as small, yellow-white, stromal opacities composed of lipids with some superficial vascularization, which begins superiorly and spreads circumferentially. With progression, a gutter forms in the affected area due to stromal thinning, leaving the epithelium intact. The condition is often bilateral and asymmetric. Perforation of the cornea is rare but may occur spontaneously or secondary to trauma. Patients are often asymptomatic but may complain of mild irritation or vision changes due to increasing against-the-rule or oblique astigmatism.

This teaching case report is intended for optometry students at all levels. For first- and second-year students, emphasis can be on corneal structure and diagnostic testing that can be performed. For third- and fourth-year students and residents, the same concepts can be stressed, with the addition of differential diagnosis and treatment and management of patients with TMD.

Case Description

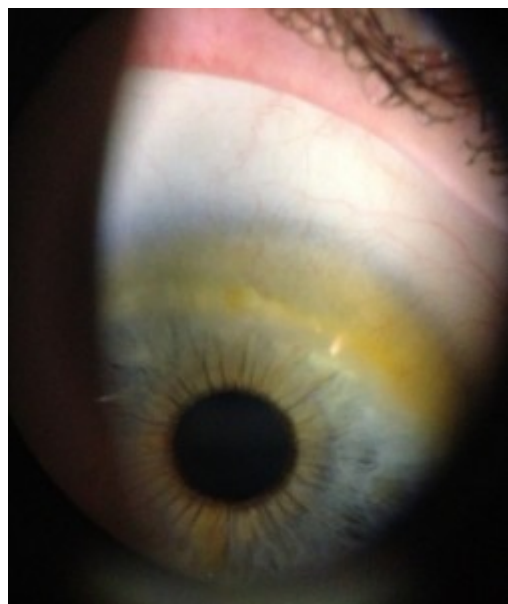

Figure 1. Stromal opacities in the superior cornea OD.

[Click to enlarge](#)

The patient, a 52-year-old Caucasian male, was seen at the clinic for a comprehensive ocular examination. He complained that his wife had noticed some coloration changes "on his right iris" in the upper quadrant. She noticed this "discoloration" about one month earlier. He reported no other problems such as eye pain, flashes, photophobia, diplopia, headaches or trauma. He did have longstanding floaters with no recent changes or increase in number. His last eye exam was approximately 10 years ago. The only significant ocular diagnosis at that examination was an alternating exotropia.

The patient's medical history included a recent tooth abscess for which he underwent a root canal and finished a round of antibiotics. The eye discoloration was present before the round of antibiotics. His history also included occasional mild joint pain. His current medications and supplements included glucosamine, methylsulfonylmethane (MSM), fish oil and turmeric. His only reported allergy was to penicillin. The patient stated that he had never been a smoker, did not currently drink, and did not use any recreational drugs. Blood pressure was taken in-office from the right arm with the patient in a seated position and measured 120/78 mmHg. Weight and height were 175 lbs. and 67.5 in. BMI was calculated at 27. Family history included a paternal grandmother who had type 1 diabetes, a sister who had suffered a stroke, and a father who was hypertensive. The patient was oriented to time, place and person, and his mood and affect were appropriate.

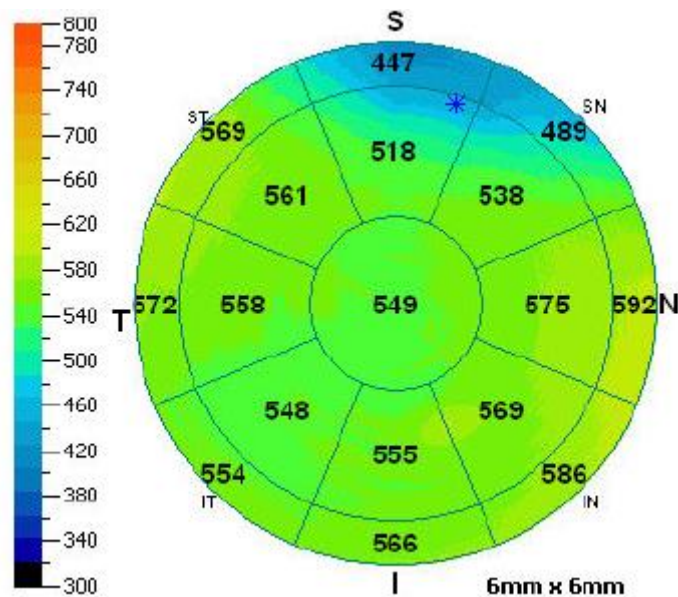
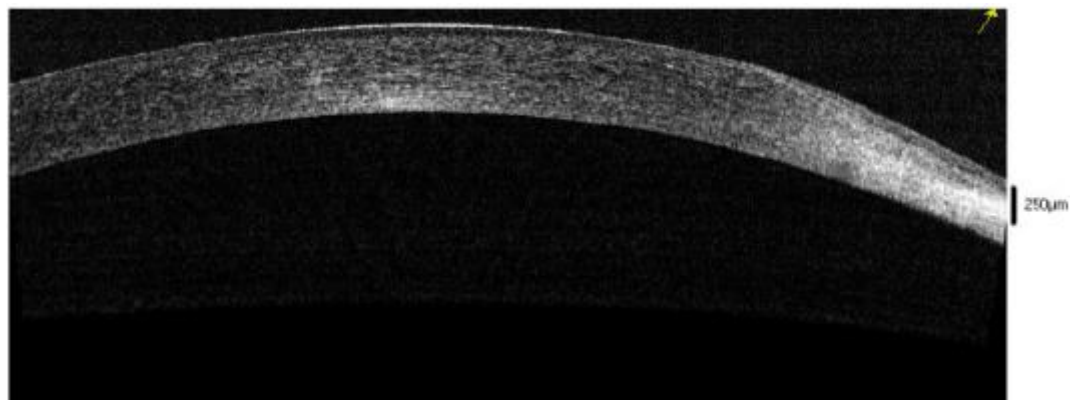


Figure 2A and 2B. Anterior segment OCT depicting superior nasal thinning OD.
[Click to enlarge](#)



[Click to enlarge](#)

The patient's entering visual acuities were OD 20/50- distance and 20/25- near, and OS 20/20- distance and 20/40 near. He did not present with glasses; therefore, all visual acuities were taken without correction. The patient's pupils were equal, round and reactive to light and accommodation without afferent pupillary defects OD, OS. Extraocular muscles were full with no restrictions. FDT perimetry was full with no defects. Cover test confirmed an 18 prism diopter constant alternating exotropia at distance and near. Subjective refraction was OD -1.00 - 1.00 x 055, and OS -0.25 - 0.75 x 090. A +2.00 add resulted in visual acuities of 20/20 OD and OS at both distance and near.

Slit lamp examination revealed superior yellow-white stromal opacities extending circumferentially from 11 to 3 o'clock with superficial corneal limbal neovascularization OD. The left eye was unremarkable. Intraocular pressures as measured by Goldmann tonometry were 20 mmHg OD and 18 mmHg OS. Dilated fundus examination showed cup to disc ratios of 0.20 round OD and 0.25 round OS with no other ocular pathology.

Follow-up: one month after initial presentation

At a one-month follow-up visit, the condition appeared to be stable with no advancement. The patient was educated about the progressive nature of this condition and the importance of wearing eye protection. He will be monitored closely for further progression as well as involvement of the other eye.

Additional testing

Additional testing performed at the one-month follow-up included anterior segment photos that were taken using the slit lamp biomicroscope and an iPhone (**Figure 1**). Anterior

segment optical coherence tomography (OCT) was also performed, and it showed thinning in the areas of the stromal opacities (**Figure 2**). Corneal topography was performed and revealed a change in curvature superiorly, in the areas of stromal opacity, consistent with thinning and flattening (**Figure 3**). Unfortunately, the topographical maps were not clear in the area of the superior cornea. Image acquisition proved challenging in this patient due to lid position. At future visits, manual attempts to better manage the lid position should be considered.

Learning Objectives

- ▶ to describe the ocular presentation of Terrien's marginal degeneration
- ▶ to describe additional testing that can be performed to confirm a diagnosis
- ▶ to describe treatment and management for Terrien's marginal degeneration
- ▶ to identify differentials that can mimic Terrien's marginal degeneration

Key Concepts and Discussion Points

- ▶ Ocular anatomy
 - corneal layers
 - corneal histology
- ▶ Ancillary diagnostic tests
 - placido topography
 - scanning slit topography
 - anterior segment optical coherence tomography
 - ultrasound biomicroscopy
 - in vivo confocal microscopy
- ▶ Ocular disease
 - ocular findings
 - differential diagnosis
 - arcus senilis
 - Mooren's ulcer
 - keratoconus
 - pellucid marginal degeneration
 - vernal keratoconjunctivitis
 - ocular rosacea
- ▶ Patient education, treatment and management

Literature Review

Terrien's marginal degeneration is a slowly progressive thinning of the peripheral cornea. It usually begins superior-

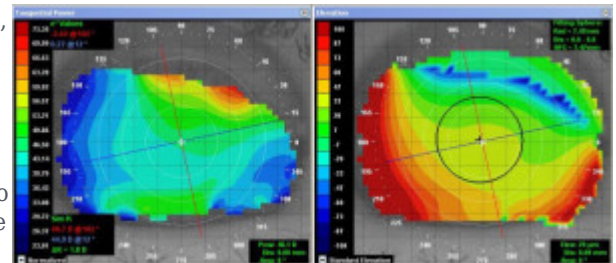


Figure 3. Corneal topography OD showing curvature change superiorly.

[Click to Enlarge](#)

nasally and progresses circumferentially. Yellow-white stromal opacities with superficial neovascularization are present. These stromal opacities are composed of scarring and lipid infiltration, and there is a distinct interval between the limbus and site of infiltration. Ultimately, stromal degeneration occurs, causing formation of a peripheral gutter.¹ The exact etiology of TMD is unknown, but there is male predilection [3:1]. The condition usually appears in the third to fifth decade of life, but it can occur at any age.² Both eyes are commonly affected, but presentation can be asymmetric.¹

Histological changes have been noted in patients with TMD. The epithelium remains intact while the subepithelial area degenerates.³ Lopez and associates presented a case of TMD that required a crescent-shaped keratoplasty. They noted that light microscopy of a lamellar corneal button revealed a thickened epithelium, with an irregular Bowman's layer. The anterior stroma was infiltrated with inflammatory cells including lymphocytes and some neutrophils. The adjacent conjunctiva was infiltrated with a few lymphocytes as well.¹ More recently, Ceresara and associates wrote of a case of TMD without perforation; in vivo confocal microscopy of the cornea was used to better evaluate the microstructures of the cornea. Confocal images revealed a normal superficial epithelium, irregular Bowman's layer, and deposits of nonhomogeneous hyper-reflective material (corresponding to the lipid deposition) at the basal epithelium and anterior stroma. Neovascularization was present at the level of the basal epithelium in the paralimbal cornea. They also reported inflammatory cell infiltration at the level of the adjacent paralimbal conjunctiva and peripheral basal epithelium.² Ferrari and colleagues published the results of a study in which in vivo confocal microscopy revealed similar findings without the presence of inflammatory cells.⁴

Recent studies suggest the use of scanning slit topography to aid in the diagnosis and differentiation of TMD from other corneal thinning disorders. Scanning slit topography utilizes optical slits that scan along multiple points of the cornea. A video camera positioned at a 45-degree angle from the cornea captures reflections of the slits. This allows for measurements of the anterior and posterior cornea, as well as corneal pachymetry.⁵ Topography mapping and videokeratography are useful tools in monitoring corneal curvature, elevation and the amount of corneal astigmatism. They are beneficial when fitting rigid gas permeable contact lenses for these patients. Typically in TMD, corneal topography reveals flattening over the peripheral areas of thinning with steepening opposite to the mid-point of thinning, which results in against-the-rule or oblique astigmatism. Scanning slit topography can also be used to monitor the anterior and posterior surfaces with respect to the "best fit sphere" (float) and corneal thickness. In a reported case of unilateral TMD (no slit lamp biomicroscopy findings in the contralateral eye), scanning slit topography float data revealed anterior and posterior elevation in the contralateral eye. In this case, keratometric maps showed skewing of principal meridians and corneal steepening. These changes, while not classic topographic evidence of TMD, may suggest the need for close monitoring to watch for progression.⁶

Due to its high magnification and ability to depict the size and shape of structures in the anterior segment, ultrasound biomicroscopy (UBM) has also been shown to be useful for monitoring the cornea. UBM is able to quantify the thickness of the cornea and help to detect progression of disease. It can reveal subtle changes in the cornea, including changes in Bowman's layer, Descemet's membrane and stromal structure.⁷

Treatment and management of TMD are largely supportive because patients are often asymptomatic. In the case of mild adjacent conjunctival inflammation, topical steroids may be used sparingly. Steroids should be used cautiously because they can exacerbate corneal melt and increase thinning. Topical ocular lubricants can provide comfort. Monitoring patients for progression plays a significant role in the management process. As already discussed, corneal topography, anterior segment OCT, confocal microscopy, biomicroscopy and ultrasound biomicroscopy are all sound clinical options for following progression. Due to risk of corneal perforation in the area of TMD, polycarbonate lenses are highly recommended, as are American National Standards Institute-compliant safety glasses when warranted. If spectacle correction of vision is not possible due to complex or irregular astigmatic changes, piggybacked rigid gas permeable contact lenses or scleral lenses are both viable options. It is recommended that patients wear plano polycarbonate lenses over their contact lens prescription.

If corneal perforation occurs or if a patient is at high risk of perforation, a crescentic lamellar or full-thickness keratoplasty^{8,9} can be performed. A lamellar keratoplasty does not replace the entire thickness of the cornea. Instead, only Bowman's layer and the anterior portion of the corneal stroma are replaced. Descemet's membrane, the endothelium and the deep stroma are left intact. A crescentic lamellar keratoplasty utilizes this technique when only the thinned portion of the patient's cornea is replaced with crescent-shaped donor cornea while the rest remains preserved. Lamellar keratoplasties are often preferred over penetrating keratoplasties because of the decreased risk of graft rejection, irregular astigmatism and corneal opacification. Symptoms of perforation can range from a decrease in visual acuity to tearing or pain. Signs of perforation include a positive Seidel sign, a shallow or flat anterior chamber, and folds in Descemet's membrane. At the onset of clinical care for TMD, patients should always be informed of the possibility of

perforation.¹⁰

Differential Diagnosis

It is important for the clinician to recognize and be able to differentiate Terrien's marginal degeneration from other corneal pathologies that can have similar appearances, including arcus senilis, Mooren's ulcer, keratoconus, pellucid marginal degeneration (PMD), vernal keratoconjunctivitis (VKC) and ocular rosacea.

- Arcus senilis is the most common peripheral corneal opacity. Stromal lipid deposits begin in the superior and inferior perilimbal cornea and progress circumferentially to form a band approximately 1 mm wide. The peripheral edge is sharp and separated from the limbus by a clear zone. The translucent interval may undergo mild thinning.¹⁰
- Mooren's ulcer is a rare, idiopathic, circumferential stromal ulceration in the peripheral cornea. It can be unilateral or bilateral with no specific age demographic. Mooren's ulcer is usually associated with moderate to severe pain, photophobia and blurred vision secondary to astigmatism. An autoimmune trigger or a history of insult or trauma to the cornea may be responsible for Mooren's ulceration. Ulceration involves the anterior one-third of the cornea and progresses circumferentially and centrally with infiltration and vascularization at the leading edge.¹⁰
- Keratoconus is a progressive stromal thinning occurring centrally or paracentrally. It usually affects both eyes but can be asymmetric. Onset usually occurs around puberty. Signs of keratoconus include scissoring reflex on retinoscopy; slit lamp exam may reveal Vogt striae (vertical tension lines in the posterior cornea) and/or an epithelial Fleischer ring (epithelial iron deposits at the cone base). Keratoconus patients often have irregular astigmatism with steep keratometry readings. Munson's sign, which is bulging of the lower eyelid on down-gaze, may also be present. In severe cases, acute hydrops (stromal edema due to leakage of aqueous humor through a tear in Descemet's membrane) may occur.¹⁰
- PMD is a rare thinning of the inferior cornea that causes reduced visual acuity. It is usually bilateral but can be asymmetric. Onset occurs during the fourth and fifth decades of life. Clinical presentation is a slowly progressive band of inferior thinning extending down to 1 mm from the limbus. Unlike in keratoconus, there is no Fleischer ring or Vogt striae, and PMD presents with an area of steepening superior to the area of corneal thinning.¹⁰
- VKC is a recurrent bilateral disorder. It primarily affects young boys around the age of 7. VKC is more common in warmer, dry areas such as the Mediterranean, sub-Saharan Africa and Middle East. Symptoms include itching, photophobia, foreign body sensation and mucous discharge. VKC can affect the limbal area of the cornea, the palpebral conjunctiva, or both. Signs include giant papillae on the superior tarsal conjunctiva and/or limbal papillae with or without a white apex called Horner-Trantas dots. Corneal changes such as punctate epithelial erosions, macroerosions and shield ulcers can also occur.¹⁰
- Ocular rosacea affects 6-18% of patients with systemic rosacea. Rosacea is an idiopathic skin condition affecting sun-exposed areas. Clinical features range from facial flushing to a papulopustular rash and, in later stages, thickening of the skin that can evolve into rhinophyma. Ocular symptoms include irritation, burning and tearing. The lids, conjunctiva and cornea can all be involved. The lids can show superficial telangiectasias and blepharitis. Conjunctival bulbar hyperemia may be present. The cornea can be impacted by minor punctate epithelial erosions, marginal keratitis and, in severe cases, corneal scarring and vascularization.¹⁰

Discussion

Although Terrien's marginal degeneration is rare, it is important that eyecare providers differentiate it from other conditions so they can set patient expectations and initiate proper management and treatment. A thorough case history and careful slit lamp examination are essential. It is imperative to use topical steroids conservatively due to the risk of corneal thinning. Corneal perforation is rare with TMD, but early prescription of polycarbonate lenses can reduce the risk by offering protection from blunt trauma.

Conclusion

This case report is intended to educate eyecare providers on the presentation and management of Terrien's marginal degeneration. It reviews multiple ways to monitor the progression of the disease, as well as treatment options depending on the severity of thinning. This case report points out the distinguishing characteristics of TMD and other differentials. This information should be helpful to eyecare providers when they encounter a rare case of TMD.

References

1. Lopez JS, Price FW, Whitcup SM, et al. Immunohistochemistry of Terrien's and Mooren's corneal degeneration. *Archives of Ophthalmology*. 1991;109(7):988-992.
2. Ceresara G, Migliavacca L, Orzalesi N, Rossetti L. In vivo confocal microscopy in Terrien marginal corneal degeneration: a case report. *Cornea*. 2011;30(7):820-824.
3. Guyer DR, Barraquer J, McDonnell PJ, Green WR. Terrien's marginal degeneration: clinicopathologic case reports. *Graefes Archive Ophthalmology* 1987;225(1):19-27.
4. Ferrari G, Tedesco S, Delfini E, Macaluso C. Laser scanning in vivo confocal microscopy in a case of Terrien marginal degeneration. *Cornea*. 2010;29(4):471-475.
5. Review of Cornea and Contact Lenses [Internet]. Yeung KK, Chang S. New equipment sees the cornea better. c2011 [cited 2015 July 17] Available from <http://www.reviewofcontactlenses.com/content/d/disease/c/30278/>.
6. Fernandes M. Scanning slit topography: Diagnostic boon in presumed unilateral Terrien's marginal degeneration. *Cont Lens Anterior Eye*. 2011;34(6):282-286.
7. Skribek A, Sohár N, Gyetvai T, Nógrádi A, Kolozsvári L. Role of ultrasound biomicroscopy in diagnosis and treatment of Terrien disease. *Cornea*. 2008;27(4):427-433.
8. Eyenet [Internet] Vishak J, Goins KM, Afshari NA. Deep anterior lamellar keratoplasty. c2007 [cited 2015 July 17] Available from <http://www.aao.org/publications/eyenet/200709/pearls.cfm>.
9. Cheng CL, Theng JT, Tan DT. Compressive C-shaped lamellar keratoplasty: a surgical alternative for the management of severe astigmatism from peripheral corneal degeneration. *Ophthalmology*. 2005;112(3):425-430.
10. Kanski J, Bowling B, Nischal K. *Clinical ophthalmology: a systematic approach* (7th ed.). Edinburgh: Elsevier/Saunders; 2011.



Dr. Peabody is a clinical faculty member at Indiana University School of Optometry. He teaches clinically in the school's primary care clinic and didactically in courses pertaining to clinical decision-making, the business aspects of optometry and the profession of optometry. Dr. Peabody is also Chief of Primary Care Services at Atwater Eye Care Center.

Dr. Boucher, a 2014 graduate of Indiana University School of Optometry, is an optometrist at Choctaw Nation Health Clinic in Poteau, Okla.

Dr. Cheney, a 2014 graduate of Indiana University School of Optometry, is a private practice optometrist in Osborne and Stockton, Kan.

DR. HOPPE DELIVERS KEYNOTE ADDRESS AT SUMMER INSTITUTE FOR FACULTY DEVELOPMENT



Elizabeth Hoppe, OD,
MPH, DrPH

Dr. Elizabeth Hoppe was honored as the keynote speaker during ASCO's 2015 Summer Institute for Faculty Development (SIFD), which took place July 12-15 in St. Louis. Dr. Hoppe, ASCO Secretary-Treasurer and the Founding Dean of Western University of Health Sciences College of Optometry, has been involved with the SIFD since its inception in 2006, providing exceptional leadership and serving as a mentor and speaker.

The 2015 program was ASCO's sixth SIFD. Thirty-eight faculty members from 20 schools and colleges of optometry attended. The goal of the SIFD is to provide participants with an opportunity to gain the necessary knowledge and skills to enhance their success in an optometric academic environment as lifelong productive faculty, thus contributing to increased retention of faculty in the schools and colleges of optometry. The program promotes active learning in a nurturing environment and is comprised of formal presentations, workshops and shared activities in the areas of teaching and learning, scholarship and academic culture. Each attendee develops a long-term career plan with specific goals, objectives and action strategies.

For more information on the SIFD, e-mail ASCO's Director of Meetings and Special Interest Groups [LaShawn Sidbury](#), or call her at (301) 231-5944 ext. 3012.

SIGNATURE SPONSOR

Alcon

Gold Sponsor

Johnson & Johnson

VISION CARE, INC.

Silver Sponsor

sponsored by
essilor

Bronze Sponsor

Allergan
Academic Partnership
YOUR FUTURE. OUR FOCUS.

Bronze Sponsor

LUXOTICA
RETAIL

Bronze Sponsor

**NATIONAL BOARD
OF EXAMINERS IN OPTOMETRY**

Thank You!

ASCO expresses its appreciation to the following companies and organizations for generously supporting the Summer Institute for Faculty Development: Alcon, Vistakon, Essilor, Luxottica, Allergan and the National Board of Examiners in Optometry.



DEADLINE EXTENDED FOR UPCOMING INTERNATIONAL OPTOMETRIC EDUCATION THEME EDITION

International Optometric Education: Global Expansion and Transformation

(New deadline to submit papers: June 1, 2016)

Over the past 20 years, the profession of optometry has undergone dramatic global changes: expanding scope of practice, increasing quality assurance expectations, significant diversification of students, and the accelerating impact of information technology. Underpinning these changes has been the critical role of international optometric education in supporting and catalyzing this transformation. The same global forces that are driving the transformation of the profession are also creating challenges and opportunities for optometric educational institutions. Student, faculty, patient and institutional expectations are converging and greater accountability is expected. This includes such areas as clinical competency, professional ethics, interprofessional collaboration and curricular innovation.

Authors are invited to submit scholarly articles that address this theme and underscore innovation and the impact educational institutions are having on their students, the profession and the communities they serve. We encourage scholarly articles that are translational and promote global dissemination.

We are pleased to have [Anthony F. Di Stefano, OD, MEd, MPH](#), Salus University, serve as the Guest Editor of this issue. For more information, please e-mail journal Editor [Aurora Denial, OD, FAAO](#).

