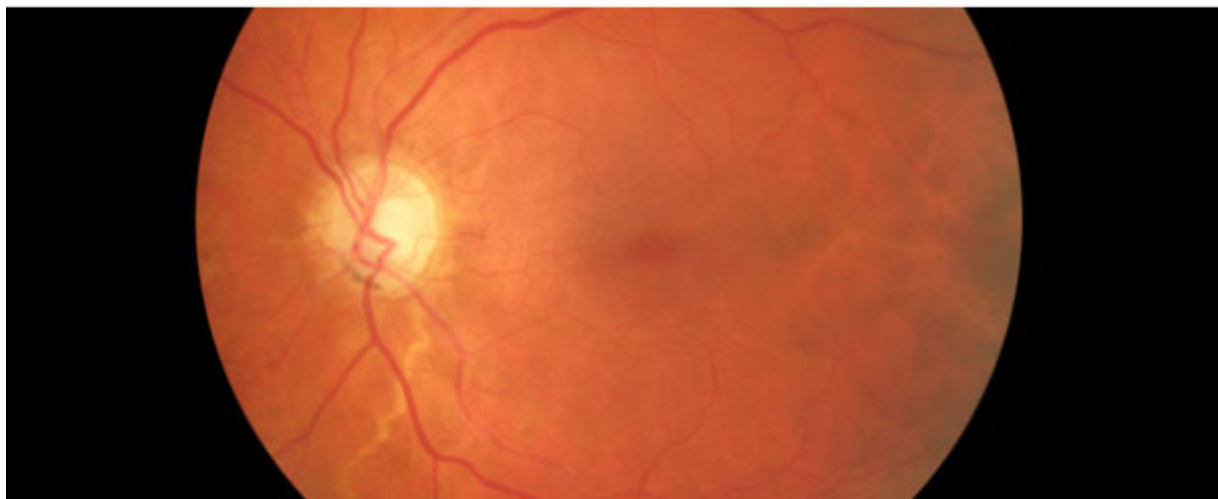


# Optometric Education: Volume 43 Number 2 (Winter-Spring 2018)

## OPTOMETRIC EDUCATION

The Journal of the Association of Schools and Colleges of Optometry

Volume 43, Number 2  
Winter-Spring 2018



Hypertensive Choroidopathy: a  
Teaching Case Report

Retinoschisis: a Teaching Case Report

Virtual Patient Instruction and Self-  
Assessment Accuracy in Optometry  
Students

### ALSO INSIDE

Editorial: Keeping Disruptive Technologies in Perspective

Educator's Podium: When Early Intervention Fails to  
Improve Outcomes in Neovascular AMD

Special Announcement: It's Time to Apply for a 2018  
Educational Starter Grant

Industry News

## Table of contents

<b>INDUSTRY NEWS .....</b>	<b>1</b>
<b>WHEN EARLY INTERVENTION FAILS TO IMPROVE OUTCOMES IN NEOVASCULAR AMD .....</b>	<b>5</b>
<b>RETINOSCHISIS: A TEACHING CASE REPORT .....</b>	<b>9</b>
<b>VIRTUAL PATIENT INSTRUCTION AND SELF-ASSESSMENT ACCURACY IN OPTOMETRY STUDENTS .....</b>	<b>17</b>
<b>IT'S TIME TO APPLY FOR A 2018 EDUCATIONAL STARTER GRANT .....</b>	<b>27</b>
<b>KEEPING DISRUPTIVE TECHNOLOGIES IN PERSPECTIVE .....</b>	<b>28</b>
<b>HYPERTENSIVE CHOROIDOPATHY: A TEACHING CASE REPORT .....</b>	<b>30</b>

## INDUSTRY NEWS



### Intern Program Taking Applications



Walmart is accepting applications for its Optometry Intern Program, which is designed to prepare the company's next generation of optometrists for practice within Walmart and Sam's Club stores.

According to Walmart, the flexible 10-week hands-on training program takes place during the summer between first and second year. It includes an OD mentor, is in-depth, and provides experience across a range of areas. Interns gain experience in basic visual services as well as diagnosis, management and treatment of visual problems and ocular disease, contact lens fitting, patient education and clinical business strategies. The internship may extend beyond the summer and is open to first- through fourth-year students who wish to participate on weekends and during academic breaks. Start and end dates are flexible to accommodate the interns' school curriculum timelines.

Interested students should [e-mail Maritza Fernandez](#) or call her at (479) 204-4603.

### Charitable Giving Aids Access to Eye Care



Alcon, a division of Novartis, donated nearly \$65 million in cash and products to fund medical missions, community organizations, eye exams, glasses, ophthalmic care and patient awareness programs in 2017.

To further educate consumers about the importance of regular eye care, Alcon also announced its continuing commitment to [Think About Your Eyes](#), the national consumer education campaign presented by The Vision Council and the American Optometric Association. Alcon has supported the campaign four years in a row, contributing \$2 million for 2018. Eyecare professionals interested in having their practice listed with the Think About Your Eyes doctor locator and accessing digital banners for use on their practice websites can visit [ThinkAboutYourEyes.com](#).

For more information about Alcon's partnerships and corporate giving efforts, visit the [Corporate Responsibility section](#) of the company's website.

**Also:** Alcon recently launched new U.S.-specific packaging for Air Optix plus HydraGlyde contact lenses to promote proper purchase and wear. The new packaging follows the 2017 launch of U.S.-specific packaging for Dailies AquaComfort Plus contact lenses.

### Connecting and Supporting Optometry Practice Buyers and Sellers



The [Practice Management Center \(PMC\)](#), [Vision One Credit Union](#) and [VSP Global](#) are teaming up through [optometrymatch.com](#) to assist doctors who are looking to buy or sell all or part of an optometry practice. The service utilizes PMC's Smart Match model to connect buyers and sellers and then works closely with the doctors to provide support and consultation throughout the practice transition process.

According to PMC CEO Mark Wright, OD, "Purchasing a practice can be a challenging experience for doctors. Similarly, selling a practice can also be an overwhelming experience for retiring doctors. Our goal is to make the process smooth for both sides, which will in turn help ensure the future success and growth of independent optometry."

#### **New Website Launches with Doctors and Patients in Mind**



HOYA has launched a [new global website](#) designed to make lens technology easy for patients and eyecare professionals. At the new site, eyecare providers can find not only product technology information but also practice development and other content that is geared toward helping them build their business and differentiate their brand. For spectacle wearers, jargon-free content is written by experts in the field. Also at the site, which has been translated into more than 40 languages, eyecare professionals can connect with their local company representative, and patients can find eyecare providers in their ZIP code.

"This is an exciting time for HOYA," says Barney Dougher, president of HOYA Vision Care, North America. "We're growing as an international company and brand, yet the new website offers functionality at the local level that helps us stay connected and relevant to our customers."

#### **Stay Tuned for a Revamped Brand Identity**



Beginning in May 2018, patients and eye doctors will see a rejuvenated brand identity, including a “Light Under Control” consumer advertising campaign, from Transitions Optical. The new look and campaign build upon the company’s efforts to recruit new wearers of photochromic lenses. Primary aims are to showcase the relevance of the lenses to today’s fast-paced lives and to attract a younger generation of single-vision wearers to the photochromic lens category.

Point-of-sale and digital assets that support the new visual identity will become available to eyecare professionals in the second quarter. For more information about the company and Transitions lenses and helpful resources, visit [Transitions.com](http://Transitions.com) or [TransitionsPRO.com](http://TransitionsPRO.com).

**Also:** Research conducted on behalf of Transitions Optical indicates that while enrollment in vision benefits remains high among all employees, younger generations, who make up an increasing portion of the workforce, are less likely to enroll and less likely to understand the importance of regularly scheduled, comprehensive eye exams.

### **Dr. Mayers Steps into New Role**



[Johnson & Johnson Vision](http://Johnson & Johnson Vision) appointed Michael Mayers, OD, FAAO, to the position of Director, US Advocacy, Vision Care. In his new role, Dr. Mayers will shape strategy and lead eye health advocacy efforts to promote patient health and safety in collaboration with legislators, regulators, associations and doctors. Dr. Mayers joined the company in 2011 and has since held roles in R&D clinical development, global medical affairs and global marketing.

**Also:** Johnson & Johnson Vision has expanded the available parameters for 1-Day Acuvue Moist Brand Contact Lenses for Astigmatism, a daily disposable contact lens that offers patients Blink-Stabilized Design for clear, stable vision and Lacreon Technology designed to provide a cushion of moisture for long-lasting comfort.

### **New Tools for the Practice Software Platform**



Rev360, the eyecare software and business services company for RevolutionEHR, launched Pulse, a practice performance dashboard that helps users manage their eyecare business, all from within RevolutionEHR. Pulse provides instant, robust views into practice data for tracking key performance indicators, analyzing and exploring trends, and comparing performance metrics across the practice.

Because RevolutionEHR is cloud-based, Pulse was instantly enabled for all practices using RevolutionEHR, with no setup or installation required. Pulse data is automatically kept up to date and is provided to RevolutionEHR users at no charge. Learn more about Pulse at the [RevolutionEHR website](http://RevolutionEHR website).

### Inspired Students Earn Grants



Optical retailer [National Vision Holdings Inc.](#) selected a grand prize winner and two runners-up in its 2017-2018 Grant Program. Inspired by Simon Sinek's TED Talk "Start with Why," National Vision asked third- and fourth-year optometry students what inspired them to become ODs and what they believe to be their personal mission as future optometrists. Students entered by submitting an essay or short video, and a panel of judges from National Vision selected the winners.

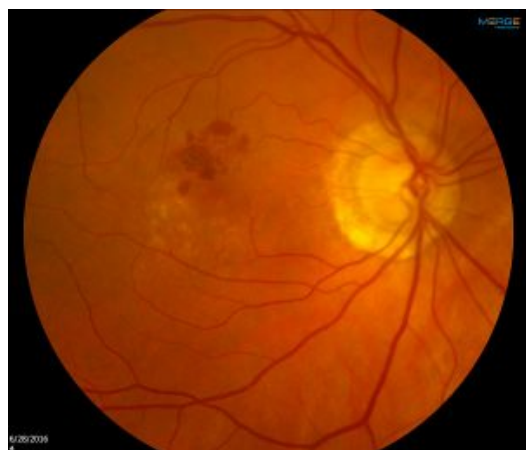The 2017-2018 grant recipients:

- First place (\$5,000 grand prize) — Leanne Leung, MCPHS School of Optometry, class of 2019
- Runner-up (\$1,000 prize) — Kandace Alfred, University of Missouri - St. Louis College of Optometry, class of 2018
- Runner-up (\$1,000 prize) — Bee Bui, University of California - Berkeley School of Optometry, class of 2019



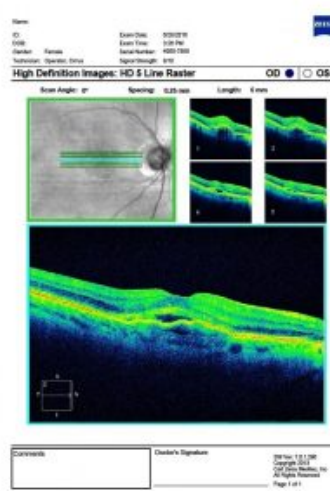
## WHEN EARLY INTERVENTION FAILS TO IMPROVE OUTCOMES IN NEOVASCULAR AMD

In the [Summer 2017 \(Volume 42, Number 3\)](#) issue of *Optometric Education*, we presented a teaching case report titled “Normotensive Glaucoma Follow-Up with Incidental Finding of Choroidal Neovascular Membrane.” The case highlighted the need for student clinicians to be flexible and modify their exam plan when novel clinical findings emerge. The patient had presented for a Humphrey visual field test and glaucoma follow-up and was incidentally found to have a minimally symptomatic choroidal neovascular membrane resulting from conversion of non-neovascular to neovascular age-related macular degeneration (AMD) (**Figures 1 and 2**).



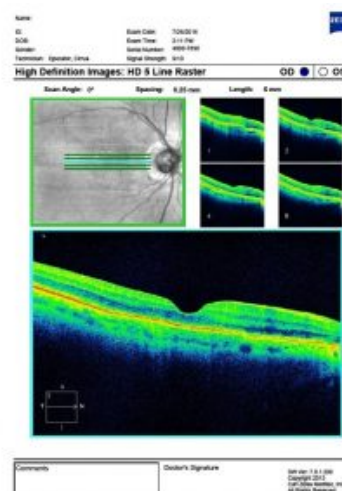
**Figure 1.** Fundus photo OD on 06/28/16 showing a mottled appearance of the macula with several small and intermediate drusen and large central-superior subretinal hemorrhage.

[Click to enlarge](#)



**Figure 2.** Optical coherence tomography five-line raster scan of the macula OD on 06/28/16 showing drusen and pigment epithelial detachment with overlying subretinal fluid causing macular elevation.

[Click to enlarge](#)



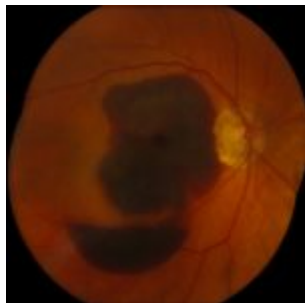**Figure 3.** Optical coherence tomography five-line raster scan of the macula OD on 7/26/16 showing reduction in the height of the pigment epithelial detachment and resolution of subretinal fluid.

[Click to enlarge](#)

The neovascular membrane was presumably discovered relatively early because the patient first began experiencing blurred vision only one week prior. She was seen same day in the retina service and found to have a fibrovascular pigment epithelial detachment (FVPED) with exudation, subretinal fluid (SRF) and large central subretinal hemorrhage (SRH). She subsequently received an intravitreal injection of bevacizumab (Avastin). Following a loading dose of three monthly bevacizumab injections, the scotoma, SRF and SRH resolved (**Figure 3**). After the fourth monthly injection, because the patient had presented with a large SRH, a “treat and extend” rather than an “as needed” treatment strategy was selected.

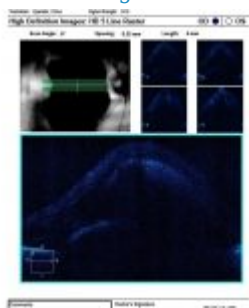
### Case Update





**Figure 4.** Fundus photo on 11/16/16 showing new large central subretinal hemorrhage and bullous sub-retinal pigment epithelium hemorrhage.

[Click to enlarge](#)



**Figure 5.** Optical coherence tomography five-line raster scan of the macula OD on 11/16/16 showing massive worsening of the pigment epithelial detachment with fluid, retinal pigment epithelial tear and subretinal hyper-reflective material.

[Click to enlarge](#)

Unfortunately, despite the early intervention with significant anatomic improvement, the patient's visual outcome was poor. Findings remained stable at the five-week extension visit, i.e., the SRF or SRH had not recurred. Therefore, another bevacizumab injection was given, and a six-week extend period was pursued. Despite the stabilization of the condition, three weeks after the fifth injection, the patient urgently presented with a dramatic reduction in vision and new large scotoma. Her uncorrected visual acuity had dropped from 20/40 at the previous visit to 20/400 (eccentrically).

Ophthalmoscopic exam showed a new large central SRH involving the entire macula and a retinal pigment epithelium (RPE) tear with bullous sub-RPE hemorrhage (**Figure 4**). Macular optical coherence tomography (OCT) supported the exam findings, showing dramatic worsening of the PED and new RPE tear with subretinal hyper-reflective material (**Figure 5**).

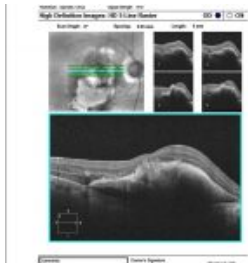
The patient was treated with an intravitreal injection of aflibercept (Eylea) 2 mg and scheduled for a two-week follow-up visit. At follow-up, she reported only minimal improvement in vision. Visual acuity was finger counting at three feet (eccentrically). Ophthalmoscopic exam showed persistent subretinal and sub-RPE hemorrhage, and OCT showed no appreciable change. Treatment with Eylea was continued at two- to four-week intervals in an effort to resolve the hemorrhage and reduce the risk of re-bleeding (**Figures 6-7**). Despite several months of aflibercept treatment (total of 8) and resolution of the large hemorrhage, vision improved only minimally to 20/200 due to the RPE tear and development of central dense subretinal fibrosis (**Figure 8**). The utility of ongoing intravitreal treatment was questioned given the abnormal retinal anatomy. The patient, however, chose to continue because she felt her scotoma had improved significantly. She currently receives aflibercept injections at six- to eight-week intervals to maintain her current level of vision and reduce the risk of another catastrophic macular bleed.

## Discussion

AMD is a multifactorial disease with a poorly understood pathogenesis. Age is a major risk factor, and smoking remains the only known modifiable risk factor.<sup>1</sup> Genetics also plays a role as 52 genetic variants across 34 loci have been associated with development of AMD.<sup>2</sup> Conversion to neovascular AMD is characterized by the uncontrolled expression of pro-angiogenic vascular endothelial growth factor (VEGF), which leads to the development of new abnormal blood vessels from the choroid.<sup>3</sup> While the emergence of intravitreal anti-VEGF therapies for neovascular AMD has been a significant advance in eye care in recent years, 10-15% of patients do not respond to anti-VEGF therapy and lose >15 ETDRS letters of visual acuity.<sup>4</sup> It is unclear why patients respond to anti-VEGF treatment differently, and current practice involves treating poorly

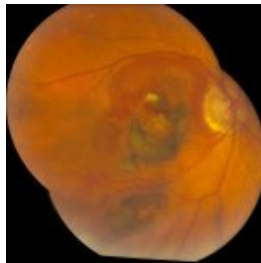


responsive patients more aggressively, i.e., more frequently, or with increased dosing and/or a different anti-VEGF drug, often with variable responses.<sup>3</sup>



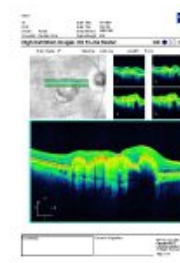
**Figure 6.** Optical coherence tomography five-line raster scan of the macula OD on 12/06/16 showing reduced height of the pigment epithelial detachment and retinal pigment epithelium tear.

[Click to enlarge](#)



**Figure 7.** Fundus photo OD on 1/31/17 showing old subretinal hemorrhage inferior and resolving sub-retinal pigment epithelium hemorrhage parafoveally and retinal pigment epithelium tear.

[Click to enlarge](#)



**Figure 8.** Optical coherence tomography five-line raster scan of the macula OD on 07/11/17 showing persistent retinal pigment epithelium tear with subretinal fluid and subretinal hyper-reflective material.

[Click to enlarge](#)

Tears of the RPE are characterized by a separation of the RPE basement membrane from the adjacent layers of Bruch's membrane.<sup>5</sup> Visual acuity is often significantly affected, with an average visual acuity of 20/150.<sup>6</sup> On ophthalmoscopic exam, an RPE tear is visualized as a well-demarcated area of bare choroid immediately adjacent to a hyperpigmented, rolled-appearing area.<sup>7</sup> With a reported incidence of 0.06%-0.8%, RPE tears are an infrequent sequela of intravitreal anti-VEGF therapy.<sup>5</sup> Eyes with AMD, with or without choroidal neovascularization, particularly those with PEDs large in height, and eyes that have undergone previous treatment, including laser photocoagulation, photodynamic therapy or intravitreal corticosteroid or anti-VEGF injection, are most susceptible to developing RPE tears.<sup>8</sup> Increased pre-injection lesion size and increased SRF also increase a patient's risk for developing a tear of the RPE.<sup>9</sup> While an RPE tear following treatment of choroidal neovascularization may be visually devastating, the benefits of vision-preserving treatment outweigh the relatively low risk of the potential complication.

A common assumption, particularly among student clinicians, is that a patient "will be OK" once he or she has been referred to the appropriate specialist, ophthalmic or otherwise. This case highlights that, even with early detection and intervention demonstrating significant anatomical improvement, patients with neovascular AMD may still have poor visual outcomes. AMD is a multifactorial disease, and VEGF is only one part of its pathobiology. Fortunately, numerous new therapeutic interventions are in the pipeline. They include oral tyrosine kinase inhibitors,<sup>10</sup> bone marrow-derived stem cells,<sup>11</sup> nanoparticle-loaded biodegradable injectable implants,<sup>12</sup> and RPE transplantation.<sup>13</sup> An improved understanding of the role of genetics in the management of retinal disease accompanies the potential new treatment options.<sup>14</sup> It is encouraging that these promising interventions may someday improve the care of patients with AMD.

## References

1. Yonekawa Y, Miller JW, Kim IK. Age-related macular degeneration: advances in management and diagnosis. *J Clin Med*. 2015;4(2):343-59.
2. Fritsche LG, Igl W, Bailey JN, et al. A large genome-wide association study of age-related macular degeneration highlights contributions of rare and common variants. *Nat Genet*. 2016;48:134-143.
3. Riaz M, Baird PN. Recent advances and future directions for the pharmacogenetic basis of anti-VEGF treatment response in neovascular age-related macular degeneration. *Neural Regen Res*. 2017 Apr;12(4):584-585.
4. Tsilimbaris MK, López-Gálvez MI, Gallego-Pinazo R, Margaron P, Lambrou GN. Epidemiological and clinical baseline characteristics as predictive biomarkers of response to anti-VEGF treatment in patients with neovascular AMD. *J Ophthalmol*. 2016;2016:4367631. doi: 10.1155/2016/4367631. Epub 2016 Mar 17.
5. Ronan SM, Yoganathan P, Chien FY, et al. Retinal pigment epithelium tears after intravitreal injection of bevacizumab (Avastin) for neovascular age-related macular degeneration. *Retina*. 2007;27:535-40.
6. Sarraf D, Joseph A, Rahimy E. Retinal pigment epithelial tears in the era of intravitreal pharmacotherapy: risk factors, pathogenesis, prognosis and treatment (An American Ophthalmological Society Thesis). *Transactions of the American*

- Ophthalmological Society. 2014;112:142-159.
7. Chang LK, Sarraf D. Tears of the retinal pigment epithelium: an old problem in a new era. *Retina*. 2007;27:523-34.
  8. Chan CK, Meyer CH, Gross JG, et al. Retinal pigment epithelial tears after intravitreal bevacizumab injection for neovascular age-related macular degeneration. *Retina*. 2007;27:541-51.
  9. Chan CK, Abraham P, Meyer CH, et al. Optical coherence tomography-measured pigment epithelial detachment height as a predictor for retinal pigment epithelial tears associated with intravitreal bevacizumab injections. *Retina*. 2010;30:203-11.
  10. Jackson TL, Boyer D, Brown DM, et al. Oral tyrosine kinase inhibitor for neovascular age-related macular degeneration: a phase 1 dose-escalation study. *JAMA Ophthalmol*. 2017 Jul 1;135(7):761-767.
  11. Cotrim CC, Toscano L, Messias A, Jorge R, Siqueira RC. Intravitreal use of bone marrow mononuclear fraction containing CD34+ stem cells in patients with atrophic age-related macular degeneration. *Clin Ophthalmol*. 2017;19:931-938.
  12. Bisht R, Jaiswal JK, Rupenthal ID. Nanoparticle-loaded biodegradable light-responsive in situ forming injectable implants for effective peptide delivery to the posterior segment of the eye. *Med Hypotheses*. 2017;103:5-9.
  13. Nommiste B, Fynes K, Tovell VE, Ramsden C, da Cruz L, Coffey P. Stem cell-derived retinal pigment epithelium transplantation for treatment of retinal disease. *Prog Brain Res*. 2017;231:225-244.
  14. Matušíková V, Balcar VJ, Khan NA, et al. CD36 gene is associated with intraocular pressure elevation after intravitreal application of anti-VEGF agents in patients with age-related macular degeneration: implications for the safety of the therapy. *Ophthalmic Genet*. 2017;30:1-7.



Dr. Bulson [[Ryan.Bulson@pacificu.edu](mailto:Ryan.Bulson@pacificu.edu)] is an Associate Professor at the Pacific University College of Optometry where he teaches optometric procedures and serves as a clinical attending for third- and fourth-year interns in the ocular disease and pediatrics clinics. He also serves as a staff optometrist at the Portland VA Medical Center where he supervises optometry students and residents.

Dr. Faridi is a medical retina specialist in the VA Portland Health Care System and an Assistant Professor of ophthalmology at the Casey Eye Institute, where she teaches ophthalmology residents, fellows and medical students. She also participates in research on age-related macular degeneration, diabetic retinopathy and inherited retinal degenerations at the Casey Reading Center.



## RETINOSCHISIS: A TEACHING CASE REPORT

### Abstract

*Retinoschisis is a rare condition that can have serious visual consequences if not managed properly. Retinoschisis is described as a separation of the neurosensory components of the retina. This case report discusses symptomatic reticular retinoschisis, as it presented within a routine diabetic examination. The patient presented with a mild change in peripheral floaters without a decrease in vision. Retinal elevation in the left eye was present upon fundusoscopic examination. The patient suffered from a full retinal detachment and underwent a pars plana vitrectomy and scleral buckle to repair the detachment, leaving his vision reduced. This case report explores important clinical findings, different types of retinoschisis, treatment options, differential diagnoses, and the optometrist's role in managing this condition.*

**Key Words:** retinoschisis, neurosensory, reticular retinoschisis, retinal detachment, retinoschisis, laser therapy/surgical repair

### Background

Retinoschisis means “splitting of neurosensory retina.”<sup>1-3</sup> In the various forms of retinoschisis, patients may present with or without symptoms. The condition can be unilateral or bilateral and it can be peripheral or central. Acquired retinoschisis and X-linked (juvenile) retinoschisis are the major subtypes mentioned in the literature. Senile, acquired, degenerative, and peripheral retinoschisis are synonymous. Acquired retinoschisis tends to be unilateral, have a later age of onset, and be nonprogressive.<sup>1</sup> There is no predilection for acquired retinoschisis based on gender or refractive error. Reticular retinoschisis is a subtype of acquired retinoschisis in which bullous elevation occurs in the peripheral retina.<sup>1</sup> Typical retinoschisis is another subtype of acquired retinoschisis and it involves little to no elevation.

X-linked retinoschisis (XLRS) disproportionally affects males, tends to show up earlier in life and, most notably, shows foveoschisis clinically.<sup>1</sup> A significant amount of information is available about the evolution of X-linked foveoschisis, but little is known about the pathological development of acquired retinoschisis.

Practicing optometrists can manage retinoschisis most efficiently by recognizing clinical presentation, utilizing imaging, and understanding retinal anatomy. This case report addresses the most common types of retinoschisis that an eyecare provider may encounter, and is appropriate for third- and fourth-year optometry students as well as optometric residents.

### Student Discussion Guide

#### Case description

A 67-year-old Caucasian male presented as a new patient for a diabetic eye examination. He had been diagnosed with non-insulin-dependent diabetes mellitus (NIDDM) one year prior and the condition was well-controlled with use of metformin 500 mg twice daily. He had no new ocular or visual complaints. His best-corrected visual acuity was 20/20 OD (+1.25 sph) and 20/20 OS (+1.00 sph). No relative afferent pupillary defect was noted. Preliminary testing and anterior segment evaluation were both unremarkable OU.

During fundus examination of the left eye, a large segment of elevation was noted in the nasal portion of the posterior pole. The margins of this elevation were distinct and extended into the periphery. Binocular indirect ophthalmoscopy revealed an elevated, smooth dome of retinal tissue nasally from 7 to 11 o'clock (approximately 12-15 disc diameters) extending to the ora serrata. There was visible separation between the retinal layers, but scleral indentation revealed no obvious break or hole.

Upon further questioning, the patient admitted that he had a black spot on the side of his vision for the “past few weeks,” but assumed it was “just a floater.” Based on the examination findings, the patient was diagnosed with having 12-15 disc diameters of symptomatic reticular retinoschisis of unknown duration. A retinal consult was arranged, and the general ophthalmology staff offered the patient the next available appointment. Three weeks later, he called the clinic to report that his vision had significantly worsened and objects out of his left eye appeared to have a yellow tinge. The patient was directed to the emergency room where he could be examined by the on-call resident ophthalmologist.

The resident saw the patient that same day. Examination of the left eye showed Snellen visual acuity of 20/400 and a relative afferent pupillary defect secondary to a large, macula-off, retinal detachment. The patient was sent to the Brooke Army Medical Center for surgery the next morning. The patient underwent a pars plana vitrectomy with scleral buckle repair for the retinal detachment of the left eye. Best-corrected visual acuity stabilized around 20/80 six months after

surgery. The patient continues to be followed yearly by the retina service to monitor for change.

### **Educational Guidelines**

#### *Key concepts*

1. Recognize the clinical differences between the subtypes of acquired retinoschisis
2. Understand the importance of taking a good history
3. Be familiar with different types of ancillary testing to aid in diagnosis and management of the condition
4. Be aware of management options for all subtypes of retinoschisis
5. Be able to properly educate patients regarding diagnosis and prognosis of the condition

#### *Learning objectives*

At the conclusion of this case discussion, participants should be able to:

1. Recognize all types of retinoschisis from an anatomic standpoint
2. Identify major classifications of retinoschisis from a retinal detachment
3. Understand the typical patient demographic for both X-linked and acquired retinoschisis
4. Understand the risk factors in association with the clinical presentation to best manage the patient, including if/when referral is appropriate
5. Provide patient education regarding all management options and expectations for those options
6. Understand that treatment with oral or topical carbonic anhydrase inhibitors for foveoschisis have similar visual outcomes but varied side effects
7. Understand treatment options in cases of peripheral retinoschisis
8. Understand intravenous fluorescein angiography (IVFA) results in XLRS.

#### *Discussion questions*

1. Knowledge and concepts required for critical review of the case
  - a. What are the typical clinical characteristics of peripheral retinoschisis?
  - b. What are the typical clinical characteristics of X-linked retinoschisis?
  - c. How can one distinguish retinoschisis from other peripheral retinal conditions?
  - d. What would be the most appropriate management given the case provided?
2. Differential diagnoses
  - a. What differential diagnoses make the most sense, given the clinical characteristics?
  - b. What other factors need to be considered in this case?
  - c. Are there any ancillary tests that would have been helpful in this diagnosis?
3. Disease management
  - a. How would you monitor this patient, if at all?
  - b. What timeline is most appropriate for this patient?
4. Patient education
  - a. How would you educate the patient regarding this diagnosis?
  - b. What is the long-term prognosis for this patient?
  - c. How would you discuss visual outcomes with or without treatment?

## 5. Critical thinking

- How would you have managed this case?
- Do you feel more prepared to manage or co-manage this condition?

### Learning assessment

- Facilitate case discussion to achieve learning objectives
- Knowledge base can be evaluated by comparing optical coherence tomography (OCT) scans and fundus photographs with case history
- Knowledge base of the condition can be assessed by student presentations of differential diagnoses
- Clinical thinking skills can be evaluated by case reports that are from a review of literature or hypothetical examples

## Discussion

Retinoschisis is defined as splitting of the neurosensory retinal components.<sup>1-3</sup> Retinoschisis can be large or small, flat or elevated (bullous), symptomatic or asymptomatic, central or peripheral, unilateral or bilateral, progressive or nonprogressive.<sup>2-4</sup> Acquired retinoschisis and XLRS are two major types discussed in the scientific literature. Acquired retinoschisis is most commonly peripheral, unilateral, asymptomatic, and present in an older demographic. XLRS is usually bilateral, central, symptomatic, and present in a younger male demographic (**Table 1**). Other forms of retinoschisis are myopic macular retinoschisis and tractional retinoschisis. Myopic macular retinoschisis (also known as myopic traction maculopathy or myopic foveoschisis) is a complication from high myopia. A posterior staphyloma is commonly associated with this type of retinoschisis.<sup>5</sup> Tractional retinoschisis can occur in vitreomacular traction syndrome or proliferative diabetic retinopathy.<sup>6</sup> The combination of clinical findings and patient symptoms determines the diagnosis, prognosis and management of the condition.

XLRS is a rare condition that can show characteristics at birth, but some children go years without a diagnosis. The clinical sign of XLRS is foveoschisis, which is retinoschisis that affects the fovea. This condition typically presents bilaterally but can be asymmetric. XLRS patients have reduced vision ranging from 20/40 to no light perception, depending on the type of mutation, location of the retinoschisis, and chronicity of relapses. As with all X-linked disorders, XLRS disproportionately affects males. The prevalence of XLRS is 1:5,000-25,000 males.<sup>7-11</sup> Patients with XLRS can also independently develop acquired retinoschisis. Family history may or may not be helpful in assessing risk of development. Table 1 outlines differences between acquired retinoschisis and XLRS.

**TABLE 1**  
Differences Between Acquired Retinoschisis and X-linked Retinoschisis

	XLRS	Acquired
Visual Acuity	20/40 - NLP	20/20
Laterality	Bilateral	Unilateral > Bilateral
Location	Fovea	Outside of Fovea
Gender Predilection	Male	Either
Age of Onset	Early	Late

NLP = no light perception; XLRS = X-linked retinoschisis

**Table 1. [Click to enlarge](#)**

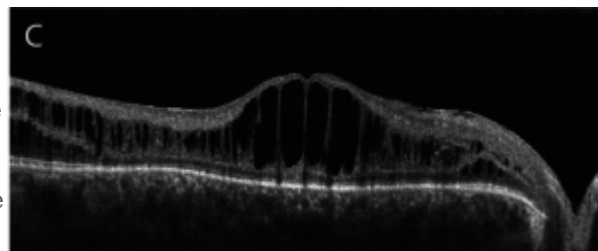
The repulsion of foveal components in XLRS has been studied in great depth.<sup>12</sup> The gene involved with this foveal pathology is the retinoschisin gene, or RS1.<sup>7,12-15</sup> Due to incomplete penetrance and expressivity of RS1, the clinical presentation of XLRS varies greatly. Gel electrophoresis, velocity sedimentation and mass spectrometry show that RS1 is a protein comprised of eight subunits, held together by disulfide bonds.<sup>15</sup> The proteins made by the RS1 gene aid in retinal cell adhesion, help with cellular organization within the retina, act as an osmotic buffer between inner and outer cellular fluids, and provide general structural support.<sup>12,13</sup> One of the most notable subunits is the discoidin domain, which helps adjust water balance between the intracellular and extracellular environment utilizing sodium/potassium ATPase. The lack of a functional discoidin domain may lead to fluid accumulation extracellularly, causing a divide between retinal layers and creating the potential for retinoschisis.<sup>13,15,16</sup>

In humans, retinoschisin has been found on the extracellular surfaces of the inner segments of rod and cone photoreceptors, bipolar cells, outer nuclear layer, and both inner and outer plexiform layers. Due to the wide distribution of the retinoschisin protein, any level of the retina can be affected.<sup>13,15</sup>

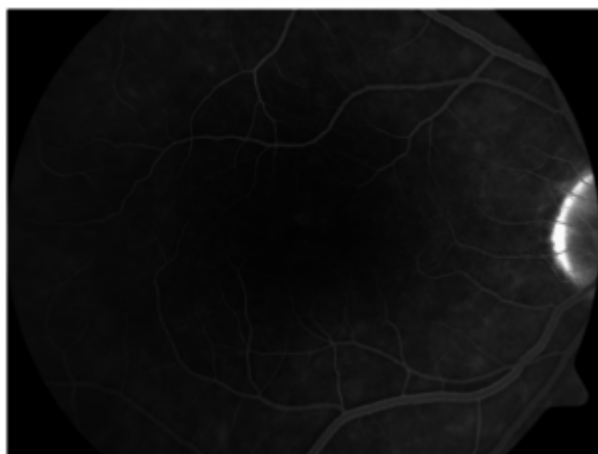


XLRS causes a significant visual disturbance due to its presence within the fovea. Cystoid macular edema (CME) is visible with OCT.<sup>7,17</sup> The CME has an atypical OCT appearance, as it involves retinoschisis with vertically elongated columns of stretched middle anatomy (**Figure 1**).<sup>18</sup> Performing IVFA can further differentiate this retinoschisis from other cases of CME, as the cystoid intraretinal spaces in XLRS do not leak or stain (**Figure 2**).<sup>16,18</sup> The cystoid spaces can be seen with indocyanine green (ICG) angiography.<sup>18</sup>

It has been reported in the scientific literature that treating with a topical or oral carbonic anhydrase inhibitor (CAI) can decrease the size of the cysts and potentially increase visual acuity.<sup>17</sup> Topical dorzolamide 2% ophthalmic solution (Trusopt, Merck) is dosed three times daily in the affected eye. Oral acetazolamide (Diamox, Duramed Pharmaceuticals) is taken as 125 mg twice daily. Dosing duration varies depending on how responsive the eye is to treatment. The exact mechanism of action of CAIs in retinoschisis is unknown, but CAIs are known to effect fluid transportation through the manipulation of bicarbonate ions to reduce intraocular pressure. It has been postulated that CAIs have similar effects within the macula. It has also been proposed that CAIs cause vascular dilation and increased blood flow by increasing tissue carbon dioxide concentrations and/or lowering tissue pH, leading to a more normal macular architecture.<sup>8,17,19</sup>



**Figure 1.** Atypical appearance on optical coherence tomography of cystoid macular edema in X-linked retinoschisis.<sup>18</sup> [Click to enlarge](#)



**Figure 2.** Absence of petaloid leakage on intravenous fluorescein angiography in X-linked retinoschisis.<sup>18</sup>

[Click to enlarge](#)

A maintenance dose of 62.5 mg Diamox taken by mouth, or once daily/twice daily dosing of Trusopt in the affected eye have been shown to help decrease XLRS relapses. Unfortunately, relapses are still quite common even with chronic CAI use.<sup>3,17</sup> Topical CAIs greatly reduce systemic absorption and are the preferred treatment of CME in XLRS. Although treatment with oral CAIs has been shown to produce equal visual acuity outcomes, it is associated with a significantly greater side-effect profile when compared with topical treatment.<sup>8,17,19</sup>

Acute onset macular edema is more responsive to treatment than chronic edema. The longer the edema is present, the more difficult it is to recover proper anatomic orientation, which decreases the likelihood of a good visual outcome. In cases of chronic foveoschisis, granular retinal pigment mottling is often seen, and in some instances is described as being wheel/spoke-like in nature.<sup>11</sup>

Both acquired retinoschisis and XLRS involve splitting of neurosensory retina; however, the mechanism that causes the split is vastly different. Research has been done to determine the impact of the retinoschisin gene on acquired retinoschisis. Interestingly enough, acquired retinoschisis does not occur because of any mutations in the RS1 gene. Research has not determined how or why acquired retinoschisis occurs.<sup>7,12</sup>

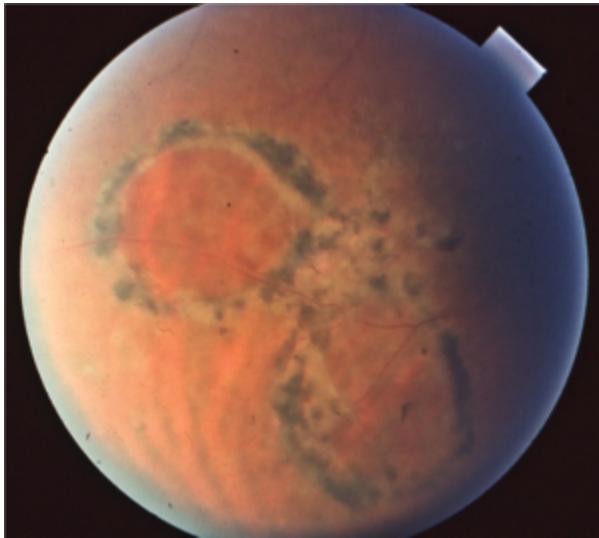
Previously, it was thought that typical retinoschisis created retinal splitting in the outer plexiform layer, while reticular retinoschisis and XLRS both created a split in the nerve fiber layer. While these are still common locations for each, OCT has shown that retinal splitting can occur between other layers as well.<sup>3,13</sup>

The most common type of retinoschisis is acquired retinoschisis. Acquired retinoschisis is usually benign and non-progressive. It is idiopathic, sporadic, usually less impactful upon vision, and most often affects the peripheral retina.<sup>1,10,12,14</sup>



Patients are typically asymptomatic despite the retinoschisis causing a true and absolute visual field defect. If a patient is symptomatic, the situation needs to be taken seriously.

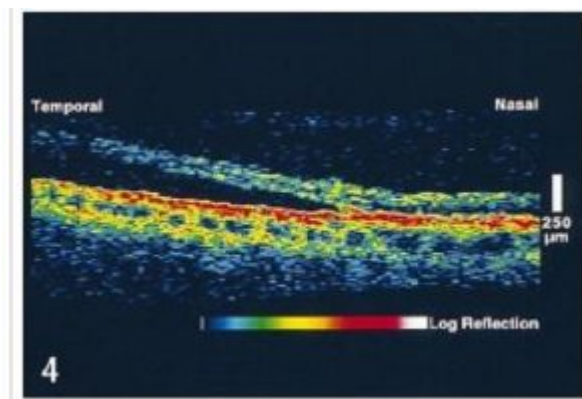
Acquired retinoschisis is further divided into reticular or typical retinoschisis.<sup>1</sup> Reticular (bullous) retinoschisis produces elevation due to the presence of fluid between the neurosensory layers, which poses a higher risk of progression and potential complications. Typical retinoschisis tends to have a flatter appearance due to less fluid accumulation.<sup>1</sup>



**Figure 3.** Chronic outer wall breaks with pigmented cuffs.<sup>21</sup> [Click to enlarge](#)

Acquired retinoschisis tends to emerge later in life, but cases of younger adults and children with this presentation have been seen. It most commonly affects peripheral inferotemporal retina, although reticular retinoschisis is seen in the nasal retina more frequently than typical retinoschisis.<sup>1</sup> Approximately 1% of all eyes have acquired retinoschisis, which shows bilaterality in 33% of those patients.<sup>3</sup> Myopic patients are more likely to be progressive than hyperopic patients and there is no gender predilection.<sup>2,3</sup> Neither cataract surgery nor posterior vitreous detachments have been shown to worsen retinoschisis.<sup>21</sup>

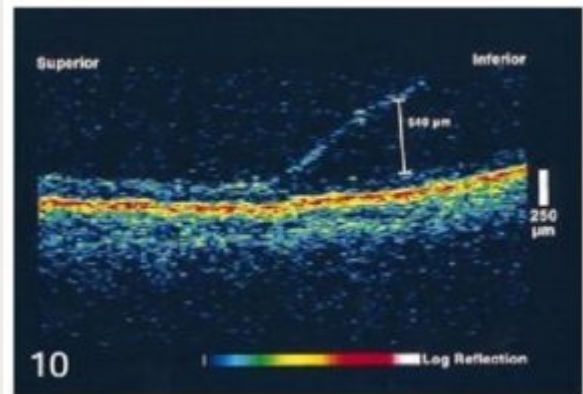
There can be outer or inner wall breaks within the acquired retinoschisis.<sup>20</sup> Outer wall breaks are usually larger and occur in up to 25% of all acquired retinoschisis cases. Outer wall breaks can have a characteristic ring of pigmentation surrounding the hole, which denotes chronicity (**Figure 3**).<sup>20,22</sup> Inner wall breaks (chronic or acute) tend to be significantly smaller and have been described as mimicking the appearance of an atrophic hole.<sup>21</sup> The presence of a hole (in either the inner or outer segment) is more strongly considered for surgical intervention, as retinal detachments are more common with either presentation.<sup>1,3,21</sup> However, when there are no inner or outer retinal wall holes, reticular retinoschisis is typically benign and non-progressive and is commonly monitored.<sup>2</sup>



**Figure 4.** Retinal detachment.<sup>20</sup> [Click to enlarge](#)

Clinicians must be able to distinguish between a retinal detachment and peripheral retinoschisis using anatomical differences observed during fundoscopic examination. Retinoschisis tends to be more translucent with visible vasculature, less flexible with well-demarcated borders, and have an overall smoother appearance than a retinal detachment. To complicate matters, a longer-standing retinal detachment can exhibit demarcation lines and retinal pigment epithelium (RPE) alterations, similar to how some retinoschisis cases present. Furthermore, a patient can present with a combination of retinoschisis and detachment.<sup>22</sup> A true detachment will have complete separation of neurosensory retina from underlying RPE with associated atrophy of the RPE.<sup>20,21,23</sup> The advent of OCT has greatly improved the accuracy of diagnosis, as the photoreceptor integrity line is relatively easy to locate. **Figure 4** shows a true retinal detachment, as the whole sensory retina is disconnected from the RPE.<sup>20</sup> **Figure 5** shows retinoschisis, as the RPE is still attached to outer retina, with the detachment located between the neurosensory retinal components.<sup>20</sup>

Acquired retinoschisis most commonly occurs in peripheral retina, creating limitations to imaging with OCT. However, there is evidence of some success performing peripheral OCT through a modified slit lamp with a three-mirror contact lens, 78D lens and/or Heidelberg Spectralis ultra-widefield module lens.<sup>22,23</sup> Scleral indentation (with or without B-scan echography) can also help differentiate between a retinoschisis and a retinal detachment.<sup>18</sup> Scleral indentation will flatten areas of a true retinal detachment, but will not flatten a retinoschisis. However, highly bullous retinal detachments do not flatten, even with forceful indentation.<sup>20,22</sup> Similarly, a B-scan (with indentation) will show a decrease in the space between the retina and sclera in a true detachment but not with a retinoschisis. Performing a Humphrey Visual Field test can also be helpful.<sup>22</sup> An absolute, irreversible defect will be seen in retinoschisis, while a relative defect may be seen in retinal detachment.<sup>21,22</sup> In 1964, Okun and Cibis published an article describing how laser photocoagulation could be used to distinguish between these conditions, as it would cause a blanching effect on the retina in acquired retinoschisis but not in retinal detachment. These findings have since been refuted.<sup>20,22</sup>



**Figure 5.** Retinoschisis: detachment between neurosensory layers with outer retina still attached to retinal pigment epithelium.<sup>20</sup> [Click to enlarge](#)

The efficacy of prophylactic laser barricade is debated.<sup>2-4,21</sup> Options may include panretinal photocoagulation, argon laser treatment or retinal cryopexy. Drainage of the retinoschisis cavity is commonly done with laser demarcation treatments to help collapse the retinal layers in an attempt to achieve as close to a normal retinal contour as possible. This prophylactic treatment will not re-establish the neuronal integrity of the split retina; therefore, it does not reverse the absolute visual field defect caused by acquired retinoschisis.<sup>24</sup> The goal is to help prevent a retinal detachment by creating a laser-induced chorioretinal scar around the affected area of retina.

Even after prophylactic treatment, progression may occur.<sup>21</sup> Literature suggests that acquired retinoschisis progresses to a more serious retinal concern in about 15% of cases.<sup>1,3</sup> If retinoschisis does progress to a retinal detachment, it is difficult to repair.<sup>2-4,21,24</sup> Clinical presentation of the detachment determines which type of retinal procedure is pursued, but a scleral buckle, and/or pars plana vitrectomy are most commonly performed. Up to 40% require a second surgical repair.<sup>21,24</sup>

Retinoschisis can present with a myriad of symptoms or none at all. The fundusoscopic examination is an important element in achieving the appropriate diagnosis. In the case reported here, the patient's history, the unknown timeline and the dilated examination were considered for the most accurate diagnosis and appropriate management. The patient presented with a new "floater" in his peripheral vision, without central vision being affected. A dilated examination revealed a large reticular retinoschisis affecting the nasal retina that was first observed with a 78D lens. A referral was warranted given the features of this symptomatic retinoschisis.

Doctors have different levels of comfort with diagnosing and managing acquired retinoschisis, but typically if no inner or outer wall holes are present, and the patient is asymptomatic, it is appropriate to monitor the condition. It is imperative that the clinician stresses the importance of follow-up visits. The patient must understand the severity of the condition and should return to the clinic with any change in or worsening of symptoms. A retinal consult is always an option should any of the conditions negatively change.

## Conclusion

Over the past two decades, there have been extensive advancements in the understanding of all types of retinoschisis at the clinical, molecular, genetic and cellular level. Even with these developments, there is still more to be discovered. The clinical presentation of this patient and understanding of retinal anatomy is what prompted the referral. Patients who are not managed appropriately are at risk for permanent vision loss. Therefore, it is important that optometrists be well-versed in the newest treatments and theories surrounding this pathology.

## References

1. Onofrey B, Skorin L, Holdeman N. Ocular Therapeutics Handbook. A Clinical Manual. Philadelphia, PA. Lippincott-Raven Publishers; Third edition. 2011.

2. Byer N. Perspectives on the management of the complications of senile retinoschisis. *Eye (Lond)*. 2002 Jul;16(4):359-64.
3. Ambler JS, Gutman FA. Retinal detachment and retinoschisis. *Ophthalmology*. 1991 Jan;98(1):1.
4. Yassur Y, Feldberg R, Axer-Siegel R, Silverston B, Manor R, Ben-Sira I. Argon laser treatment of senile retinoschisis. *Br J Ophthalmol*. 1983;67:381-384.
5. Benhamou N, Massin P, Haouchine B, Erginay A, Gaudric A. Macular retinoschisis in highly myopic eyes. *Am J Ophthalmol*. 2002 Jun;133(6):794-800.
6. Faulborn J, Ardjomand N. Tractional retinoschisis in proliferative diabetic retinopathy: a histopathological study. *Graefes Arch Clin Exp Ophthalmol*. 2000 Jan;238(1):40-44.
7. Vijayasarathy C, Sui R, Zeng Y, et al. Molecular mechanisms leading to null-protein product from retinoschisin signal-sequence mutants in X-linked retinoschisis disease. *Hum Mutat*. 2010 Nov;31(11):1251-1260.
8. Walia S, Fishman G, Molday R, et al. Relation of response to treatment with dorzolamide in X-linked retinoschisis to the mechanism of functional loss in retinoschisin. *Am J Ophthalmol*. 2009 Jan;147(1):111-115.e1.
9. Liu M, Tuo J, Chan C. Gene therapy for ocular diseases. *Postgrad Med J*. 2011 July; 87(1029):487-495.
10. Sikkink SK, Biswas S, Parry NR, Stanga PE, Trump D. X-linked retinoschisis: an update. *J Med Genet*. 2007 April;44(4):225-232.
11. Kjellstrom S, Vihasarathy C, Ponjavic V, Sieving P, Andreasson S. Long-term 12 year follow-up of X-linked congenital retinoschisis. *Ophthalmic Genet*. 2010 September;31(3):114-125.
12. Vijayasarathy C, Ziccardi L, Zeng Y, Smaoui N, Caruso R, Sieving P. Null retinoschisis-protein expression from an RS1 c354del1-ins18 mutation causes progressive and severe XLRA in a cross-sectional family study. *Invest Ophthalmol Vis Sci*. 2009 Nov;50(11):5375-5383.
13. Wu W, Wong J, Kast J, Molday R. RS1, a discoidin domain-containing retinal cell adhesion protein associated with X-linked retinoschisis, exists as a novel disulfide-linked octamer. *J Biol Chem*. 2005 March 18;280(11):10721-10730.
14. Gehrig A, White K, Lorenz B, Andrassi M, Clemens S, Weber B. Assessment of RS1 in X-linked juvenile retinoschisis and sporadic senile retinoschisis. *Clin Genet*. 1999 Jun;55(6):461-465.
15. Wu W, Molday R. Defective discoidin domain structure, subunit assembly, and endoplasmic reticulum processing of retinoschisin are primary mechanisms responsible for X-linked retinoschisis. *J Biol Chem*. 2003 Jul 25;278(30):28139-46. Epub 2003 May 13.
16. Gaucher D, Saleh M, Sauer A, Speeg-Schatz C, Bourcier T, Gaudric A. "Macular edema without fluorescein leakage. *J Fr Ophthalmol*. 2009 May;32(5):314-9. Epub 2009 Apr 10.
17. Kaur I, Smitha R, Aggarwal D, Kapil M. Acetazolamide: future perspectives in topical glaucoma therapeutics. *Int J Pharm*. 2002 Nov 6;248(1-2):1-14.
18. Ansari W, Browne A, Singh R. Juvenile X-linked retinoschisis responsive to intravitreal corticosteroids. *Am J Ophthalmol Case Reports*. Vol 5 (2017 Apr):48-51.
19. Iannaccone A, Fung KH, Eyestone ME, Stone EM. Treatment of adult-onset macular retinoschisis in enhanced s-one syndrome with oral acetazolamide. *Am J Ophthalmol*. 2009 Feb;147(2):307-312.e2.
20. Ip M, Garza-Karren C, Duker JS, et al. Differentiation of degenerative retinoschisis from retinal detachment using optical coherence tomography. *Ophthalmology*. 1999 Mar;106(3):600-5.
21. Reed D, Gupta O, Garg S. Managing complications of retinoschisis. *Retina Today*. 2014 November/December:32-39.
22. Ho V, Wehmeier J, Shah G. Wide-field infrared imaging: a descriptive review of characteristics of retinoschisis, retinal detachment, and schisis detachments. *Retina*. 2016 Aug;36(8):1439-1445.
23. Stehouwer M, Tan SH, van Leeuwen TG, Verbraak FD. Senile retinoschisis versus retinal detachment, the additional

value of peripheral retinal OCT scans (SL SCAN-1, Topcon). Acta Ophthalmol. 2014 May;92(3):221-7. Doi:

10.1111/aos.12121. Epub 2013 June 15.

24. Gotzaridis E, Georgalagas I, Petrou P, Assi A, Sullivan P. Surgical treatment of retinal detachment associated with degenerative retinoschisis. Semin Ophthalmol. 2014 May;29(3):136-141.



Dr. Alberts [[Megan.Alberts@va.gov](mailto:Megan.Alberts@va.gov)] completed an ocular disease/low vision residency at the Marion Veterans Affairs Medical Center (VAMC) in Illinois from 2010-2011. Subsequently, she worked at the San Antonio VAMC in Kerrville, Texas, for four years before transferring back to the Marion VAMC. She currently works at the Evansville Health Care Center in Indiana, which is a branch of the Marion VAMC.

Dr. Sutter is a 2014 graduate of the Illinois College of Optometry where she earned clinical distinction. She completed an ocular disease/low vision residency at the Marion VAMC in Illinois from 2014-2015. Dr. Sutter now serves the veteran population at the Evansville Health Care Center in Indiana.

Dr. Payne is a 2016 graduate of the Indiana University School of Optometry. She is certified in expanded therapeutic laser procedures and the use of injection procedures. She is experienced with orthokeratology contact lenses. Dr. Payne practices privately in the Evansville, Ind., area with emphasis in contact lenses.

## VIRTUAL PATIENT INSTRUCTION AND SELF-ASSESSMENT ACCURACY IN OPTOMETRY STUDENTS

### Abstract

*We tested the hypotheses that virtual patient instruction aimed at developing clinical decision-making skills in second-year optometry students in the United Kingdom (UK), is (1) associated with improved self-assessment accuracy, and (2) that this occurs regardless of academic ability, gender or learning style. Self-assessment accuracy, the difference between perceived mastery (questionnaire) and actual mastery (multiple-choice examination), was determined for five learning objectives: question selection, critical symptom recognition, test selection, critical sign recognition and referral urgency. Virtual patient instruction was not associated with improved self-assessment accuracy, which was generally poor across all learning objectives. There was evidence of over-estimated self-assessment in students, especially males, with poorer academic performance. Opportunities for optometry students to develop self-assessment skills should start early in the academic program and be reinforced throughout the entire curriculum.*

**Key Words:** self-assessment accuracy, clinical decision-making, virtual patient, academic ability, gender, learning style

### Introduction

Decision-making in a clinical context is defined as “making choices between alternatives in order to decide what procedures to do, to make a diagnosis, or to decide what treatments to prescribe.”<sup>1</sup> We developed a virtual patient software to teach these skills to second-year optometry students at Aston University. This software was inspired by Pane and Simcock’s textbook “Practical Ophthalmology: a Survival Guide for Doctors and Optometrists,” which promotes a symptom-based approach.<sup>2</sup> The intended learning objectives are shown in **Table 1**.

**TABLE 1**  
Learning Objectives

1. QUESTION SELECTION: the ability to ask the right questions in History and Symptoms based on a patient's presenting complaint
2. CRITICAL SYMPTOM RECOGNITION: the ability to recognize symptoms of serious eye disease
3. TEST SELECTION: the ability to select the most appropriate tests to look for signs that aid differential diagnosis
4. CRITICAL SIGN RECOGNITION: the ability to recognize signs of serious eye disease
5. REFERRAL URGENCY SELECTION: the ability to decide upon the most appropriate referral urgency for any eye disease detected

**Table 1.** [Click to enlarge](#)

Clinical instructors are required to assess students’ clinical decision-making skills. This often takes place in training clinics where clinical instructors supervise groups of students. Group supervision makes it difficult, even when eye examinations are recorded on video, to provide timely feedback on every clinical procedure carried out by each student. Using virtual patient software, which automatically records every student decision via the keyboard and mouse, students can obtain immediate and consistent formative and summative feedback. Previous research has shown that assessments made by clinical supervisors can be inconsistent because assessment criteria can vary between supervisors, and the grades given by individual supervisors can vary on different occasions.<sup>3</sup> Virtual patient software overcomes this by operating via consistent grading criteria. Thus, virtual patient instruction has the advantage of allowing unlimited risk-free and self-paced opportunities to apply clinical decision-making skills. In addition, virtual patient software can be programmed to simulate any desired eye condition, ensuring that students are exposed to an ample variety of pathologies during their training.

Accurate self-assessment can be an indicator of student ability to understand their own strengths and weaknesses and to recognize areas in which further practice is required to achieve mastery. In this regard, we believe that teaching methods should be designed to promote accurate self-assessment regardless of learning style, academic ability or gender. In this study, we evaluated whether virtual patient instruction was associated with student variations in self-assessment accuracy regarding specific elements of clinical decision-making skills. In the context of the study, self-assessment accuracy refers to how well a student’s perceived confidence in his or her mastery of the learning objectives listed in Table 1 reflects actual mastery. Self-assessment accuracy has been studied in students of various disciplines,<sup>4-9</sup> including optometry,<sup>5</sup> and some evidence that it is influenced by learning styles,<sup>6</sup> academic ability<sup>6,7</sup> and gender has been presented.<sup>8,9</sup> However, the effect of virtual patient instruction on the accuracy of self-assessment of clinical skills remains largely unknown.

In this study, for all learning objectives shown in Table 1, we tested the following hypotheses:



1. Better self-assessment accuracy occurs with virtual patient instruction because it facilitates unlimited practice and exposure to feedback that encourages students to re-evaluate their perceived skills
2. Self-paced virtual patient instruction gives all students an equal opportunity to improve self-assessment independently of student learning style, gender and academic ability

## **Methods**

### *Ethics*

This study adhered to the tenets of the Declaration of Helsinki and was approved by Aston University's Research Ethics Committee. Voluntary informed consent was obtained from all participants before any data were analysed.

### *Study design*

Two cohorts of second-year optometry students participated in the study. The first cohort entered the course the year before the second cohort. Both cohorts received the same course content in which 22 types of presentation were covered: 10 presenting symptoms, such as vision loss and diplopia, and 12 presenting signs, such as eyelid spasm and anisocoria. These presentations covered more than 100 eye conditions.

For the first cohort (no virtual patient instruction; control group) classes were organized into nine two-week blocks in which students (a) received a didactic lecture, (b) applied what they had been taught over a period of one week by completing an online quiz, and (c) attended a class tutorial to discuss the same cases (constituting formative assessment). The online quiz aimed to evaluate students' ability to determine the most likely diagnosis and referral urgency of three cases (for which immediate summative assessment was given). As time did not allow for 22 teaching blocks, corresponding to the 22 types of presentations, some of the nine blocks covered just one symptom or sign whereas others grouped several symptoms or signs into one block. The structure of each didactic lecture led students systematically through the five learning objectives.

For the second cohort (virtual patient instruction; intervention group) classes were organized into 20 one-week blocks in which students (a) received a tutorial covering the virtual patient "at a glance" guides, and (b) had unlimited practice on the virtual patient over a period of one week, in preparation for (c) online virtual patient assessments. This allowed enough time for all teaching blocks to cover just one symptom or sign except for two of the teaching blocks, which covered two presenting signs each.

The virtual patient was designed to provide a more interactive environment that matched, as closely as possible, the "natural flow" of an eye examination. Students were required to choose questions to ask based on the patient's chief complaint, and to choose clinical tests to look for signs that would lead them to the most likely diagnosis and appropriate referral urgency. The virtual patient responded to questions and revealed symptoms and signs in the form of text and images. All findings were available for review in a virtual eye examination record. At the end of the examination, the virtual tutor provided formative feedback on every decision entered by the student, via the keyboard or mouse. Summative feedback was also provided based on the chosen questions, tests, diagnosis and urgency. Points were discounted for incorrect procedures such as failure to carry out pre- and post-dilation checks or attempting to look for a sign before selecting the required test.

During the unlimited practice sessions, students in the second cohort could switch the virtual patient to teaching mode. Here, the virtual tutor showed the "at a glance" approach guides mentioned above before directing students through each step and demonstrating how this altered the list of differential diagnoses. The virtual tutor also presented "pop-up" messages explaining the significance of any critical symptoms and signs. The intention here was for students to acquire background knowledge and clinical reasoning more as an apprentice does when observing a master than a scholar would do when reading a book. Students were able to choose a specific case or have one randomly selected from the database.

### *Participants*

Second-year UK optometry students, most of whom had entered the program directly from high school, participated in this study. The first year of the degree program covers basic sciences including ocular biology, geometric optics and basic clinical techniques. Pre-clinical skills are developed during the second year, mainly on fellow students, and include the eye examination, contact lenses and advanced clinical techniques. Clinical practice dominates the third year and involves direct patient care at various clinics such as primary care, contact lenses, spectacle dispensing, binocular vision, low vision and ophthalmology. After graduation, students enter a pre-registration training program that lasts approximately a year.



This postgraduate training is spent under the supervision of a qualified optometrist either in private practice or a hospital setting. During this last part of their training, graduates are required to pass further assessments to become registered as qualified optometrists.

The first study cohort (no virtual patient instruction; control group) consisted of 102 students (62 females and 40 males). The second cohort (virtual patient instruction; intervention group) consisted of 93 students (64 females and 29 males). All students in the classes to which both cohorts belonged were invited to participate (118 students in the first cohort; 120 students in the second cohort) but some refused consent (16% of the first cohort; 22.5% of the second cohort).

### Perceived mastery

Perceived mastery was a self-assessed measure of the students' own perception of their confidence in the five learning objectives (Table 1). Previous literature has referred to this as "self-efficacy."<sup>10</sup> A questionnaire was released two weeks before the end of the academic year with a one-week deadline. The questionnaire (Table 2) contained items that corresponded directly to the five learning objectives. Students responded to each question using a five-level Likert score, which was converted to a percentage such that 0% corresponded to a Likert score of 1 ("strongly disagree") and 100% to a score of 5 ("strongly agree").

**TABLE 2**  
Perceived Mastery Questionnaire

1.	I am very confident in my ability to ask the right questions in History and Symptoms based on a patient's presenting complaint
2.	I am very confident in my ability to recognize symptoms of serious eye disease
3.	I am very confident in my ability to select the most appropriate tests needed to look for signs that aid differential diagnosis
4.	I am very confident in my ability to recognize signs of serious eye disease
5.	I am very confident in my ability to decide upon the most appropriate referral urgency for any eye disease detected

Table 2. [Click to enlarge](#)

### Actual mastery

Following previous research,<sup>1</sup> actual mastery was determined using end of year multiple-choice examinations. Both student cohorts were assessed by means of identical multiple-choice examinations. Aston University's rules require that a proportion of multiple-choice examinations are altered each year. This was adhered to but still allowed for 25 multiple-choice questions, five per learning objective, to remain unchanged between both examinations. Example questions are shown in Table 3, one for each learning objective. Actual mastery scores represented the percentage of the five questions correctly answered for each learning objective.

**TABLE 3**  
Examples of the Multiple-Choice Questions Used to Measure Actual Mastery

Objective 1: Which question is LEAST LIKELY to be useful when investigating floaters or flashes?
a) is this in one or both eyes?
b) <b>do you experience pain with eye movements?</b>
c) do you have diabetes?
d) have you had cataract surgery?
e) have you ever suffered from migraine?
Objective 2: Which is LEAST LIKELY to indicate a sinister headache?
a) <b>chronic daily headache</b>
b) onset within last 6 months
c) very young or elderly patient
d) atypical headache
e) high blood pressure
Objective 3: Examination of which is LEAST LIKELY to be useful when investigating a complaint of pain in or around the eyes?
a) eyelid
b) <b>mobility</b>
c) <b>retinal blood vessels</b>
d) optic nerve
e) pupil
Objective 4: Which sign is MOST LIKELY to indicate raised intracranial pressure?
a) bilateral crowded optic disc
b) unilateral optic disc cupping
c) <b>bilateral optic disc swelling</b>
d) unilateral optic atrophy
e) bilateral optic disc drusen
Objective 5: Which requires the HIGHEST referral urgency?
a) anisocoria in which one eye has keratic precipitates
b) anisocoria that is likely to be due to Adie's pupil
c) anisocoria with head and neck pain
d) <b>anisocoria in which one eye is red with a hazy cornea and an oval pupil</b>
e) anisocoria with heterochromia

Table 3. [Click to enlarge](#)

### Self-assessment accuracy

Self-assessment accuracy was initially determined by subtracting the actual mastery percentage from the perceived mastery percentage.<sup>12</sup> Self-assessment accuracy was then classified into three groups: over-estimation, for percentage differences greater than zero; under-estimation, for percentage differences less than zero; and accurate, for percentage differences equal to zero.

### Academic ability

Academic ability was based on the average grade achieved by each student across all second-year modules in sessional examinations performed at the end of the academic year.<sup>13</sup> Academic grading in the UK is typically defined as follows: first class (score of 70-100%); upper second class (60-69%); lower second class (50-59%); and third class (40-49% score). A score below 40% is considered a failing grade. Students must achieve a lower second class grade or higher to progress onto the pre-registration program. All students participating in this study were in the tier of first class, upper second class or lower second class.

### Learning style

During the first half of the course, all students completed the established Index of Learning Styles questionnaire.<sup>13</sup> Students were initially classified along the four learning style dimensions: active-reflective, sensing-intuitive, visual-verbal and sequential-global. The four dimensions were then combined so that each student was re-classified as falling into one of

16 possible learning style profiles.<sup>13</sup>

### Statistical analyses

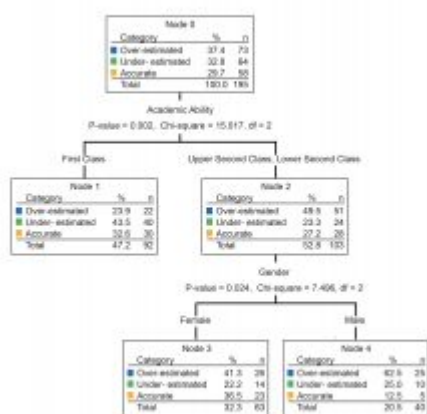
Decision trees, a form of multivariate analysis, were generated using SPSS 21.0 (IBM SPSS Statistics) and findings were tested for statistical significance at the 95% level ( $P < 0.05$ ). Multivariate analyses eliminate confounding by accounting for all variables at once. Decision trees adopt a hierarchical output, where independent variables (i.e., virtual patient tuition, academic ability, gender and learning style) are shown in order of the strength of their association with the dependent variable (i.e., self-assessment accuracy). The most and least influential variables appear at the top and bottom of the trees, respectively. Branches only form for statistically significant associations.

The Chi-squared automatic interaction detection (CHAID) tree-growing method was adopted. Other researchers in the field of optometry have reported using the same method.<sup>14</sup> Our study variables were categorical; therefore, Chi-square was used as the splitting criteria for generating decision-tree branches, and Bonferroni adjustments were applied to p-values to account for multiple tests. Decision trees consist of parent nodes that branch into child nodes. In our study, the minimum sample size for parent and child nodes was set at 30 and 15, respectively. By default, SPSS sets the maximum tree branching levels to three. We increased this to five (one more than the number of independent variables) to ensure maximum tree growth was achieved.

We made power calculations using GPower (version 3.1.0.).<sup>15</sup> In our case, because any changes to teaching would require significant resources, we argue that it would only be justifiable to base changes on statistically significant findings for large effects. The highest degrees of freedom (df) required in our study was 30, i.e., 1 minus 3 levels of self-assessment accuracy (over-estimated, accurate and under-estimated) multiplied by 1 minus 16 learning style profiles ( $2 \times 15 = 30$  df). We calculated that a total sample of 99 students was required to enable Chi-square tests with 30 df to detect statistically significant large size effects at the 95% level of statistical significance with 80% power, a conventionally acceptable power.<sup>16-17</sup> Our total sample of 195 students far exceeded this.

### Results

The decision trees in **Figures 1 through 4** show which of the independent variables (i.e., student cohort, academic ability, gender and learning style) were associated with self-assessment accuracy for each learning objective. “Question selection” decision tree is shown in Figure 1, “critical symptom recognition” in Figure 2, “critical sign recognition” in Figure 3, and “referral urgency selection” in Figure 4. No decision tree is shown for “test selection” as none of the independent variables was associated with self-assessment accuracy for this learning objective.



**Figure 1.** Decision tree showing statistically significant ( $P < 0.05$  after correction for multiple comparisons)

Root nodes (node 0) in each decision tree allow for comparison of the self-assessment accuracy measured for all 195 students across each learning objective. In the case of “test selection” (decision tree not shown), accurate self-assessment occurred in less than one-third of the students (28.2%, 55 students), being over-estimated (43.1%, 84 students) and under-estimated (28.7%, 56 students) in the remainder. This reflected a general trend across all learning objectives in which self-assessment was accurate for 26 to 31% of students and inaccurate for 69 to 74% of students (Figures 1 through 4).

The presence or absence of virtual patient instruction was only associated with variations in self-assessment accuracy for “critical symptom recognition” (Figure 2). Here, 61.3% of the cohort with virtual patient instruction showed over-estimated self-assessment compared with 35.3% of the cohort without this type of instruction. Academic ability was associated with self-assessment accuracy for all learning objectives except “test selection” (Figures 1 to 4). Here, over-estimation was more common in students with lower grades (37 to 76% of students depending on the learning objective) compared with those with higher grades (14 to 50% of students depending on the learning objective). Gender was only associated with self-assessment accuracy for “question selection” (Figure 1) in lower academic achievers, where over-estimation was more common in males (63%) than females (41%). Finally, learning style was not associated with self-assessment accuracy for any of the learning objectives considered.

### Discussion

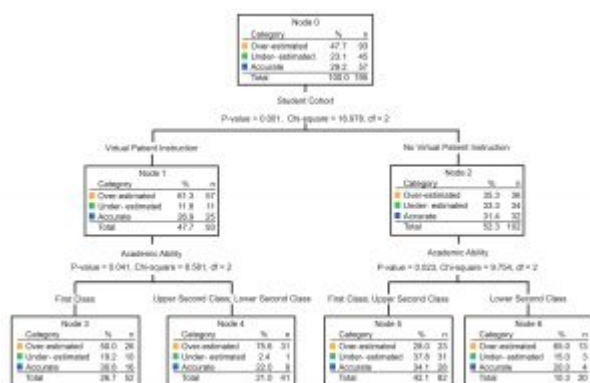
associations between academic ability, gender and self-assessment accuracy for the “question selection” learning objective (Table 1) for second-year optometry students ( $n = 195$ ). This is a form of multivariate analysis that removes confounding between the independent variables entered (i.e., student cohort, academic ability, gender and learning style) before showing the remaining associations in hierarchical order (strongest to weakest). Each node of the decision tree shows the number ( $n$ ) and percentage (%) of students for which self-assessment was over-estimated, under-estimated or accurate. Node 0 (the tree trunk) shows that accurate self-assessment was only found in 29.7% of the students for this learning objective. Academic ability showed the strongest association (first branching level leading to nodes 1 and 2,  $P = 0.002$ ) in which self-assessment was over-estimated more often in students with lower grades (node 2: 49.5%) compared with those with higher grades (node 1: 23.9%). Decision tree analysis automatically governed assignment of students with first class, upper second class and lower second class grades as being of higher or lower academic ability. For students with lower grades, gender showed a slightly weaker association (second branching level leading to nodes 3 and 4,  $P = 0.024$ ) in which self-assessment was over-estimated more often in males (node 4: 62.5%) compared with females (node 3: 41.3%). [Click to enlarge](#)

In this study, we investigated the potential effects of virtual patient instruction in student self-assessment accuracy. For that purpose, we selected a set of specific elements of clinical decision-making (“question selection,” “critical symptom recognition,” “test selection,” “critical sign recognition” and “referral urgency”) as variables within two student cohorts that were trained in classes that either lacked (i.e., control group) or included (i.e., intervention group) virtual patient instruction.

Our first working hypothesis was that, for the five learning objectives, better self-assessment accuracy would occur with virtual patient instruction. However, our results did not support this hypothesis. Virtual patient instruction was only associated with self-assessment accuracy for the learning objective “critical symptom recognition” and had the detrimental effect of increasing the proportion of students over-estimating their skills (Figure 2; 61.3% for teaching with virtual patient instruction [in node 1] compared with 35.3% for teaching without virtual patient instruction [in node 2]). Therefore, our notion that unlimited practice on the virtual patient would lead to improved self-assessment skills was not supported by the findings of the study.

Our second hypothesis was that self-paced virtual patient instruction would give all students an equal opportunity to improve self-assessment independently of student learning style, gender and academic ability. Our results did not support this hypothesis either. The associations detected between self-assessment accuracy and academic ability (Figures 1 to 4) and gender (Figure 1) were independent of the presence or absence of virtual patient instruction. In fact, our findings indicated that students exposed to virtual patient instruction were more likely to be left with an unrealistically high level of confidence in their ability to recognize symptoms of serious disease (Figure 2) and might, therefore, be unaware of their need for further study to improve this skill.

The lack of any positive association between self-assessment accuracy and virtual patient instruction was surprising in a generation of students that favor “concrete experience” and “active experimentation.”<sup>18</sup> Despite this finding, virtual patient instruction remains part of our second-year clinical decision-making course. Student satisfaction scores for this course have ranged from 89% to 96% since it was introduced, with virtual patient instruction often placed at the top of a “what has worked best for you” list of effective learning resources. Interestingly, a previous study at the Rosenberg School of Optometry concluded that use of interactive learning material for first-year gross anatomy classes did not improve test scores but did increase motivation.<sup>19</sup> Perhaps virtual patient instruction was beneficial for student learning on the basis that it motivates students rather than improves self-assessment accuracy.



**Figure 2.** Decision tree showing statistically significant ( $P < 0.05$  after correction for multiple comparisons) associations between student cohort (i.e., the presence or absence of virtual patient instruction), academic ability and self-assessment accuracy for the “critical symptom recognition” learning objective (Table 1) for second-year optometry students ( $n = 195$ ). This is a form of multivariate analysis that removes confounding between the independent variables entered (i.e., student cohort, academic ability, gender and learning style) before showing the remaining associations in hierarchical order (strongest to weakest). Each node of the decision tree shows the number ( $n$ ) and percentage (%) of students for which self-assessment was over-estimated, under-estimated or accurate. Node 0 (the tree trunk) shows that accurate self-assessment was only found in 29.2% of the students for this learning objective. Student cohort showed the strongest association (first branching level leading to nodes 1 and 2,  $P < 0.001$ ) in which self-assessment was over-estimated more often in students that received virtual patient tuition (node 1: 61.3%) compared with those that did not (node 2: 35.3%). Academic ability showed a slightly weaker association (second branching level leading to nodes 3 and 4,  $P = 0.041$  and nodes 5 and 6,  $P = 0.023$ ) in which, for both cohorts, self-assessment was over-estimated more often in students with lower grades (nodes 4 and 6 for the first and second cohorts: 75.6% and 65.0%, respectively) compared with those with higher grades (nodes 3 and 5 for the first and second cohorts: 50.0% and 28.0%, respectively). Decision tree analysis automatically governed grouping. Therefore, the assignment of students with first class, upper second class and lower second class grades as being of higher or lower academic ability differed for students with or without virtual patient instruction. Confounding variations in the academic ability, gender mix and learning styles in both cohorts (the first cohort studied the year before the

An interesting finding of our study was that self-assessment accuracy, for clinical decision-making skills at least, seemed generally poor across all learning objectives: 29.7% for “question selection,” 29.2% for “critical symptom recognition,” 28.2% for “test selection,” 26.2% for “critical sign recognition” and 30.8% for “referral urgency.” These findings corroborate earlier studies involving practitioners (practicing physicians, nurse practitioners and physician assistants) of a continuing medical education course on knee joint injection<sup>9</sup> and junior medical officers carrying out routine skills during their first postgraduate year.<sup>20</sup> However, accurate self-assessment has been reported in other studies involving third-year optometry students<sup>5</sup> and computer engineering students.<sup>6</sup> A systematic review<sup>7</sup> of studies that included practicing physicians, residents or similar health professionals from the United Kingdom, Canada, United States, Australia or New Zealand concluded that physicians had a limited ability to accurately self-assess and that more advanced students and practitioners showed better self-assessment skills.

Our data suggested that academically stronger students were less likely to over-estimate their performance on four of the five learning objectives: “question selection” (Figure 1; 23.9% over-estimation in node 1 for stronger students compared with 49.5% in node 2 for others), “critical symptom recognition” (Figure 2; 50.0% and 28.8% over-estimation in nodes 3 and 5 for stronger students compared with 75.6% and 65% in nodes 4 and 5 for others), “critical sign recognition” (Figure 3; 41.3% in node 1 for stronger students compared with 61.2% in node 2 for others), and “referral urgency” (Figure 4; 14.1% in node 1 for stronger students compared with 36.9% in node 2 for others). Thus, our data was in agreement with some of the previously published work and suggested more developed metacognition skills in the stronger students’ group.

Nevertheless, a study on third-year students at the New England College of Optometry (NECO) showed that optometry students were competent at self-assessment of their clinical skills.<sup>5</sup> These students were asked to self-assess their knowledge base and clinical skills. The clinical instructor supervising each student also evaluated the students using the same criteria. Students’ and instructors’ grades correlated to at least the 95% significance level ( $P < 0.05$ ).<sup>5</sup> We did not find statistically significant correlations between perceived mastery (self-assessment) and actual mastery (exam performance) for any of the five learning objectives we assessed (data not shown). So why did our study findings differ from those obtained at NECO? Several factors could have led to the differences observed. For instance, our students were in the second year of an undergraduate optometric program while the students from NECO were in the third-year of a doctoral program. In addition, perhaps different methods were utilized to measure self-assessment accuracy in each study.

We found that males who were academically weaker were prone to over-estimate their performance for the learning objective “question selection” (Figure 1; 62.5% in node 4 for males with second class grades compared with 41.3% in node 3 for females with second class grades). This also corroborates previous



second) were effectively accounted for in this analysis so that any associations remaining were most likely due to the presence or absence of virtual patient tuition. [Click to enlarge](#)


research on medical students taking part in a third-year surgery rotation,<sup>8</sup> practitioners undergoing continuing medical education,<sup>9</sup> and a meta-analysis of self-assessment in medical students.<sup>12</sup> The first of these studies<sup>8</sup> was designed to determine the ability of medical students to perform self-assessment. Data collected on medical students in their third-year surgery clerkship indicated that women under-estimated their performance and yet outperformed men. The second of these studies<sup>9</sup> investigated how confidence, background, education and skills influenced a practitioner's belief that he or she was qualified to perform a knee joint injection during a continuing medical education session. Participants completed questionnaires gauging confidence and self-assessment before and after instruction. Self-assessments were compared with actual performance on a simulator. Instruction improved confidence, competence and self-assessment, but men disproportionately over-estimated their skills and this worsened as confidence increased. The meta-analysis<sup>12</sup> was conducted to gain a greater understanding of self-assessment accuracy in medical students. Its findings raised the importance of conducting analyses on factors that influence self-assessment accuracy, including gender. The studies analyzed indicated that female students under-estimated their performance more than male students and that gender analyses were often unreported.

In contrast to the previously mentioned study on computer engineering students,<sup>6</sup> our results showed that learning style profile was not associated with self-assessment accuracy. It has been suggested that teaching methods that are adapted to include both poles of the four learning style dimensions would be close to providing the optimal learning environment for most students.<sup>21</sup> Therefore, the lack of any associations could be a positive finding as it suggests that our course on clinical decision-making, with or without virtual patient instruction, catered well to all learning styles. On a cautionary note, however, the study on computer engineering students made use of a more objective self-assessment scale and could, therefore, have been better set up to detect subtle variations associated with learning style.<sup>6</sup>

### Study Limitations

The small size of each student cohort allowed us to achieve enough statistical power to detect associations with large size effects between virtual patient instruction, academic ability, gender, learning style and self-assessment accuracy. We believe, however, that only associations with large size effects justify changes to teaching practice, which would require substantial amounts of time and resources.

The first and second cohorts of students were recruited from classes that entered in different years. This could be a potential flaw in the study as the composition of classes can differ from year to year so that direct comparisons are confounded. The multivariate analyses carried out in this study do, however, provide protection against unsafe comparisons as they remove confounding. That is, yearly variations in the academic ability, gender mix and learning styles in both cohorts were effectively accounted for in our analyses. Therefore, any associations between



**Figure 3.** Decision tree showing the statistically significant ( $P < 0.05$  after correction for multiple comparisons) association between academic ability and self-assessment accuracy for the “critical sign recognition” learning objective (Table 1) for second-year optometry students ( $n = 195$ ). This is a form of multivariate analysis that removes confounding between the independent variables entered (i.e., student cohort, academic ability, gender and learning style) before showing the remaining associations in hierarchical order (strongest to weakest). Each node of the decision tree shows the number ( $n$ ) and percentage (%) of students for which self-assessment was over-estimated, under-estimated or accurate. Node 0 (the tree trunk) shows that accurate self-assessment was only found in 26.2% of the students for this learning objective.

Academic ability showed the only association (one branching level leading to nodes 1 and 2,  $P = 0.013$ ) in which self-assessment was over-estimated more often in students with lower grades (node 2: 61.2%) compared with those with higher grades (node 1: 41.3%). Decision tree analysis automatically governed assignment of students with first class, upper second class and lower second class grades as being of higher or lower academic ability. [Click to enlarge](#)

virtual patient instruction and self-assessment accuracy represent only those that occur after removal of other confounding associations.

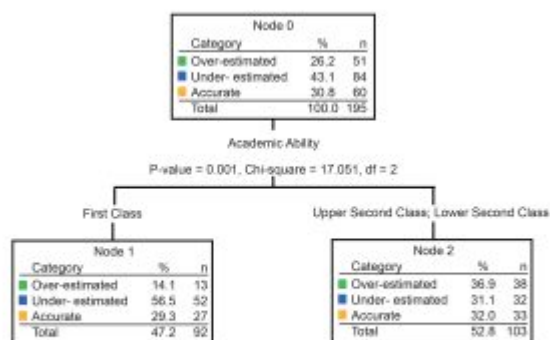
Like our virtual patient, the Ocular Disease Diagnostic Tutor (ODDT) software developed at NECO for fourth-year optometry students,<sup>22</sup> enabled self-paced study. The ODDT was comprised of five activities: (1) interactive topic files providing background knowledge, (2) recognition exercises introducing clinical terms, (3) diagnostic cases testing recall of background knowledge and clinical terms, (4) clinical reasoning cases requiring formulation of differential diagnoses and treatment plans, and (5) interactive quizzes. Similar to our virtual patient, the ODDT software was designed to encourage problem-solving rather than factual recall.<sup>22</sup> As mentioned in the Methods section, our virtual patient provided background knowledge via “at a glance” guides and allowed students to interact with a virtual clinical environment in order to demonstrate: 1) application of background knowledge, 2) recognition of critical symptoms and signs, 3) clinical reasoning, and 4) the use of appropriate terminology when recording clinical findings and selecting the most likely diagnoses and appropriate treatment plans. Despite similarities in the design concept of the virtual patient and ODDT software, ODDT was designed for fourth-year optometry students. This may explain, at least in part, why the results from the studies at NECO and our school differ.

Our questionnaire on perceived mastery was not validated on an independent student population; therefore, its reliability could not be determined. Interestingly, the systematic review on the accuracy of physician self-assessment<sup>7</sup> found that most studies had used self-assessment questionnaires that had not been validated. This was also true for some of the studies on medical students or practitioners cited above.<sup>8,9</sup> The study involving computer engineering students used an objective self-assessment scale based on Bloom’s Revised Taxonomy.<sup>6</sup> Use of a similar scale in our study might have allowed detection of subtle variations associated with learning style and may also be a valuable tool for future studies on the improvement of self-assessment in students as they progress through undergraduate and postgraduate optometric training.

We had developed a notion that unlimited self-paced virtual patient instruction would give all students an equal opportunity to improve self-assessment independently of student learning style, gender and academic ability. On reflection, we missed an opportunity to test this notion more thoroughly. Had we monitored how many times students accessed the online virtual patient for self-paced practice purposes, we might have obtained the data to better explain our findings. For example, we might have found that students were not taking the opportunity to practice, or that gender and academically ability influenced the level of engagement in self-paced practice. This will be a potentially valuable avenue for further study.

## Conclusion

The findings of this study suggested that our second-year optometry students had poor self-assessment accuracy in relation



**Figure 4.** Decision tree showing the statistically significant ( $P < 0.05$  after correction for multiple comparisons) association between academic ability and self-assessment accuracy for the “referral urgency selection” learning objective (Table 1) for second-year optometry students ( $n = 195$ ). This is a form of multivariate analysis that removes confounding between the independent variables entered (i.e., student cohort, academic ability, gender and learning style) before showing the remaining associations in hierarchical order (strongest to weakest). Each node of the decision tree shows the number ( $n$ ) and percentage (%) of students for which self-assessment was over-estimated, under-estimated or accurate. Node 0 (the



tree trunk) shows that accurate self-assessment was only found in 30.8% of the students for this learning objective. Academic ability showed the only association (one branching level leading to nodes 1 and 2,  $P = 0.001$ ) in which self-assessment was over-estimated more often in students with lower grades (node 2: 36.9%) compared with those with higher grades (node 1: 14.1%). Decision tree analysis automatically governed assignment of students with first class, upper second class and lower second class grades as being of higher or lower academic ability. [Click to enlarge](#)

to the clinical decision-making learning objectives shown in Table 1, and that the use of virtual patient instruction was not associated with an improvement in self-assessment accuracy. Student feedback, nevertheless, indicated that virtual patient instruction helped them to learn. We also observed that lower academic ability, especially in males, was associated with over-estimated self-assessment. Previous research carried out on improving self-assessment skills<sup>4, 23</sup> has led to the suggestion that curricula should include opportunities for students to develop self-assessment skills early in their degree programs, and this should be reinforced throughout the entire curriculum.<sup>4</sup> Additional research is needed to evaluate the efficacy of different instructional methods in promoting self-assessment accuracy in students. Data generated through these studies will aid in the design of successful implementation protocols that could be adapted and incorporated into the optometric curriculum.

### Acknowledgements

We thank Abdullah Bhamji, Pardeep Chohan, Hardish Dhillon, Sharon Lamson, Hui Lok, Ebrahim Lorgat, Nashreen Mulla, Andrew Munson and Taha M Jalal for testing and evaluating prototypes of our virtual patient. We are also very grateful to the reviewers of *Optometric Education* for helping us to improve this paper.

### References

1. Faucher C. Differentiating the elements of clinical thinking. *Optometric Education*. 2011;36(3):140-5.
2. Pane A, Simcock P. *Practical ophthalmology: a survival guide for doctors and optometrists*. Elsevier Health Sciences; 2005.
3. Sharaf AA, AbdelAziz AM, El Meligy OA. Intra-and inter-examiner variability in evaluating preclinical pediatric dentistry operative procedures. *Journal of Dental Education*. 2007;71(4):540-4.
4. Mort JR, Hansen DJ. First-year pharmacy students' self-assessment of communication skills and the impact of video review. *American Journal of Pharmaceutical Education*. 2010;74(5):78.
5. Denial A. Accuracy of self-assessment and its role in optometric education. Poster #53. *Optometry and Vision Science*. 2001;78(12):266.
6. Alaoutinen S. Effects of learning style and student background on self-assessment and course performance. In: *Proceedings of the 10th Koli Calling International Conference on Computing Education Research 2010* (pp. 5-12). ACM.
7. Davis DA, Mazmanian PE, Fordis M, Van Harrison RT, Thorpe KE, Perrier L. Accuracy of physician self-assessment compared with observed measures of competence: a systematic review. *JAMA*. 2006;296(9):1094-102.
8. Lind DS, Rekkas S, Bui V, Lam T, Beierle E, Copeland E 3rd. Competency-based student self-assessment on a surgery rotation. *Journal of Surgical Research*. 2002;105(1):31-4.
9. Leopold SS, Morgan HD, Kadel NJ, Gardner GC, Schaad DC, Wolf FM. Impact of educational intervention on confidence and competence in the performance of a simple surgical task. *J Bone Joint Surg Am*. 2005;87(5):1031-7.
10. Bandura A. Self-efficacy: toward a unifying theory of behavioral change. *Psychological Review*. 1977;84(2):191.
11. Glittenberg C, Binder S. Using 3D computer simulations to enhance ophthalmic training. *Ophthalmic Physiol Opt*. 2006;26(1):40-9.
12. Blanch-Hartigan D. Medical students' self-assessment of performance: results from three meta-analyses. *Patient Education and Counselling*. 2011;84(1):3-9.
13. Prajapati B, Dunne M, Bartlett H, Cubbidge R. The influence of learning styles, enrollment status and gender on

- academic performance of optometry undergraduates. *Ophthalmic Physiol Opt.* 2011;31(1):69-78.
14. Rushton RM, Armstrong RA, Dunne M. The influence on unaided vision of age, pupil diameter and sphero-cylindrical refractive error. *Clinical and Experimental Optometry.* 2016;99(4):328-35.
  15. Faul F, Erdfelder E, Lang AG, Buchner A. G\*Power 3: a flexible statistical power analysis program for the social, behavioral, and biomedical sciences. *Behav Res Methods.* 2007;39(2):175-91.
  16. Prajapati B, Dunne M, Armstrong R. Sample size estimation and statistical power analyses. *Optometry Today.* 2010;16(07):10-8.
  17. Cohen J. *Statistical power analysis for the behavioural sciences.* Hillside, NJ: Lawrence Earlbaum Associates. 1988.
  18. Eubank TF, Pitts J. A comparison of learning styles across the decades. *Optometric Education.* 2011;36(2):72-5.
  19. Sanchez-Diaz PC. Impact of interactive instructional tools in gross anatomy for optometry students: a pilot study. *Optometric Education.* 2013;38(3):100-5.
  20. Barnsley L, Lyon PM, Ralston SJ, et al. Clinical skills in junior medical officers: a comparison of self-reported confidence and observed competence. *Medical Education.* 2004;38(4):358-67.
  21. Felder RM, Silverman LK. Learning and teaching styles in engineering education. *Engineering Education.* 1988;78(7):674-81.
  22. Sleight WE. Assessment of the ocular disease diagnostic tutor as a learning tool. *Optometric Education.* 2011;36(2):63-71.
  23. Hawkins SC, Osborne A, Schofield SJ, Pournaras DJ, Chester JF. Improving the accuracy of self-assessment of practical clinical skills using video feedback-the importance of including benchmarks. *Medical Teacher.* 2012;34(4):279-84.



Dr. Pancholi (nee Prajapati) carried out this study as part of her postgraduate research while she worked as a Clinical Demonstrator in the Optometry School at Aston University, UK. Previously, she had trained pre-registration students in private practice.

Dr. Dunne [[m.c.m.dunne@aston.ac.uk](mailto:m.c.m.dunne@aston.ac.uk)] is Senior Lecturer in the Optometry School at Aston University, UK. He supervised Dr Pancholi's postgraduate research.

## IT'S TIME TO APPLY FOR A 2018 EDUCATIONAL STARTER GRANT

ASCO and The Vision Care Institute, LLC, an affiliate of Johnson & Johnson Vision Care, Inc., are pleased to announce the opening of the application period for the 2018 Educational Starter Grants.

The grants, which have been available for the past several years, are dedicated to supporting educational research. They are a great opportunity for faculty to get involved in conducting educational research, which impacts teaching, student learning and the profession.

Interested faculty can find information about the grants, past successful grant proposals and the current application at the ASCO website under [Awards & Grants Opportunities](#). Completed applications should be submitted electronically to [Sara Lau](#) by midnight, July 24, 2018.



## KEEPING DISRUPTIVE TECHNOLOGIES IN PERSPECTIVE

In 1997, in his book “The Innovator’s Dilemma,” Prof. Clayton Christensen from Harvard Business School introduced the term “disruptive technology.”<sup>1</sup> In the book, Christensen distinguishes sustaining technology from disruptive technology. He characterizes sustaining technologies as those that introduce small changes that improve the performance of an existing technology. He describes disruptive technologies as those that displace an established technology, and thus “shake up” an industry, or ground-breaking products that create a completely new industry.<sup>2</sup> Often, disruptive technology can underperform established technology, at least in the short term.<sup>1</sup> However, according to Christensen, products based on disruptive technologies are typically cheaper, simpler, smaller and frequently more convenient to use. Some examples of disruptive technologies (and the technologies/conventions they displaced): the personal computer (typewriter), health maintenance organizations (conventional insurers), transistors (vacuum tubes), cell phones (land lines), laptop computers (desktop computers), smartphones (cell phones).<sup>1,2</sup>

### Disruptive Technologies in Eye Care

At a recent continuing education event at the New England College of Optometry, Dr. Howard Purcell, a Senior Vice President at Essilor of America, spoke about how disruptive technologies are impacting the profession of optometry. He urged practitioners “to look at the disruptive technologies and understand the value they can bring to your practice.”<sup>3</sup> Dr. Purcell talked about smart phone apps, online and remote refractions, 3D printing, virtual reality devices and wearable technology. Also on the horizon is artificial intelligence software, which allows a computer to analyze conditions, symptoms, clinical findings, diagnosis and treatment.<sup>4</sup> In 2013, at the 90th annual SECO International meeting in Atlanta, Dr. David Talley, who practices in Memphis, Tenn., described trends and technology in the profession. Trends included refractive lasers, expansion of scope of practice including the use of injectable medications such as Botox and minor surgical procedures.<sup>5</sup> Technology included gene chip analysis, radio frequency technology, plasma surgery and tissue engineering and biomechanics, which includes organ regeneration and replacement, wound healing and adhesion.<sup>5</sup>

### Adding Forward Thinking to the Skill Set

Optometric educators have a responsibility to provide students with the knowledge and practical skills that will enable them to practice in the world of today and tomorrow. Therefore, fostering an aptitude for forward thinking is a worthy goal. But how do we create a culture of forward thinkers both for faculty and students that embraces future technology and trends, yet acts in a responsible manner to ensure the safety of patients and a sound learning environment? We can nurture and support the characteristics that define a forward thinker. Although these characteristics are somewhat arbitrary, several that make sense to me are identified in the literature. Forward thinkers embrace both critical and creative thinking.<sup>6</sup> Critical thinking ensures complete, unbiased thinking whereas creative thinking ensures that people are thinking outside of the box and creating a new vision.<sup>6</sup> These qualities are particularly important for evaluating new technologies or trends. Forward thinkers do not dwell on the past.<sup>6</sup> They learn from the past but do not reside in the past. They have the ability to see the larger picture and set goals for the future.<sup>6</sup> Forward thinkers embrace risk-taking and persevere even if initial ideas are unsuccessful.<sup>6</sup> They tend to possess “intellectual empathy, which is an awareness of the need to actively entertain views that differ from your own, especially those with which you strongly disagree.”<sup>6,7</sup> This allows insight into different points of view and the capability to be receptive to new ideas. In academia, nurturing these characteristics involves creating an environment of trust, support and respect.

Future optometrists, throughout their careers, will evaluate and make decisions on the incorporation of technology into practice, changes in scope of practice and utilization of current trends. Technology, either sustaining or disruptive, represents tools for the profession. Disruptive technology has the potential to alter the appearance of the optometric setting and patient interaction. However, as disruptive as it may be, technology will never replace the clinical judgment, knowledge and communication that defines the profession of optometry. In the educational arena, faculty are constantly



Aurora Denial, OD, FAAO

forming a balance between letting go of the past and incorporating the future in a responsible manner. Supporting a culture of forward thinkers supports the future of the profession.

## References

1. Christenson CM. The Innovator's Dilemma: When New Technologies Cause Great Firms to Fail. Boston, Mass: Harvard Business School Press, 1997, p10-11.
2. WhatIs.com. Disruptive technology. 2016 [cited 2018 Feb 2]. Available from: <http://whatIs.techtarget.com/definition/disruptive-technology>.
3. New England College of Optometry. Continuing education event explores role of new technologies in optometry, Boston, MA; [cited 2018 Feb 2]. Available from: <https://www.neco.edu/news/entry/new-technologies-optometry>.
4. Primary Care Optometry News. Embrace disruptive technologies while advocating for patients. 2017 [cited 2018 Feb 2]. Available from: <https://www.healio.com/optometry/technology/news/print/primary-care-optometry-news/%7Beaebcc8e-3739-451e-9c36-da1f2522baa6%7D/embrace-disruptive-techno>.
5. Optometry Times. Peek into optometry's future with trends and technology, 2013 [cited 2018 Feb 2]. Available from: <http://optometrytimes.modernmedicine.com/optometrytimes/news/user-defined-tags/ehr/peek-optometry%E2%80%99s-future-trends-and-technology>.
6. Ross G. Traits of a forward thinker. [cited 2018 Jan 29]. Available from: <https://www.wisdomtimes.com/blog/forward-thinker-traits/>.
7. Hawkins D, Elder L, Paul R. The Thinker's Guide to Clinical Reasoning, Dillon Beach, CA: Foundation for Critical Thinking, 2010.



Dr. Denial [[deniala@neco.edu](mailto:deniala@neco.edu)], Editor of Optometric Education, is a Professor and Chair of the Department of Primary Care at the New England College of Optometry and a Clinical Instructor at a community health center in Boston.



## HYPERTENSIVE CHOROIDOPATHY: A TEACHING CASE REPORT

### Abstract

*Approximately 1 in 3 adults in the United States has hypertension.<sup>23</sup> Blood pressure is under control in only approximately half of those adults.<sup>24</sup> Because the retina is the only place in the body where the vasculature can be observed directly, eyecare providers are uniquely positioned to evaluate the effects of hypertension. This case-based report discusses fundus signs in a patient with accelerated hypertension. A review is given of ocular blood flow, the pathophysiology of fundus signs, diagnostic testing, staging of hypertension and hypertensive retinopathy. The discussion should lead to an understanding of the optometrist's role in the management of patients with elevated blood pressure.*

**Key Words:** hypertensive retinopathy, hypertensive choroidopathy, malignant hypertension, hypertensive crisis

### Introduction

Patients with hypertension often present with ocular findings of hypertensive retinopathy. In 1898, Marcus Gunn first described hypertensive retinopathy to include generalized and focal arteriolar narrowing, arteriovenous crossing changes, retinal hemorrhages, cotton wool spots and disc edema. Later, fundus findings in hypertensive choroidopathy would be described to include Siegrist streaks<sup>25</sup> and Elschnig spots.<sup>26</sup> Three distinct entities have been hypothesized: hypertensive retinopathy, hypertensive choroidopathy and hypertensive optic neuropathy.<sup>1</sup> This teaching case report describes a noncompliant patient with chronic hypertension in a hypertensive urgent crisis. It highlights the findings associated with hypertensive retinopathy, choroidopathy and optic neuropathy. This paper is intended for third- and fourth-year optometry students and all eyecare providers in clinical care.

### Case Report

A 57-year-old white male presented to the Veterans Affairs (VA) healthcare clinic on Dec. 5, 2014 for the initial visit with his primary care provider. His blood pressure was 251/136 mmHg, and he had a 7-year history of severe hypertension managed outside the VA. He was taking amlodipine 10 mg daily, clonidine 0.1 mg bid and metoprolol 50 mg bid. He reported no focal neurological symptoms and no vision problems, and he denied palpitations. After examination, the patient was diagnosed with acute renal failure in addition to chronic renal disease due to malignant hypertension from improper medication management and noncompliance. Clonidine 0.2 mg was given in-office and the patient was referred to the emergency room.

The patient received additional medication in the emergency room, but his blood pressure remained elevated at 191/110 mmHg. He was transferred to a private nephrologist. After a review of records on file, the nephrologist placed the patient on the following medications to be taken once daily: carvedilol 12.5 mg, doxazosin 2 mg, clonidine 0.1 mg patch, 1,000 mg Vitamin D2 and calcium acetate. The nephrologist discharged the patient back to the VA with a poor prognosis given the history of non-adherence to medical care. On Dec. 12, 2014, the patient returned to his VA primary care provider for follow-up, and his blood pressure was improved at 114/72 mmHg. He reported seeing "sun spots" or "afterimages" in both eyes after starting the new hypertensive medications and was referred to the eye clinic for same-day evaluation.

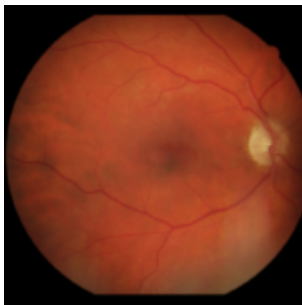
Further history during the eye exam included a severe (10/10 on the pain scale) left temple headache that started one week prior. At the exam, the patient felt the severity of the headache was 5/10. Entering visual acuity and best-corrected visual acuity were 20/20 in each eye. Intraocular pressure was 10 mmHg OD and 11 mmHg OS at 2:09 p.m. Dilated fundus exam showed cup to disc (C/D) ratio of 0.4 OD and 0.5 OS. Macular findings were unremarkable. Vessels showed marked arteriolar attenuation and crossing changes. Some small, scattered hemorrhages were present in the posterior pole, OS>OD, as were a few areas of flat greyish spots OS (**Figures 1 and 2**). Optical coherence tomography (OCT) of the optic nerve and macula were performed. OCT of the optic nerve showed diffuse retinal nerve fiber layer thinning in both eyes (**Figure 3**). Macular scans showed a nasal area of thinning OD and inferior-nasal thinning in both eyes. The patient was diagnosed with moderate hypertensive retinopathy, and it was recommended that he return to the eye clinic for follow-up in 6 months.

The patient continued to be seen by nephrology and primary care at regular intervals over the next 2 years during which time medication non-compliance issues continued. His in-office blood pressure ranged from 105/71 mmHg to 190/109 mmHg. In February 2016, he reported poor home blood pressure control, fatigue, decreased appetite and weight loss. Consequently, dialysis was initiated and the patient was referred as a candidate for a kidney transplant.

In October 2016, approximately 2 years after his initial visit, the patient returned to the eye clinic for follow-up. His chief

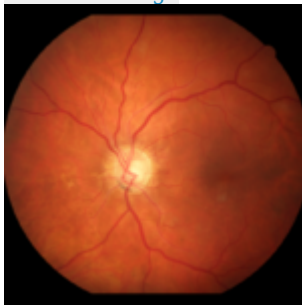

complaints at this visit were diminished distance vision while wearing glasses and the need to remove his glasses to read. Refraction yielded visual acuities of 20/20 OD and 20/20-2 OS with -1.75-1.25X070 OD and -2.00-0.75X140 OS. Intraocular pressure was 12 mmHg OD and 14 mmHg OS at 1:04 p.m. Slit lamp examination findings were remarkable for 1+ superficial punctate keratitis OU. Dilated fundus exam revealed a C/D ratio of 0.55 round (rd) OD, 0.6 rd OS with pallor and the appearance of thinning inferiorly. A linear hypopigmented choroidal lesion inferior to the optic nerve OS, which was not present on prior photos, was noted (**Figures 4 and 5**). OCT scans of the optic nerve and macula were obtained, and both eyes showed diffuse progressive thinning of the retinal nerve fiber layer (**Figure 6**) and macula compared to prior scans. The patient's blood pressure at this visit was 146/87 mmHg. He was diagnosed with moderate hypertensive retinopathy with secondary extensive progressive atrophy of the optic nerve and macula. The patient was also diagnosed with a possible Siegrist streak OS, indicating hypertensive choroidopathy, and referred to ophthalmology for evaluation.




**Figures 1 and 2.** Fundus imaging at the patient's initial visit in 2014 shows arteriovenous crossing changes and arteriolar attenuation OU secondary to hypertension, scattered retinal hemorrhages (OS>OD), and a few areas of flat greyish spots OS.

[Click to enlarge](#)

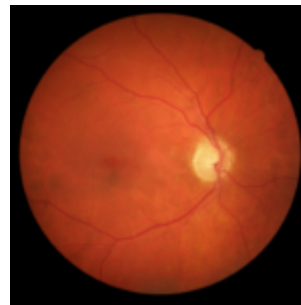

[Click to enlarge](#)



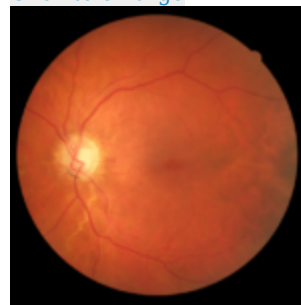
**Figure 3.** Initial OCT scans in 2014 reveal diffuse thinning of the retinal nerve fiber layer OU.

[Click to enlarge](#)

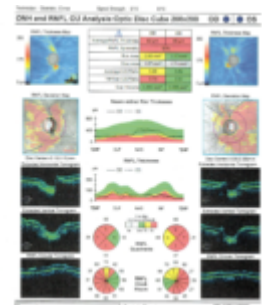


**Figures 4 and 5.** In October 2016, dilated fundus exam reveals C/D ratios of 0.55 rd OD and 0.6 rd OS with pallor and the appearance of thinning inferiorly. A linear hypopigmented choroidal lesion inferior to the optic nerve OS, which was not present on prior photos, was observed.

[Click to enlarge](#)



[Click to enlarge](#)



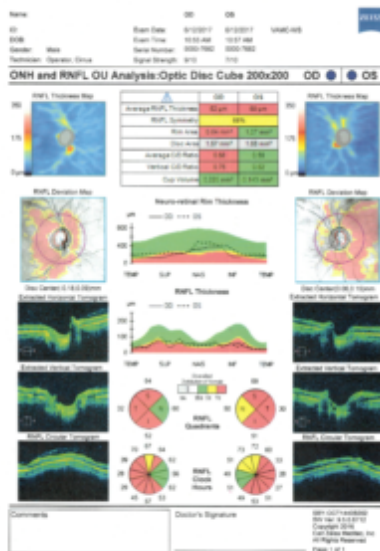
**Figure 6.** OCT scans obtained in October 2016, show diffuse, progressive thinning of the retinal nerve fiber layer (and macula).

[Click to enlarge](#)


In December 2016, the patient was evaluated by ophthalmology. Examination findings were consistent with the October 2016 optometric findings. The ophthalmologist recorded a C/D ratio of 0.55 rd OD, 0.6 rd OS with pallor and appearance of thinning inferiorly OU and superiorly OD. The hypopigmented choroidal lesion extending inferior to the optic nerve OS was confirmed to be consistent with Siegrist streak. The final diagnosis was malignant hypertension with temporal optic nerve pallor OU and hypertensive choroidopathy with Siegrist streak OS. The recommended follow-up was with optometry in 6 months.

In June 2017, after retinal consultation, the patient returned to the eyecare clinic for the 6-month follow-up. He had no ocular complaints. Visual acuity was 20/25-2 OD and 20/30-2 OS. Blood pressure was 174/84 mmHg. Intraocular pressure was 15 mmHg OD and 16 mmHg OS at 9:56 a.m. Slit lamp examination was unremarkable. Dilated fundus exam showed 1+ nuclear sclerotic cataracts OU, stable C/D ratios of 0.55 rd OD and 0.6 rd OS with pallor OU, Siegrist streak inferior to the optic nerve OS, macular mottling OU, attenuated vessels and unremarkable retinal periphery OU. OCT of the optic


nerve and macula were obtained again and showed stable thinning of the retinal nerve fiber layer and macula (**Figure 7**) compared to scans from the October 2016 visit. The patient was assessed as having malignant hypertension with improved control of blood pressure, stable optic nerve atrophy OU and Siegrist streak OS. He returned in October 2017 to undergo baseline visual field testing (**Figures 8 and 9**). The results were unreliable OU; however, the test showed defects inferiorly OU and superiorly OS, which correlated with the Siegrist streak OS.



**Figure 7.** OCT in June 2017 shows stable thinning of the retinal nerve fiber layer (and in October 2017 shows defects inferiorly OU).  
[Click to enlarge](#)



**Figure 8.** Baseline visual field testing in October 2017 shows defects inferiorly OU.  
[Click to enlarge](#)



**Figure 9.** Baseline visual field testing in October 2017 shows defects inferiorly OU and superiorly OS, which correlates with the Siegrist streak OS.  
[Click to enlarge](#)

## Educator's Guide

### Key concepts

1. Hypertension affects millions of Americans, and dilated fundus exams are essential in the management of the condition
2. Recognizing signs and symptoms of hypertensive retinopathy and choroidopathy may help providers to understand and manage these conditions
3. There are key differences in the vascular flow between the retina and choroid and these differences play a role in the development of hypertensive retinopathy vs. choroidopathy
4. Ancillary testing, such as fundus photography, OCT, fundus autofluorescence and fluorescein angiography may be useful in the management of hypertensive retinopathy and choroidopathy

### Learning objectives

After this case discussion, participants should be able to:

1. Classify hypertensive retinopathy
2. Categorize hypertensive crises into emergencies and urgencies
3. Recognize the fundus findings associated with hypertensive retinopathy
4. Identify common findings associated with hypertensive choroidopathy
5. Understand the difference between retinal and choroidal blood flow
6. Understand how ancillary testing can be used to recognize and manage hypertensive retinopathy and choroidopathy

7. Understand the optometrist's role in managing uncontrolled hypertension

*Discussion points*

1. Categorize hypertensive crises into emergencies and urgencies
2. Describe the blood flow from the ophthalmic artery to the retina and choroid
3. What retinal findings are associated with hypertensive retinopathy?
4. What are some ocular findings associated with hypertensive choroidopathy?
5. What are the differential diagnoses of hypertensive choroidopathy?
6. What is the pathophysiology behind optic nerve head and nerve fiber layer changes in chronic hypertension?
7. Describe the role of fluorescein angiography and fundus autofluorescence in hypertensive retinopathy/choroidopathy diagnosis and management
8. What are some end organs that are damaged by hypertension?

*Discussion*

Hypertension is defined by the American Heart Association as systolic pressure greater than 139 mmHg or diastolic pressure greater than 89 mmHg. Approximately 75 million Americans have hypertension and are at increased risk for myocardial infarction, heart failure, stroke, renal disease and early death.<sup>6</sup> An accelerated hypertension or hypertensive crisis affects approximately 1% of people with high blood pressure and is defined as extremely high blood pressure that develops rapidly and causes some type of organ damage. It is most common in younger adults, especially African Americans. Blood pressure is typically 180/120 mmHg or greater in these cases, which should be treated as medical emergencies.

Changes in vasculature from hypertension are visible in the retina and are indicative of vessel changes elsewhere in the body. The retina receives a dual blood supply from branches of the ophthalmic artery. The inner retina is supplied by the central retinal artery. The outer retina and choroid receive their blood supply from the long and short posterior ciliary arteries.<sup>6</sup> The posterior ciliary artery is the main arterial blood supply for the optic nerve.<sup>29</sup>

The retinal and choroidal vascular beds have fundamentally different properties. The choroidal bed lacks an autoregulatory mechanism for blood flow, has no blood-ocular barrier, and has a sympathetic nerve supply.<sup>1</sup> The retinal vascular bed has efficient autoregulation, a blood-retinal barrier, and no sympathetic nerve supply. Because of these properties, the choroidal and retinal vascular beds respond differently to elevated blood pressure.

In hypertensive retinopathy, the initial response to elevated blood pressure is vasospasm and vasoconstriction of the retinal arterioles leading to arteriole narrowing called the vasoconstrictive phase.<sup>2</sup> Eventually, elevated blood pressure may lead to endothelial damage, intimal thickening and vessel narrowing called the sclerotic phase. This results in copper wiring, i.e., moderate vascular wall changes, and arteriovenous nicking. If hypertension remains uncontrolled, an exudative phase may develop. In this stage, the blood-retina barrier is disrupted leading to blood and fluid accumulation within the retina. Ischemic findings during this phase may include cotton wool spots, microaneurysms, retinal hemorrhages and macular edema.<sup>2,3,12</sup> It is important to note though that the stages may not be sequential. The exudative signs may be seen without the sclerotic phase. This occurs because the sclerotic phase is a result of chronic hypertension and the exudative phase is indicative of recent uncontrolled hypertension.<sup>13</sup>

Accelerated hypertension can lead to choroidal ischemia and hypertensive choroidopathy, as in the patient in this case report. In reno-vascular malignant hypertension, excessive angiotensin and norepinephrine in the choroidal fluid cause choroidal vasoconstriction that leads to the ischemia. Hypertensive choroidopathy is less commonly seen than hypertensive retinopathy. It can manifest as Elschnig spots, Siegrist streaks and rarely serous retinal detachments.<sup>5</sup> Elschnig spots are changes to the retinal pigment epithelium (RPE) that overlies infarcted choriocapillaries. These appear as pale, yellow, well-demarcated lesions often found in the perimacular region followed by the peripapillary region.<sup>1</sup> Fluorescein angiography at this stage often shows generalized delayed patchy filling of the choroidal vascular bed and in the macular region marked delay and staining of the lesions during the late phase.<sup>1</sup> Over time, the RPE becomes hyperpigmented with a margin of hypopigmentation. Healed Elschnig spots do not leak fluorescein, but transmission defects may appear through the hypopigmented halo.<sup>9</sup> In cases of chronic or severe hypertension, Siegrist streaks can be seen as linear hyperpigmented streaks along the course of choroidal arteries.<sup>9</sup> The presence of Siegrist streaks may signify advanced

vascular sclerosis.<sup>1</sup> Persistent chronic choroidal ischemia may lead to progressive late RPE degenerative lesions that are widely scattered with heavy distribution in the temporal aspect of the macula and periphery.<sup>1</sup> The lesions can be composed of polymorphic RPE atrophic lesions as well as diffuse pigmentary changes and may be focal to confluent.<sup>1</sup> The macular changes often look like those seen in senile macular degeneration, and the peripheral fundus changes may resemble late-stage birdshot retinopathy.<sup>1</sup> These late degenerative lesions are typically more extensive than the acute lesions, and fluorescein angiography often shows even more extensive lesions than seen clinically.

In rare cases, serous retinal detachment occurs because of global choroidal dysfunction and decompensation of the RPE.<sup>6</sup> These are usually bullous in nature, and the macular region is often the area affected followed by the periphery. The detachments are usually shallow and well-circumscribed. Once resolved, extensive RPE changes are often more evident.

Hypertensive optic neuropathy usually presents as bilateral disc swelling. This finding has the strongest association with death; therefore, it is a true hypertensive emergency. The pathogenesis of the papilledema is unclear but may be due to ischemia, raised intracranial pressure secondary to hypertensive encephalopathy or obstruction of axoplasmic flow from ischemia and choroidal nonperfusion.<sup>1-3,12</sup> Other causes of papilledema, such as space-occupying lesions and benign idiopathic intracranial hypertension must be ruled out, so imaging may be required. Optic disc swelling secondary to hypertension usually resolves with improved blood pressure control. Resolution of the swelling often results in optic nerve pallor and retinal nerve fiber layer loss. Longstanding chronic elevated hypertension may result in nerve fiber layer loss as well, as seen in this patient.<sup>11</sup> The nerve fiber layer defects are localized and have not been shown to change the size or shape of the neuroretinal rim or peripapillary atrophy as seen in glaucomatous optic neuropathy.<sup>11</sup> Chronic hypertension can lead to vasoconstriction of peripapillary choroidal vessels and posterior ciliary arteries that supply the optic nerve. This chronic hypoperfusion can result in optic nerve atrophy and pallor.<sup>27,28</sup> These changes are reflected on an OCT as thinning in the nerve fiber layer.

#### *Differential diagnosis*

There are several conditions that may mimic hypertensive retinopathy including diabetic retinopathy, anemic retinopathy, venous occlusive disease, carotid occlusive disease, radiation retinopathy, perifoveal telangiectasia and collagen vascular diseases.<sup>14,18,19</sup> Because the RPE and other tissues supplied by choroidal vasculature respond in limited ways to decreased perfusion, hypertensive choroidopathy may be difficult to distinguish from other clinical conditions that cause choroidal ischemia including vascular, inflammatory and degenerative diseases. These conditions include toxemia of pregnancy, disseminated intravascular coagulopathy, multifocal acute ischemic choroidopathy, collagen vascular disorders, thrombotic thrombocytopenic purpura, leukemia, Goodpasture syndrome, hemolytic diseases, cardiac lesions, giant cell arteritis, and other local vascular and systemic disease.<sup>1,15</sup> Furthermore, in the late stages of hypertensive choroidopathy, the macular region is often indistinguishable from senile macular degeneration as drusen develop. This may indicate that chronic choroidal ischemia may play a role in development of drusen.<sup>4</sup> Choroidal ischemia can also result from iatrogenic sources. Laser thermocoagulation and photodynamic therapy have been shown to create segmental choroidal ischemia and vascular occlusion.<sup>17</sup>

#### *Role of fluorescein angiography and fundus autofluorescence*

Fluorescein angiography may show varied findings. With hypertensive retinopathy, dilation of capillaries, telangiectasia, capillary nonperfusion and/or leakage from retinal vessels may be seen.<sup>14,18</sup> Leakage may be present at the optic nerve if edema is present.<sup>14,18</sup> In hypertensive choroidopathy, choroidal bed abnormalities can be seen and RPE degeneration is visualized more clearly compared to visualization with funduscopy alone. This is due to unmasking of choroidal fluorescence in degenerated areas, which demonstrate choroidal circulatory insufficiency.<sup>21</sup> In early hypertensive choroidopathy, a mild to marked delayed or patchy filling of the choroidal bed can be seen and is especially noticeable in the macular area. Acute focal RPE lesions are associated with this delayed and patchy choroidal bed fluorescein filling and will stain during the late phase.<sup>21,22</sup> Older degenerative choroidal lesions will begin to show unmasking of the choroidal fluorescence during the transit stage, but they do not stain late.<sup>21</sup>

By highlighting lipofuscin distribution in the RPE, fundus autofluorescence may also play a role in identifying retinal changes due to hypertension. In a small study by Ramezani, et al., fundus autofluorescence revealed some pathological changes at the level of the RPE.<sup>4</sup> These changes included a hyper-autofluorescent ring surrounding a small area of hypo-autofluorescence at the fovea. This was evident in patients with chronic hypertension significantly more often than in normotensive patients. It was also noted that hyper-autofluorescent patches of RPE outside of the fovea were found more often in patients with chronic hypertension, but this was not statistically significant.<sup>4</sup>

Changes in the foveal RPE are thought to be the result of possible damage caused by chronic hypertension resulting in lipofuscin accumulation in the RPE at the fovea, a reduction of macular pigment, or both. It is also possible that patches of mixed autofluorescent patterns outside the fovea are secondary to past episodes of acute elevated blood pressure; however, a larger study would be needed to find statistical evidence of this. It is possible that fundus autofluorescence may be used to detect retinal problems such as hypertensive retinopathy or choroidopathy in early stages because the retinal changes found were not visible by routine imaging or funduscopy.<sup>4</sup>

#### Target organ damage

Hypertensive end organ damage occurs when the major organs (i.e., heart, brain, kidneys, eyes) nourished by the circulatory system undergo damage or impairment from uncontrolled hypertension. This can manifest in a variety of ways including stroke, myocardial infarction, heart failure, albuminuria, proteinuria, renal failure, encephalopathy, subarachnoid hemorrhage, dissecting aortic aneurysm, pulmonary edema and renal failure.<sup>10,12-14</sup>

Ocular target organ damage includes the ocular findings discussed above as well as retinal artery or vein occlusions, cranial nerve palsies, nonarteritic anterior ischemic optic neuropathy and macroaneurysms.<sup>12,13</sup>

Identifying end organ damage is important in the clinical decision-making process for managing the patient's overall cardiovascular risk. If end organ damage is present, such as in the case of this patient, more intense treatment may be required as the goal should be to reduce the blood pressure to values of 130/80 mmHg or lower.<sup>10</sup>

#### Classification and management of hypertensive patients

**TABLE 1**  
Classification of Hypertensive Retinopathy

Grade of retinopathy	Retinal findings	Diastolic BP (mmHg)	Systemic associations
Mild	generalized and focal arteriolar narrowing, A/V crossing changes	> 90 and < 110	modest association with risk of stroke, heart disease
Moderate	hemorrhages, retinal aneurysms, cotton wool spots, hard exudates	≥ 110 to 120	strong association with stroke, death, cardiovascular disease
Severe	moderate retinal findings plus optic nerve swelling	≥ 120	strong association with death

From Wong et al<sup>11</sup>  
A/V = arterio/venous

**Table 1. Click to enlarge**

Various staging systems for hypertensive retinopathy have been developed. One that has been widely used in more recent years was presented by Wong et al<sup>13</sup> (**Table 1**). Optometrists play an important role in the treatment of patients with hypertension and knowing how to effectively manage these patients is crucial (**Table 2**). The information outlined in Tables 1 and 2 can aid the eyecare provider in grading retinopathy, educating the patient on the likely target organ damage based on ocular findings, and directing appropriate timely referrals and follow-up visits. For example, when mild retinopathy is present, it indicates chronic hypertension and does not require as urgent of a referral as moderate hypertensive retinopathy, which represents an acute rise in blood pressure and similar vascular damage occurring in the brain, heart and kidneys.<sup>13,14,18</sup> Optic nerve swelling is most associated with mortality and renal failure and therefore is a true medical emergency.<sup>13,15</sup>



Treatment of hypertensive retinopathy is typically controlling the blood pressure with medication. If blood pressure has not been elevated for a prolonged period and is controlled promptly, retinal blood vessels may return to a normal state with no permanent changes.<sup>14,20</sup> If blood pressure remains elevated and hypertension is chronic, retinal findings may be irreversible even if blood pressure is subsequently brought under control.<sup>14,20</sup>

#### Assessment of learning objectives

The assessment of the learning objectives for this teaching case report can be accomplished in several ways. Students presented with fundus photos should be able to describe the photos, including normal and abnormal findings of the retinal vasculature, optic nerve and macula as well as grade any hypertensive changes. PowerPoint slide quizzes are an option for testing students' knowledge. Once abnormal findings are identified, students should be queried on differential diagnosis along with what additional testing should be performed to determine the underlying disease and any associated conditions. Students should also be assessed on their ability to describe and recognize a hypertensive crisis and what organs can be damaged from hypertension. Case-based discussions are a good platform for helping students work through the differential diagnoses and management. In this report, fluorescein angiography and fundus autofluorescence were addressed as having a role in the diagnosis and management of hypertensive retinopathy; students can be evaluated for their knowledge of each of these tests and should be able to describe images in detail and describe normal and abnormal retinal and choroidal circulation. Role-playing simulations can help students meet patient education and management expectations.

#### Conclusion

Optometrists play an important role in the management of patients with systemic arterial hypertension. Ocular manifestations vary, and prompt recognition and accurate diagnosis are crucial for optimizing both the ocular and systemic health of the individual.

#### References

1. Hayreh SS, Servais GE, Viridi PS. Fundus lesions in malignant hypertension. VI. Hypertensive choroidopathy. *Ophthalmology*. 1986;93(11):1383-1400.
2. Bhargava M, Ikram MK, Wong TY. How does hypertension affect your eyes? *J Hum Hypertens*. 2012;26(2):71-83.
3. Hammond S, Wells JR, Marcus DM, Prisant LM. Ophthalmoscopic findings in malignant hypertension. *J Clin Hypertens*. 2006;8(3):221-223.
4. Ramezani A, Saberian P, Soheilian M, et al. Fundus autofluorescence in chronic essential hypertension. *J Ophthalmic Vis Res*. 2014 Jul-Sep;9(3):334-8.
5. Bourke K, Patel R, Pisant M, Marcus DM. Hypertensive choroidopathy. *J Clin Hypertens*. 2004 Aug;6(8):471-2.
6. Fraser-Bell S, Symes R, Vaze A. Hypertensive eye disease: a review. *Clin Exp Ophthalmol*. 2017;45(1):45-53.
7. Schechtman DL, Falco LA. Hypertension: more than meets the eye. *Review of Optometry*. 2007 Sept 15;144(9).
8. Moser M, Papademetriou V, Pickering TG, Sica DA. Hypertension treatment guidelines. *J Clin Hypertens*. 2004 Aug;6(8):452-457.
9. Ugarte M, Horgan S, Rassam S, Leong T, Kon CH. Hypertensive choroidopathy: recognizing clinically significant end-organ damage. *Acta Ophthalmol*. 2008 Mar;86(2):227-228.

**TABLE 2**  
Hypertensive Crisis Management by Optometrists

	Severe Hypertension	Hypertensive Urgency	Hypertensive Emergency
	Urgent	Urgent	Emergent
Blood pressure	> 180/110 mmHg	> 180/120 mmHg	> 180/120 mmHg
Clinical findings	no acute TOD, + mild HTN, + HTN-associated ocular findings, may have headaches	+ moderate HTN retinopathy, ± headaches and/or dyspnea, peripheral edema	papilledema w/ moderate HTN retinopathy, chest pain, severe dyspnea, headache, altered mental status, ± focal neurological deficit
Referral	patient's PCP consultation	patient's PCP consultation	emergency department or call 911
Physician setting	outpatient, long-acting oral medical treatment needed	usually outpatient, may advise sending to PCP's office or ED, oral medication with rapid onset needed	inpatient, ICU, intravenous medication needed
Treatment timeline	BP control within 3-7 days	BP control within 24-72 hours	immediate BP reduction, titrated and decreased by 15-25% within 2 hours, ICU release once 140/90 mmHg
Recommended optometric follow-up	1-3 months	1 month	1 month after release from hospital

From Meitz et al.<sup>11</sup> Wong et al.<sup>12</sup> Wong et al.<sup>13</sup>

HTN = hypertension; BP = blood pressure; TOD = target organ damage; PCP = primary care provider; ED = emergency department; ICU = intensive care unit

**Table 2. Click to enlarge**

10. Schmieder RE. End organ damage in hypertension. *Dtsch Arztebl Int.* 2010 Dec;107(49): 866-73.
11. Hayreh SS, Jonas JB. Appearance of the optic disk and retinal nerve fiber layer in atherosclerosis and arterial hypertension: an experimental study in rhesus monkeys. *Am J Ophthalmol.* 2000 Jul;130(1):91-96.
12. Meetz R, Harris T. The optometrist's role in the management of hypertensive crises. *Optometry.* 2011;82(2):108-116.
13. Wong TY, Mitchell P. Hypertensive retinopathy. *N Engl J Med.* 2004 Nov 25;351(22):2310-7.
14. Luo BP, Brown GC. Update on the ocular manifestations of systemic arterial hypertension. *Curr Opin Ophthalmol.* 2004 Jun;15(3):203-210.
15. Wong TY, McIntosh R. Hypertensive retinopathy signs as risk indicators of cardiovascular morbidity and mortality. *Br Med Bull.* 2005 Sep 7;73-74:57-70.
16. Hayreh SS. Ocular vascular occlusive disorders. 1st ed. Switzerland: Springer International Publishing; 2015:409-410.
17. Choroidal perfusion abnormalities [Internet]. San Francisco: American Academy of Ophthalmology; c2017 [cited 2017 August 14]. Available from: <https://www.aao.org/bcscsnippetdetail.aspx?id=bb9a0c9a-4a9c-488a-b28d-52cab794fc30>.
18. Mandava N, Yannuzzi LA. Vitreoretinal disease: the essentials. New York, NY: Thieme; 1999:193-209.
19. Gerstenblith AT, Rabinowitz MP. The Wills eye manual, 6th ed. Philadelphia, PA: Wolters Kluwer Health/Lippincott Williams & Wilkins; 2012:308.
20. Tso MO, Jampol LM. Pathophysiology of hypertensive retinopathy. *Ophthalmology.* 1982 Oct;89(10):1132-1145.
21. Hayreh SS, Servais GE, Virdi PS. Fundus lesions in malignant hypertension. VI. Hypertensive choroidopathy. *Ophthalmology.* 1986 Nov;93(11):1383-400.
22. Wolffsohn JS, Hurcomb PG. Hypertension and the eye. *Curr Hypertens Rep.* 2002 Dec;4(6):471-6.
23. Nwankwo T, Yoon SS, Burt V, Gu Q. Hypertension among adults in the United States: National Health and Nutrition Examination Survey, 2011-2012. NCHS Data Brief, No. 133. Hyattsville, MD: National Center for Health Statistics, Centers for Disease Control and Prevention, US Dept of Health and Human Services; 2013.
24. Farley TA, Dalal MA, Mostashari F, Frieden TR. Deaths preventable in the U.S. by improvements in use of clinical preventive services. *AM J Prev Med.* 2010;38(6):600-9.
25. Siegrist A. Beitrag zur Kenntnis der Arteriosklerose der Augengefasse. In: IXth International Congress on Ophthalmology. 1899:131-9.
26. Klien BA. Ischemic infarcts of the choroid (Elschnig spots). A cause of retinal separation in hypertensive disease with renal insufficiency. A clinical and histopathologic study. *Am J Ophthalmol.* 1968 Dec;66(6):1069-74.
27. Brown M. Ocular manifestations of systemic hypertension. *Optometry Times.* 2013 June 19.
28. Kovach JL. Hypertensive optic neuropathy and choroidopathy in an 18-year-old woman with renal failure. *Retin Cases Brief Rep.* 2010 Spring;4(2):187-9.
29. Hayreh SS. Blood supply of the optic nerve head. *Ophthalmologica.* 1996;210(5):285-95.



Dr. Richwine, a graduate of Indiana University School of Optometry, is an optometrist in Charlotte, N.C. She is an Associate Professor and educates optometry externs and optometry residents.

Dr. Mah [[diana.mah@va.gov](mailto:diana.mah@va.gov)], a graduate of the Pennsylvania College of Optometry, is an optometrist in Winston Salem, N.C.

Dr. Mercado, a graduate of the Illinois College of Optometry, is an optometrist in Hickory, N.C.