OPTOMETRIC EDUCATION

The Journal of the Association of Schools and Colleges of Optometry

Volume 46, Number 3
Summer 2021

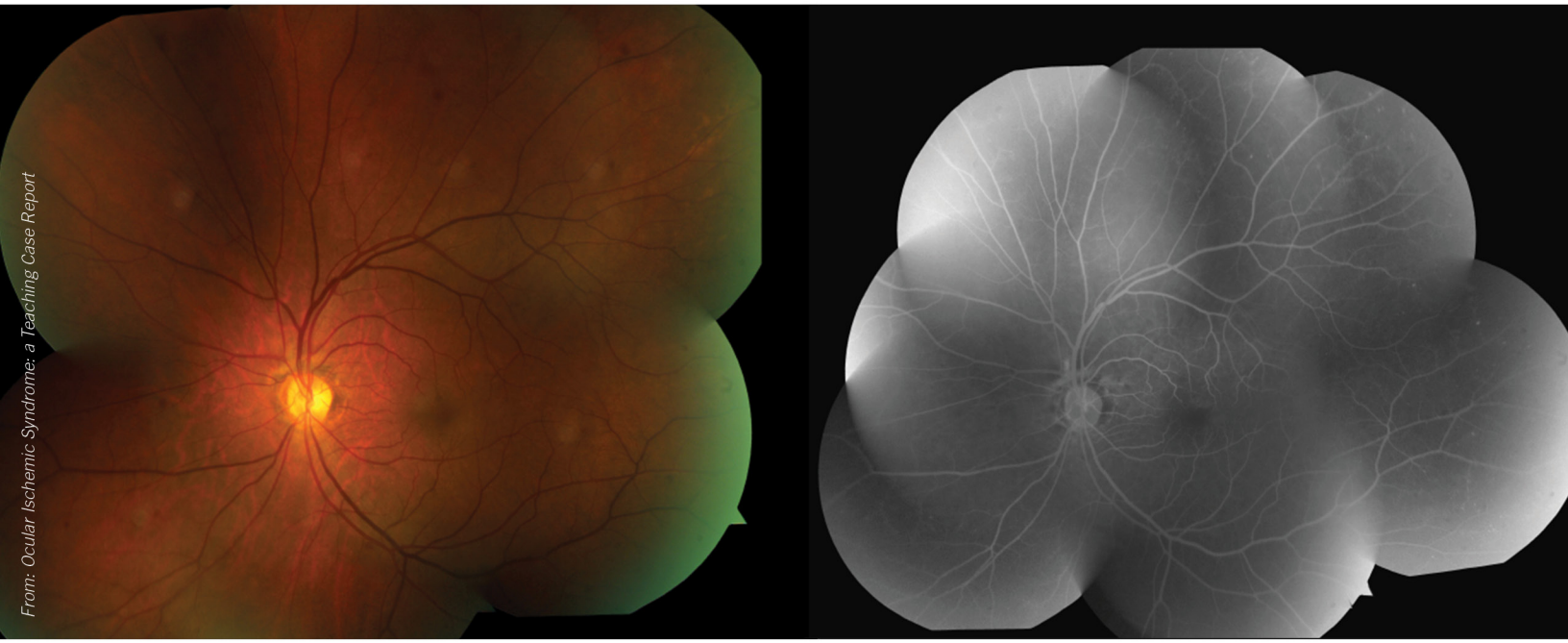

From: Ocular Ischemic Syndrome: a Teaching Case Report

ALSO INSIDE

ASCO ASSOCIATION *of* SCHOOLS *and* COLLEGES *of* OPTOMETRY

Table of Contents

Introducing Educator's Toolkit, a Teaching Resource for Optometric Faculty

Keshia S. Elder, OD, MS, MS, FAAO | Optometric Education: Volume 46 Number 3 (Summer 2021)

PDF of Article

Keshia S. Elder, OD, MS, MS, FAAO

As optometric educators, we are not necessarily trained as teachers. Rather, we are subject matter experts who are expected to effectively teach. As most of us know, this is challenging. We tend to focus on maintaining our clinical competencies, which leaves less time to spend advancing our instructional competencies. Although I am formally trained in secondary education, in my 14 years in optometric education I have often found myself wondering what I can do to improve my teaching effectiveness.

To help all of us fulfill our dual responsibility to be doctors and teachers, *Optometric Education* is launching a new feature called "Educator's Toolkit." To achieve our essential learning outcomes, we must have knowledge of sound teaching theories and methods. Sometimes the hardest part of acquiring and implementing such knowledge is just getting started. This is where Educator's Toolkit comes in. It is meant to serve as an information and resources hub. Educators can use it to stay abreast of current trends in higher education pedagogy and to access ideas and useful tools that can be applied to optometric teaching.

We begin Educator's Toolkit in this issue of the journal by exploring principles and techniques for eLearning, a topic, which, thanks to COVID-19, is more relevant than ever.

Follow

Share

Call for Papers for Theme Edition: Diversity and Cultural Competency in Optometry

| Optometric Education: Volume 46 Number 3 (Summer 2021)

PDF of Article

The population continues to become more diverse, and optometry must be able to meet the cultural, ethnic, racial, gender and linguistic needs of patients.

Optometric Education is inviting authors to submit scholarly papers addressing related themes such as diversity, cultural competency, gender issues and cultural awareness.

The deadline to submit papers for this theme edition is **Sept. 1, 2021**

For more information, e-mail journal Associate Editor Keshia S. Elder, OD, MS, MS, FAAO, or journal Editor Aurora Denial, OD, FAAO, DipOE.

Follow

Share

The Four-Year Optometric Education Program: Something's Got to Give

Aurora Denial, OD, FAAO, DipOE | Optometric Education: Volume 46 Number 3 (Summer 2021)

PDF of Article

Aurora Denial, OD, FAAO, DipOE

Optometric scope of practice has evolved significantly in the past 46 years. Originally limited to refractive and binocular conditions,[1] the scope expanded by the mid-1970s (when the first four states had granted optometrists the authority to use diagnostic drugs[2]) and broadened again with the addition of prescribing privileges for therapeutic drugs. Today, optometrists are primary eyecare professionals[1] with significant responsibilities in diagnosis and treatment of many ocular conditions and diagnosis of some systemic diseases as well as timely referrals, follow-up care and patient education. In 2021, scope of practice includes topical treatment of glaucoma in all 50 states, use of oral steroids in 39 states, use of lasers to treat ocular conditions in eight states, and use of injectables in 20 states.[3]

The seismic changes in the scope of optometric practice have been accompanied by additional obligations to practice evidence-based medicine and continuously acquire new knowledge about diseases and diagnostic and treatment technologies. Despite this staggering amount of new information and increased responsibility, the education of optometrists has remained a four-year postgraduate program. Is this sustainable given that scope of practice will continue to expand and new information and technology will continue to emerge? How can we achieve in four years the goal of a high-quality, relevant education that is not mentally overloading for students?

The Solution May Lie in Letting Go

To effectively prepare future optometrists via the current four-year postgraduate program, educators will have to let go. Perhaps we start with eliminating some course material. Is there any course material that could be taught before entry into optometry school, for example in undergraduate courses (prerequisites) or a brief virtual summer curriculum completed independently before matriculation?

We must also acknowledge that the optometrist's role has evolved from primarily gathering data to primarily exercising analytical skills. Should we let go of teaching some data-gathering technical skills and focus on critical-thinking and analytical skills? Do we need to teach binocular indirect ophthalmoscopy if a widefield scanning laser ophthalmoscope is available? Students may be better served by faculty teaching the skills involved with interpreting the images. In didactic teaching, a shift away from specific information and toward key concepts may be helpful. Key concepts provide a broader understanding of material, which can then be applied to different scenarios.

Students may need to play a role, too. They may need to change their perceptions and expectations of optometric education. The current expectation is that the curriculum and faculty will provide all the information necessary for success in practice. This sets up a passive system of learning in which students receive and internalize the instructor's knowledge. Instead, optometric education should provide students with the skills, tools and knowledge they need for lifelong independent learning. This would require students to assume responsibility for their learning and take charge of learning in an active manner. It would free up time in the curriculum and give students the skills needed in the real world.

Change is Difficult; Collaboration Can Help

The response to optometry's challenge of how to provide a relevant education in a reasonable amount of time is not straightforward. The idea of not teaching skills that have been the foundation and identity of our profession for years is mindboggling. Lecturing and not providing every bit of information on a particular subject is scary. All healthcare professions are facing these issues. Therefore, we should collaborate with them to develop evidence-based solutions. We should also strive to conduct well-designed studies to contribute to the literature to help guide all educators.

References

1. Baldwin WR. Tomorrow’s challenge. Optometric Education. 1975 Spring;1(2):74-9.
2. Filer C. Pacific University in profile: generations of leadership. Optometric Education. 1975 Summer-Fall;1(3):113-15.
3. Nguyen Q, Goldberg, Geller M. Optometry Scope of Practice in the United States [Internet]. San Diego, CA: Eyes On Eyecare; c2021 [cited 2021 July 8]. Available from: https://eyesoneyecare.com/resources/optometry-scope-of-practice-un-ted-states/.

Follow

Share

Principles, Techniques and Tools that Promote Successful eLearning

Keshia S. Elder, OD, MS, MS, FAAO | Optometric Education: Volume 46 Number 3 (Summer 2021)

PDF of Article

Keshia S. Elder, OD, MS, MS, FAAO

During the COVID-19 pandemic, eLearning — learning that occurs through electronic means — increased exponentially. Many optometric educators found themselves teaching online classes for the first time in their careers. We were thrust into learning new instructional delivery techniques and new technologies in a very short time. We experimented with learning management systems and figured out how to use electronic teaching aids that we had not found time to learn in the past. Now that we have cleared the initial hurdles of adapting to modified teaching platforms, we can focus on maximizing their effectiveness as teaching tools so our students are successful eLearners.

First Things First

Compared with traditional instruction, eLearning has many advantages. It is customizable and more broadly accessible. It is self-paced for students, and both they and their teachers can benefit from learning analytics. However, an eLearning course must do more than look good. It must be effective.

When considering the design of an eLearning course, one must answer several foundational questions. For example, it is important to consider your audience and the learning goals, which will inform the delivery system. The Learning Rooms recommends five questions to ask yourself when developing an eLearning course **(Figure 1)**.

Figure 1.*Click to enlarge*

Incorporation of eLearning Principles

Design and delivery of effective eLearning encompass a variety of strategies, including the application of eLearning principles, such as those developed by Mayer **(Table 1)**. According to Mayer's Cognitive Theory of Multimedia Learning (eLearning is a form of multimedia learning), there are dual channels (auditory and visual) for processing words and pictures, and people have a limited capacity to actively process the information in the channels.[1] Application of eLearning principles reduces the cognitive load, which frees the working memory to be used for learning and helps to ensure the instruction aligns with cognitive learning processes.

I wonder how many optometric educators are familiar with eLearning principles, such as the redundancy principle, the coherence principle or behavioral vs. psychological engagement? Based on your teaching experience, how would you respond to the following questions?

- Do you believe adding elements such as pictures, graphics, sounds or music to a lesson to make the presentation "pop" engages students and facilitates learning? I would have responded yes. In fact, as Harp and Mayer found, extraneous pictures can interfere with learning.[2]
- Do you think students learn principles more effectively by playing a game in which they apply the principles or by using a slide presentation? My guess would have been a game, but in a study by Adams et al., students who learned with games performed worse than students who learned with slideshows on several parameters, including retention and post-test scores.[3] Interestingly, this finding aligns with the idea that psychological engagement and not behavioral engagement is the driver of cognitive learning.[1]
- In a narrated animation, do you think having the narrated text on-screen simultaneously reinforces what students are learning? Again, I would have said yes. However, several researchers, including Austin[4] and Moreno and Mayer,[5] found that students performed better when they did not have on-screen text to accompany the narrated animation.

Andrew DeBell, a training consultant with Water Bear Learning, has written an informative and well-illustrated article on how to apply Mayer's 12 Principles of Multimedia Learning. Other experts in eLearning have also created helpful resources, including websites and podcasts, for faculty **(Table 2)**.

TABLE 1
Examples of Multimedia / eLearning Principles

Multimedia Principle	Words and pictures are better than pictures alone
Contiguity Principle	Text and spoken word should align with corresponding images
Redundancy Principle	Explain visuals with words in audio or text but not both
Modality Principle	Present words as audio rather than on-screen text
Coherence Principle	Adding extra material can hurt learning
Segmenting	Break a continuous lesson into smaller segments
Pre-training	Learners should know characteristics and names of key concepts
Personalization	Conversational style, polite wording and friendly human voice
Embodiment	Use online agents with human movements and gestures

Source: Clark RC, Mayer RE. e-Learning and the science of instruction: proven guidelines for consumers and designers of multimedia learning. 4th ed. Hoboken, NJ: John Wiley & Sons, Inc.; 2016.

Table 1.*Click to enlarge*

TABLE 2
Additional Resources

Websites	Podcasts	Texts
The eLearning Coach is the website of Connie Malamed, a learning experience design consultant theelearningcoach.com	Strategies for Effective Online Instruction, a conversation with Michelle D. Miller, author of Minds Online: Teaching Effectively with Technology (**eLearning Coach 036**) theelearningcoach.com/podcasts/36	Clark RC, Mayer RE. e-Learning and the Science of Instruction: Proven Guidelines for Consumers and Designers of Multimedia Learning (John Wiley & Sons, Inc., 2016)
The K. Patricia Cross Academy is dedicated to supporting faculty by offering free instructional videos and downloadable resources kpcrossacademy.org	**Online Course Coach** by Jeff Long, who helps companies, organizations and entreprenuers create engaging online courses onlinecoursecoach.com/category/podcast	Miller MD. Minds Online: Teaching Effectively with Technology (Harvard University Press, 2014)
	Rod's Pulse Podcast, a technology and eLearning podcast by Rodney B. Murray, PhD www.rodspulsepodcast.com	

Table 2.*Click to enlarge*

eLearning Authoring Tools

For help creating eLearning courses, educators can use an eLearning authoring tool. An eLearning authoring tool is software used for developing digital content. A variety of authoring tools, which are cloud-based or desktop-based and different in complexity and price, are available. They range from something as simple as the ability to add hotspots to an image (click an area on an image and an action happens), to stand-alone course authoring software, to a learning management system with built-in authoring software. Many eLearning authoring tools, including these, offer a free trial:

Adobe Captivate

- Desktop-based course authoring software
- 30-day free trial available
- Student and teacher price: approximately $400 one-time fee or $34/month subscription

Articulate 360

- Family of eLearning course authoring tools that includes desktop and web-based applications
- Includes Storyline 360 and Rise 360
- 60-day free trial available
- Academic price: approximately $500/year/user on a personal plan; $650/year/user on a team plan

Gomo

- Cloud-based eLearning software
- 21-day free trial available
- Pricing: approximately $1,000/year/user; $3000/year for a team up to four

Adapt

- Open-source web-based course authoring tool
- Price: free

Camtasia

- Screen capture and video editing software suite
- Used in conjunction with eLearning authoring software
- 30-day free trial available
- Education pricing: approximately $170 one-time fee

The Cardinal Rule

While an array of technologies can be incorporated into eLearning courses and used in creating them, it's important to remember they are the means, not the end. If not used properly, technology does not support learning. The key to successful eLearning and teaching, as Krippel et al. state in their paper "Multimedia use in Higher Education: Promises and Pitfalls," is

that pedagogy must drive education technology, not the other way around.[6] It is vital to understand and implement this concept as we continue to explore instructional approaches for online settings.

References

1. Clark RC, Mayer RE. e-Learning and the science of instruction: proven guidelines for consumers and designers of multimedia learning. 4th ed. Hoboken, NJ: John Wiley & Sons, Inc.; 2016.
2. Harp SF, Mayer RE. How seductive details do their damage: a theory of cognitive interest in science learning. Journal of Educational Psychology. 1998;90(3):414-434.
3. Adams DM, Mayer RE, MacNamara A, Koenig A, Wainess R. (2012). Narrative games for learning: testing the discovery and narrative hypotheses. Journal of Educational Psychology. 2012;104(1):235-249.
4. Austin KA. Multimedia learning: cognitive individual differences and display design techniques predict transfer learning with multimedia learning modules. Comput Educ. 2009 Dec;53(4):1339-1354.
5. Moreno R, Mayer RE. Verbal redundancy in multimedia learning: when reading helps listening. Journal of Educational Psychology. 2002;94(1):156-163.
6. Krippel G, McKee AJ, Moody J. Multimedia use in higher education: promises and pitfalls. Journal of Instructional Pedagogies. 2010 March;2.

Follow

Share

Student Award in Clinical Ethics: 2021 Winning Essay Explores Potentially Thorny Issue

| Optometric Education: Volume 46 Number 3 (Summer 2021)

PDF of Article



Tam Tran, OD

ASCO and its Ethics Educators Special Interest Group are pleased to announce Tam Tran, OD, as the winner of the 2021 Student Award in Clinical Ethics. Dr. Tran graduated this year from Illinois College of Optometry and plans to make binocular vision a focus of his career. His winning essay, "The Ethical Muddle of Sick Notes: Can We Do Better?" appears below.

The Student Award in Clinical Ethics competition, sponsored by Alcon, is open to optometry students during any point in their professional program at an ASCO-affiliated school or college of optometry. The winner receives an engraved plaque and $1,000.

ASCO thanks all students who submitted essays this year.

****

The Ethical Muddle of Sick Notes: Can We Do Better?

By Tam Tran, OD

To utilize the benefit of paid leave or be absent from school for a health reason, employees and students are often required to present a "sick note" from a doctor. It is not uncommon for patients to ask their optometrists to provide such a note. Many requests for sick notes are clinically legitimate, but they can be misused, too. For example, patients could withhold information to prolong diagnosis or treatment. In many cases, the issue is not a perplexing medical decision, but rather an immoderate demand. Thereby, optometrists can find themselves in a quandary: grant the request for a note to "proactively serve the needs of the patient," as stated in the American Optometric Association (AOA) Standards of Professional Conduct,[1] or deny the request based on clinical judgment? Furthermore, should doctors alone carry the responsibility of deciding whether a patient should stay home or return to work or school?

Case Description

JM, a 52-year-old law enforcement officer, presented for severe dry eye OU. He reported eye irritation, photophobia, foreign body sensation, tearing and blurry vision. His best-corrected visual acuity was 20/30 OU. Slit lamp examination showed 3+ superficial punctate keratitis (SPK) OU. JM was counseled to use preservative-free artificial tears, omega-3 fatty acid supplements and warm compresses. He asked for and received a sick note due to being sensitive to light, which prohibited him from driving on duty.

During the follow-up visit one week later, JM said he had been complying with the treatment recommendations, but his condition was unchanged. Tobramycin/dexamethasone eye drops (Tobradex) were added to the treatment regimen. JM requested and received another sick note for sick leave.

During the second-week follow-up appointment, JM reported an improvement in his eye condition, but said he was still experiencing mild-to-moderate discomfort and photophobia. He was advised to use supportive therapies such as sunglasses and artificial tears for symptom relief while on duty. JM said he felt unsafe to drive and persisted in asking for another sick note, which was provided.

During the third-week follow-up, JM's condition was further improved. Slit lamp examination showed 1-2+ SPK OU and his best-corrected visual acuity was 20/20-2 OU. The attending optometrist cleared him for work. JM, however, insisted that he felt unsafe to drive and wanted another sick note.

Discussion

At this point, JM had taken three weeks off from work on sick leave. Based on clinical examination, his eye condition had improved enough to allow him to resume working. Yet, he still felt unsafe to drive on duty. As previously noted, optometrists have a duty to proactively serve the needs of their patients; however, they also have an obligation "to conduct themselves with integrity."[1] This requires us to walk a fine line between advocating for patients' best interests and being truthful in sick notes for patients' work or school. Was JM's unease caused by an unknown ailment, or was he taking advantage of his employer's sick leave policy? Given that no further eye abnormality was observed, additional examination or referral might have only put an unnecessary financial burden on the patient. On the other hand, blatantly accusing him of sick leave abuse would be premature and damaging to the optometrist-patient relationship. With no evidence either way, is it ethical to continue granting JM sick notes as he continues to report eye discomfort?

The ethics argument hinges on the choice between giving patients what they want or offering what they and society need. To tackle this dilemma, we need to uncover its root cause. It has become standard practice for society to demand medical documentation for sick leave. In regard to vision problems, optometrists have become an authority for providing such documentation, for example, on school forms and sick notes. However, because we also have an ethical obligation to act in the best interest of patients, we are put in the odd position of impartial arbiters between patients and their work or school. So far, except for driving restrictions and legal blindness, which are governed by laws, deciding for society who is "worthy" of what vision-related excuses is solely at optometrists' discretion. Such a situation is destined for trouble.

In fact, this demand for optometrists to "certify" everything eye-related has created a huge burden on both optometrists and patients. As defined in the AOA's Code of Ethics, it shall be the duty of all optometrists "to conduct themselves as exemplary citizens and professionals with honesty, integrity, fairness, kindness, and compassion,"[2] so whatever we write in the note is deemed truthful and accurate by the public. But what if we are not given the whole story? It swings the door wide open for sick leave abuse. As to patients, the policy of mandatory doctor's notes for sick days adds little to patients' well-being. They should make their own decisions on whether and when their illness requires medical attention. Unfortunately, the fear of losing jobs forces patients to either continue working instead of resting, or to pay extra money for a clinic visit merely to get a sick note.

To address this dilemma, society, not doctors, should decide conditions for coping with short-term illness. Ideally, society would push workplaces to provide paid sick leave without the need for a sick note. Currently, no U.S. federal law mandates companies to provide paid sick leave.[3] As of this year, only 13 states and Washington, DC, have enacted laws requiring paid sick leave.[4] Studies have shown that paid sick leave is cost-effective because it reduces employee turnover and also reduces the risk of exposing the public to infectious diseases, especially in a pandemic like COVID-19.[5,6] Patients with paid sick days have the autonomy to decide how to spend their health benefit and when a visit to the optometrist is necessary. Reducing the number of office visits scheduled only to request a sick note would better allocate optometrists' resources to serving patients who are truly in need of care.

This is not to argue that the doctor's note should be abolished altogether. On the contrary, optometrists can play an essential role in supporting informed decision-making by workplaces and schools. In place of sick notes, a better alternative may be "fit notes," which England has been using since 2010.[7] Such notes focus on what patients are capable of doing at work based on clinical examination and let the workplace decide what to do.

Moreover, optometrists need to educate patients through effective communication. According to the AOA's Standards of Professional Conduct, "telling the truth is a necessary component of a trusting optometrist-patient relationship."[1] When facing unreasonable demands from patients, optometrists should educate patients about the difference between facts and feelings, as well as the limitation of optometry in decision-making for social dependencies. Patients need to understand that a reasonable request for a sick note is when optometrists need not create "sickness" for patients where there are just conflicting opinions.

Case Resolution

It was not irrational for JM to be concerned about going back to work. His police work entailed extended outdoor activities (e.g., driving vehicles and directing traffic). Dry eye symptoms such as photophobia could increase the risk of accidents. In fact, per the Law Enforcement Officer Motor Vehicle Safety Report, motor vehicle-related incidents are a leading cause of line-of-duty deaths for law enforcement officers in the United States,[8] most of which occurred during daylight, in clear weather, and at speeds lower than 50 mph.[9] Nevertheless, JM's dry eye had significantly improved and was deemed to be of minimal

interference to his job and low risk for driving. Per the AOA Standards of Professional Conduct, “When optometrists provide expert testimony within a judicial or administrative action, the testimony should be balanced, fair, and truthful based on scientific and clinical knowledge.”[1] Given the ethical obligations in this case, it would have been inappropriate to continue advocating for JM’s sick leave.

Because the sick leave policy at JM’s workplace cannot waive a sick note, we decided to take the fit-note approach and let his employer decide how to accommodate him on duty. Following the Standards of Professional Conduct that optometrists have the duty “to treat patients without prejudice,” and “to involve the patient in care and treatment decisions in a meaningful way, with due consideration of patient’s needs, desires, abilities and understanding,”[1] we listened to JM’s concerns and educated and reassured him on his readiness to work. We involved JM in determining what he could do and could not do. For the interest of public safety, JM was encouraged to start office work with no vehicle use in the near term. He was also instructed to continue using artificial tears and warm compresses and scheduled for a follow-up visit. A fit note was provided to advise his workplace to excuse JM from operating vehicles and to allow him to perform indoor office tasks.

Conclusion

The requirement for a doctor’s note to take sick leave has many negative social implications. Because optometrists are ethically obligated to serve in patients’ best interests, positioning optometrists as objective authorities often leads to ethical dilemmas. Our society needs to legislate and expand paid sick leave without the need of a sick note, which affords patients the autonomy of seeking truly needed medical attention and improves their overall well-being. Optometrists ought to serve as advisors, not judges, to guide workplaces to make informed decisions on how to support employees during and after sickness.

References

1. Standards of Professional Conduct [Internet]. St Louis, Mo: American Optometric Association; [cited 2021 July 12]. Available from: https://www.aoa.org/AOA/Documents/About%20the%20AOA/Ethics%20%26%20Values/Standards-of-Professional-Conduct_Adopted-June-2011.pdf.
2. Code of Ethics [Internet]. St. Louis, Mo: American Optometric Association; [cited 2021 July 12]. Available from: https://www.aoa.org/about-the-aoa/ethics-and-values?sso=y.
3. Sick Leave [Internet]. Washington, DC: U.S. Department of Labor; [cited 2021 Jan 28]. Available from: https://www.dol.gov/general/topic/workhours/sickleave.
4. Paid Sick Leave. [Internet]. Washington, DC: National Conference of State Legislatures; c2021 [cited 2021 Jan 28]. Available from: https://www.ncsl.org/research/labor-and-employment/paid-sick-leave.aspx.
5. Lovell V. Valuing Good Health: An Estimate of Costs and Savings for the Healthy Families Act, Publication #B248, April 2005 [Internet]. Washington, DC: Institute for Women’s Policy Research; [cited 2021 July 12]. Available from: https://iwpr.org/iwpr-general/valuing-good-health-an-estimate-of-costs-and-savings-for-the-healthy-families-act-2/.
6. Maclean JC, Pichler S, Ziebarth NR. Mandated Sick Pay: Coverage, Utilization, and Welfare Effects, Working Paper 26832, March 2020 [Internet]. Cambridge, MA: National Bureau of Economic Research; c2021 [cited 2021 July 12]. Available from: https://www.nber.org/papers/w26832.
7. Fit Note [Internet]. London, England: Department for Work and Pensions; [cited 2021 Jan 28]. Available from: https://www.gov.uk/government/collections/fit-note.
8. Law Enforcement Officer Motor Vehicle Safety [Internet]. Centers for Disease Control and Prevention, National Institute for Occupational Safety and Health; [cited 2021 Jan 28]. Available from: https://www.cdc.gov/niosh/topics/leo/default.html.
9. Tiesman HM, Heick RJ. Law Enforcement Officer Motor Vehicle Safety: Findings from a Statewide Survey [Internet]. Centers for Disease Control and Prevention, National Institute for Occupational Safety and Health; [cited 2021 Jan 28]. Available from: https://www.cdc.gov/niosh/docs/2015-101/pdfs/2015-101_v2-.pdf.

Follow

Share

System Dynamics Simulation of the Eyecare Workforce Needs in the Dominican Republic

Héctor C. Santiago, OD, PhD, FAAO | Optometric Education: Volume 46 Number 3 (Summer 2021)

PDF of Article

Background

The determination of needs in the eyecare workforce of a nation is critical for the education, training and allocation of optometrists, ophthalmologists and other ophthalmic personnel. Given the multiple interacting variables, it is often challenging to predict these needs.[1-2] The Dominican Republic is a country in the Caribbean region with a population of approximately 11 million people.[3] The prevalence of blindness in the 50 and older age group in the Dominican Republic is 2.1%.[4] A recent study in a clinical population in Pedernales, a Dominican town at the border with Haiti, found an overall presenting prevalence of visual impairment of 48.2%, which was reduced to 15.8% after refractive correction. Among the patients 50 years and older, the presenting visual impairment was 60.2%, the highest reported in Latin America. The prevalence of impairment was reduced to 23.8% with eyeglasses, indicating the need for optometric care.[5-6]

In the Dominican Republic, as in the United States, ophthalmologists are medical doctors with additional residency training in ophthalmology. They may perform refractions, diagnose and manage ocular disease, and perform ocular surgeries. In 2019, the Dominican Republic had 350 practicing ophthalmologists.[7-8] Medical education is regulated and accredited by the Ministry of Higher Education, Science and Technology (MESCyT), and medical practice is regulated by the Colegio Medico Dominicano (Dominican Medical Association).[9-10]

The practice of optometry in the Dominican Republic is not regulated or supervised as a health profession by any government agency. Optometric practitioners pay taxes on the sale of eyeglasses and contact lenses as businesses. There are approximately 500 optometric practitioners in the nation.[11] In the absence of professional optometric regulation, those without any formal optometric training are the majority of practitioners (empiricists) who perform autorefraction and dispense eyeglasses. This group has only a high school education. A second group of optometric practitioners (approximately 20) received limited technical training after high school (one to two years), previously at the Armando Espaillat Cabral Institute and most recently at the Universidad de la Tercera Edad. They perform refractions (retinoscopy and subjective) and dispense eyeglasses and contact lenses. A third group — composed of only four university-trained practitioners — received professional optometric degrees (four to five years university education) outside the Dominican Republic and perform refractions and external and internal eye examinations.[a] Since 2019, optometric education is accredited by the MESCyT.[12]

The Dominican Optometric Association (ASODOP), founded in 1991, is an organization that represents about 300 optometric practitioners.[11] ASODOP holds annual meetings with educational programs for its members. In 2012, the association promoted an agreement between Inter American University of Puerto Rico School of Optometry (IAUPR) and the Autonomous University of Santo Domingo (UASD) to establish a professional optometry program. UASD canceled the agreement in 2016 before the opening of the program. In 2018, ASODOP supported a new agreement between IAUPR and the Technological University of Santiago (UTESA), which led to establishing and opening the first professional optometry program.[13]

UTESA, founded in 1976, is the largest private university in the Dominican Republic. Its mission is to offer non-denominational higher education to students of disadvantaged economic and social backgrounds. It has eight campuses across six cities in the Dominican Republic. It offers professional degrees in the health sciences (medicine, dentistry, pharmacy, optometry, psychology, veterinary medicine, nursing), engineering, law, education, economics and business administration. The professional Bachelor of Optometry program (Licenciatura) opened in September 2019 at two UTESA campuses in the capital city of Santo Domingo. This four-year optometric curriculum has 185 credit hours, including 2,135 lecture hours and 1,440 lab hours (including patient care).[13]

System dynamics modeling has been used to forecast workforce needs in medicine, dentistry, pharmacy and social care in England, nursing in Korea and dentistry in the United States.[14-16] System dynamics has also been used to develop scientific, social, business and political models.[17] More recently, it has been applied to public health planning.[18–19] In education, it is a useful tool to promote deeper learning and critical-thinking skills among students.[20]

Saraji and Sharifabadi reviewed 28 studies on the effectiveness of system dynamics models in forecasting specific outcomes.

The studies included predictions on the demand for air travel, water, urban transportation, housing and petroleum. They also involved predictions of the housing supply, fuel and coal prices, and sales of cars. They found that system dynamics models can make accurate predictions compared to actual outcomes (less than 5% error) or more reliable forecasts than alternate methods such as multiple linear regression, exponential smoothing or artificial neural networks.[21-26]

General systems thinking postulates that a deeper understanding of systems can be obtained by examining patterns of behavior over time. These behaviors result from the interaction among many variables through feedback loops. Deep inside these patterns are structures and mental models of an organization. System dynamics involves simulation models using general systems theory to explore the inter-relationship among variables to produce outcomes of interest. Instead of a single snapshot, the models allow exploration of how outcomes change over time.

The present study explores the use of system dynamics to model the eyecare workforce needs in a developing country after opening its first professional optometry university program.

Methods

A system dynamics simulation model was developed using the software Vensim PLE 7.3.5 (Ventana Systems Inc.).[27,b] Vensim is available as a free version and an upgraded paid version. There are more than 50 free tutorials available on YouTube and the company's website. Vensim was developed in 1985 for large business simulation. Its functionality expanded through time with Windows and Macintosh versions and a free personal learning edition (PLE) for educational use.[28] Vensim models have been successfully applied in the pharmaceutical, financial, energy, environmental, aerospace and health scenarios.[29-32]

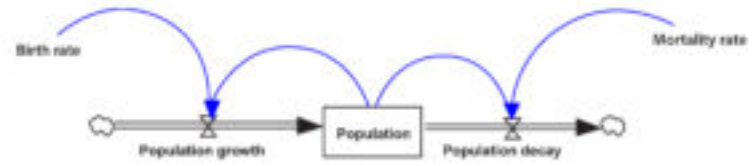

Figure 1. *A simple system dynamics simulation model for population changes using stocks, flows and feedback loops. Rectangles represent stocks. Flows are represented by pipes, flow regulators and spigots.*
Click to enlarge

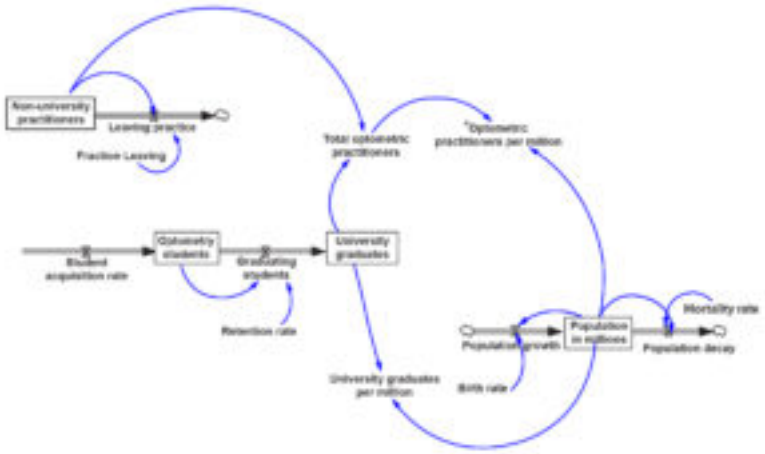

Figure 2. *The optometric workforce of Dominican Republic model using Vensim modeling software. Rectangles represent stocks. Flows are represented by pipes, flow regulators and spigots. Click to enlarge*

System dynamics models in Vensim are based on three elements: stocks, flows and feedback loops. Stocks are variables that

accumulate over time, such as "population" in **Figure 1**. Flows can increase or decrease stocks, as in the case of "population growth" (which increases "population") and "population decay" (which decreases "population") in Figure 1. Feedback loops can be reinforcing (promoting growth or decay) or balancing (promoting the achievement of the desired state).

The model is based on the initial values, rate of change and factors that affect the stocks. For example, in our optometric workforce model **(Figure 2)**, the stock "total optometric practitioners" has an initial value of 500, and it is affected by the stock "university graduates" and "non-university practitioners." The initial 500 practitioners include approximately 476 without formal optometric training, 20 with some technical training, and four with foreign university-level optometric degrees. The total number of optometric practitioners present in the Dominican Republic was acquired from the Board of the Dominican Optometric Association.[9] "University graduates" has an initial value of 0, and changes by the "student acquisition rate" (60 per year) and the university "retention rate" (80%). UTESA provided data about the admitted students per year and the new university optometry program's expected retention rates.[13] The "non-university practitioners" has an initial value of 496 and changes by the rate "fraction leaving." Finally, the "university graduates per million" variable is based on the "university graduates" and the Dominican "population in millions." The Dominican "population in millions" is based on the "birth rate" and "mortality rate." Demographic information (population, birth and mortality rates) for the Dominican Republic was obtained from the Dominican Republic Census.[3] The ratio of 100 optometrists per million of optometrists (1 per 10,000 population) in developed countries such as the United States was used as a standard for comparison.[33]

The total predicted number of ophthalmologists per million over time was based on the current number of practicing ophthalmologists, the number of new ophthalmologists, their annual attrition rate per year, and the population of the Dominican Republic. The current number of practicing ophthalmologists was obtained from the website of the Dominican Society of Ophthalmology.[7] The number of new ophthalmologists per year was supplied by the Institute Against Blindness due to Glaucoma.[8] The criteria for the recommended minimum number of ophthalmologists per million in Latin America was based on Hong et al.[34]

Model assumptions

Based on the sources listed, the following model assumptions were used:

- 500 optometric practitioners in 2019, including 476 without any formal training (empiricists), 20 with limited technical training, and four with university optometric degrees from outside the Dominican Republic
- A decrease in the number of practitioners without university training once the university program is initiated (This assumption is based on the availability of trained optometrists to substitute the empiricists and the approval of a law prohibiting optometry practice without professional education.) The model explores annual attrition rates of 0%, 5%, 10% and 20%
- 60 optometry students per year in the bachelor's program of optometry
- 80% retention rate at the school of optometry
- 350 ophthalmologists in practice in 2019
- 18 new ophthalmologists per year

Two independent models were run. The first was a simulation of the optometric workforce **(Figure 2)**, and the second was a simulation of the ophthalmologic workforce **(Figure 3)**.

Results

Figure 4 shows the total predicted number of optometric practitioners per million population for 60 years after opening the UTESA professional optometry program. The curves show how the ratio changes as the non-university practitioners (mostly empiricists) decrease by 0%, 5%, 10% and 20% annually. A ratio of 100 practitioners per million (1 per 10,000 population) will occur in 15 years with no attrition (0%) of empiricists. This ratio will occur in 24 years if the empiricists' annual attrition rate is 5% and in approximately 27 years if it is 10% or more. A short-term decline in the ratio lasting no more than five years will occur if the attrition rate is greater than or equal to 10%. After 60 years, the number of optometric practitioners will stabilize to approximately 160 per million (1 per 6,250 population) if there is no attrition of empiricists. After 60 years, it will stabilize to about 140 optometrists per million (1 per 7,000 population) if the attrition rate is 5% or more.

Figure 5 shows the predicted number of ophthalmologists per million population for the 60 years after the UTESA optometry program's opening. The curves show how this ratio changes as the number of ophthalmologists decreases (attrition rates) by 0%, 1% and 2% annually. Under all conditions, the starting point is the current (2019) ratio in the Dominican Republic of 32.5 ophthalmologists per million. If there is no attrition of ophthalmologists (0%), the ratio will maximize at 46.2 ophthalmologists per million after 31 years. With a 1% attrition rate, the ratio will be a maximum of 38.7 ophthalmologists per million after 20 years. With a 2% attrition rate, the ratio will maximize at 34.5 ophthalmologists per million after 11 years.

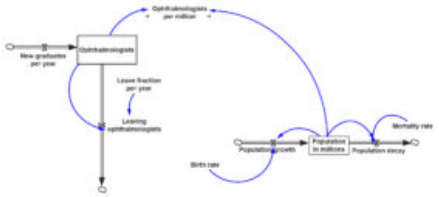

Figure 3. *The ophthalmologic workforce model of the Dominican Republic using Vensim modeling software. Rectangles represent stocks. Flows are represented by pipes, flow regulators and spigots.*
Click to enlarge

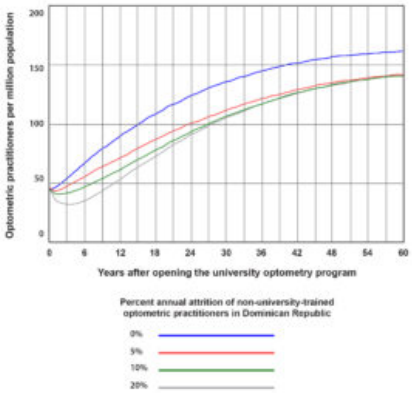

Figure 4. *Ratio of optometric practitioners per million (university-educated and non-universit--educated optometrists) in the Dominican Republic during a period of 60 years. Year 0 represents the year when the university optometry program was initiated (2019). The curves represent annual attrition rates of non-university-trained optometrists of 0%, 5%, 10% and 20%.*
Click to enlarge

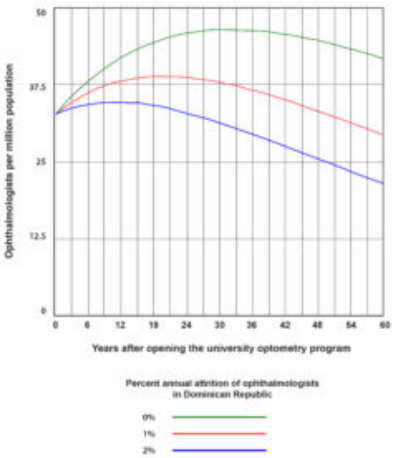

Figure 5. *Ratio of ophthalmologists per million in the Dominican Republic during a period of 60 years. Year 0 represents the year when the university optometry program was initiated (2019). The curves represent annual attrition rates of ophthalmologists of 0%, 1% and 2%.*
Click to enlarge

Discussion

The system dynamics simulation shows that if non-university-trained practitioners (mostly empiricists) can practice without restriction (0% attrition) along with university-educated optometrists, the number of optometrists per million population will achieve the United States' ratio in only 15 years. This scenario will create an oversupply of practitioners that may decrease the demand for university-educated optometrists. The public may not be able to differentiate between empiricists and trained optometrists to the detriment of primary eyecare quality. This was the experience of countries like Mexico, where the practice of the profession was unregulated until 2014.[35]

One important recommendation for the Dominican Optometric Association derived from the simulation is the promotion of legislation to prohibit optometry practice without a professional degree. The model indicates that such a law should be implemented to ensure an attrition rate of 5% or more annually among non-university-trained practitioners. The model predicts a ratio of one optometrist per 7,000 population after approximately 60 years with an attrition rate of non-university-trained practitioners of 5% or more. This ratio will create an eventual saturation that may decrease the number of applicants to the professional program or promote optometrists' migration to neighboring countries. UTESA should monitor the workforce needs in the coming years and adjust its admission policies to avoid this possible scenario.

Based on the available clinical data, the leading cause of visual impairment in the Dominican Republic is uncorrected refractive error.[5] The UTESA program must prepare its students to provide excellent refractive and functional care. The leading causes of blindness are cataracts, glaucoma and diabetic retinopathy.[4] UTESA must also prepare students for the diagnosis, treatment and management of primary ocular disease to serve the Dominican population's needs. In Colombia, an optometric therapeutic law was approved in 1997 before the country's optometry schools adequately prepared their students.[36] Legal challenges to the law required all schools to implement significant curricular changes to prepare optometrists for the expanded new role. Today, optometry is recognized by the Colombian Ministry of Health in the national eyecare programs.[37] The Colombian experience indicates that UTESA should develop, as early as possible, a broad curriculum to justify therapeutic privileges for the profession. A follow-up study should address the UTESA professional program's effectiveness in addressing the Dominican Republic population's eyecare needs.

The current (2019) ratio of ophthalmologists per million population in the Dominican Republic is 32.5. This ratio is above the minimum recommended international standard of 27 ophthalmologists per million population.[34] Nevertheless, it is well below the current (2019) ratio of 59 ophthalmologists per million population in the United States.[38] All our simulation scenarios predict that the ratio in the Dominican Republic will never achieve the United States' ratio.

In the United States, based on a survey of male ophthalmologists between 50 and 85 years of age, the annual attrition rate of ophthalmologists was about 2.7% annually.[39-40]

Because approximately half of ophthalmologists in the United States are younger than 50 years, the actual annual attrition rate

for all ophthalmologists is below 2.7%.[41] According to our model, assuming a 2% annual attrition rate of ophthalmologists in the Dominican Republic, the number of ophthalmologists per million will reach a maximum of 34.5 per million after 11 years and decrease thereafter. One recommendation from this scenario is the expansion of the ophthalmology resident positions within a decade to avoid a decline in the ratio of ophthalmologists to population.

The conclusions obtained from the models have several limitations. First, it is assumed that there is no interaction between the optometric and ophthalmologic workforce models. It is likely that as the number of university-educated optometrists increases, there will be pressure exerted by non-surgical ophthalmologists to decrease the growth of the university program. A future expansion of optometry scope to include the treatment and management of ocular disease is also likely to increase ophthalmologic opposition. This situation could be incorporated into the model by assuming a dampening factor on the number of optometric applicants. The value of the dampening factor would increase as the number of optometrists grows.

Second, the current models consider stable birth and mortality rates through time in the Dominican Republic. In a future paper, as reliable information about changing birth and death rates becomes available, the model may be refined through a table or graph function for the Vensim simulation.

Third, it is assumed there is no attrition of university-trained optometrists during the 60-year period. In the United States, where the profession is mature and well-established, approximately 2% of optometrists retire annually.[42] When assuming a cohort of young graduates in the Dominican Republic (less than 25 years old), one can expect low percentages of retirees during the first 40 years. On the other hand, when assuming a cohort of older students entering the program, one may expect a higher percentage of annual retirees. Future data on the student body composition may allow for better refinement of the optometric workforce model.

Fourth, the model is limited in scope and only addresses eyecare workforce needs based on international ophthalmologic standards and the United States' optometric standards. Further refinements of the model may consider workforce needs based on population-based data on the prevalence of refractive error, visual impairment and ocular pathologies in the Dominican Republic. The currently available information is limited in detail and quality but may improve in the near future to allow model refinements.

Lastly, as in all simulation models, the present model is based on assumptions that may change over time, such as the number of admitted optometry students and their retention rate, as well as the number of new ophthalmology residents. However, the model could be refined as the values of these variables are known and applied in the simulation.

Conclusion

This paper has shown an application of system dynamics to model the optometric and ophthalmologic workforce in the Dominican Republic. The model produces predictions of the changes in the supply of eyecare professionals under varying annual attrition rates. These predictions allow for useful recommendations to be made regarding optometric legislation to curb empiricism, future expansion of the scope of the profession, changes in the number of admitted optometry students, and changes in the number of ophthalmology residents. Optometric educators could apply system dynamics simulation in their public health courses in diverse areas. For example, it could be used to model demographic changes, the development of epidemics, the effects of air pollution, the provision of immunization services, or workforce needs as in the present case.[14-19]

Footnotes

[a] Mariano Belen, former President of the Dominican Optometric Association. Conversation with author, Santo Domingo, Dominican Republic. He has given permission to publish this information.

[b] The author has no financial arrangement with or interest in the Vensim software or Ventana Systems.

References

1. Marshall EC, Pagan A. Optometric manpower in the Commonwealth of Puerto Rico: estimates and projections, 1982-2025. J Am Optom Assoc. 1998;69(3):161-79.
2. Marshall EC. Assessment of the need for optometric education in Puerto Rico – Part II: vision care needs and manpower. Optometric Education. 1983 Fall;9(2):13-18.
3. Oficina Nacional de Estadística [Internet]. Dominicana en Cifras 2018. Santo Domingo (Dominican Republic); 2018. 553p. Available from: https://web.one.gob.do/publicaciones/2019/anuario-dominicana-en-cifras-2018/.
4. Furtado JM, Lansingh VC, et al. Causes of blindness and visual impairment in Latin America. Surv Ophthalmol. Mar-Apr 2012;57(2):149-77.

5. Santiago HC. Systemic Ocular and Refractive Conditions in a Clinical Population in the Dominican Haitian Border Town of Pedernales [Internet]. Poster session presented at: American Academy of Optometry Meeting; 2018 Oct 27-30; Chicago, IL. Available from: https://www.aaopt.org/detail/knowledge-base-article/systemic-ocular-and-refractive-conditions-in-a-clinical-population-in-the-dominicanhaitian-border-town-of-pedernales.
6. Limburg H, von-Bischhoffshausen FB, Gomez P, Silva JC, Foster A. Review of recent surveys on blindness and visual impairment in Latin America. Brit J Ophthalmol. 2008;92(3):315-9.
7. Sociedad Dominicana de Oftalmología [Internet]. Santo Domingo: Sociedad Dominicana de Oftalmología [cited 2019 Oct 10]. Available from: https://cmd.org.do/sociedades_especiali/sociedad-dominicana-de-oftalmologia/.
8. Instituto contra la Ceguera por Glaucoma [Internet]. Santo Domingo: INCOCEGLA; [cited 2019 Oct 20]. Available from: http://incocegla.org.do/v2/.
9. Ministerio de Educación Superior, Ciencias y Tecnología [Internet]. Normas para la aprobación, regulación y acreditación de las Escuelas de Medicina en la Republica Dominicana [Internet]. Santo Domingo (Dominican Republic), 2012 [cited 2020 Aug 20]. Available from: https://www.mescyt.gob.do/wp-content/uploads/2018/07/16.-NORMAS-PAR--LA-APROBACION-REGULACION-Y-ACREDITACION-DE-ESCUELAS-DE-MEDICINA-EN-RD.pdf.
10. Colegio Médico Dominicano [Internet]. Ley de Colegiación Médica y sus Reglamentaciones. Santo Domingo (Dominican Republic); 2005 [cited 2020 Aug 20]. Available from: https://cmd.org.do/wp-content/uploads/2019/09/Ley-de-Colegiac-on-Medica-y-sus-Reglamentaciones.pdf.
11. Asociación Dominicana de Optometría [Internet]. Santo Domingo (Dominican Republic); [cited 2020 Dec 5]. Available from: http://www.findglocal.com/DO/Santo-Domingo/298454650181992/Asociaci%C3%B3n-Dominicana-De-Optometr%C3%Ada.
12. Secretaria de Estado de Educación Superior, Ciencias y Tecnología. Ley 139-01 de Educación Superior, Ciencias y Tecnología. [Internet]. Santo Domingo (Dominican Republic); 2013 [cited 2020 Jun 23]. Available from: https://www.siteal.iiep.unesco.org/sites/default/files/sit_accion_files/do_3063_0.pdf.
13. Universidad Tecnológica de Santiago [Internet]. Santo Domingo: UTESA; c2020. [cited 2020 Oct 20]. Available from: https://www.utesa.edu/webutesa/home.htm.
14. Cave SR, Willis G, Woodward A. A Retrospective of System Dynamics based Workforce Modelling at the Centre for Workforce Intelligence [Internet]. Paper presented at the 34th International Conference of the System Dynamics Society; 2016 July 17-21; Delft, Netherlands. Available from: https://www.researchgate.net/publication/321225119_A_retrospective_of_System_Dynamics_based_workforce_modelling_at_the_Centre_for_Workforce_Intelligence.
15. Chung SH, Jung DC, Yoon SN, Lee D. A dynamic forecasting model for nursing manpower requirements in the medical service industry. Service Business. 2010;4(3):225-36.
16. Hirsch GB, Killingsworth WR. A new framework for projecting dental manpower requirements. Inquiry. 1975 Jun;12(2):126-42.
17. Garcia JM. System dynamics modeling with Vensim. Madrid (Spain): ATC-Innova; 2019. 333 p.
18. Homer JB, Hirsch GB. System dynamics modeling for public health: background and opportunities. Am J Public Health. 2006;96(3):452-8.
19. Johnson JA, Anderson DE, Rossow CC. Health Systems Thinking: A Primer. Burlington, MA: Jones & Bartlett Learning; 2020. 138 p.
20. Santiago HC. Visual mapping to enhance learning and critical thinking skills. Optometric Education. 2011 Summer;36(3):125-139.
21. Saraji MK, Sharifabadi AM. Application of system dynamics in forecasting: a systematic review. International Journal of Management, Accounting and Economics. 2017;4(12):1192-1205.
22. Marzouk M, Hosny I. Modeling housing supply and demand using system dynamics. Housing, Care and Support. 2016 June;19(2):64-80.
23. Suryani E, Chou S-Y, Chen C-H. Air passenger demand forecasting and passenger terminal capacity expansion: a system dynamics framework. Expert Systems with Applications. 2010;37(3):2324-39.
24. Tang X, Zhang B, Höök M, Feng L. Forecast of oil reserves and production in Daqing oilfield of China. Energy. 2010;35(7):3097-3102.
25. Lyneis JM. System dynamics for market forecasting and structural analysis. System Dynamics Review: J Sys Dyn Soc. 2000;16(1):3-25.
26. Kwon H, Lyu B, Tak K, Lee J, Cho JH, Moon I. Optimization of naphtha purchase price using a price prediction model. Comp Chem Eng. 2016;84:226-36.
27. Vensim [Internet]. Version PLE 7.3.5. Harvard, MA: Ventana Systems; 2017. [cited 2020 Oct 20]. Available from https://vensim.com/.
28. Vensim History [Internet]. Harvard, MA: Ventana Systems; c2015 [cited 2020 Aug 23]. Available from: https://vensim.com/vensim-history/.
29. Goldner DR, Borener SS. Evaluating NGATS Research Priorities at JPDO [Internet]. Paper presented at: Aviation Technology, Integration and Operations Conference; 2006 Sept 25-27, Wichita, KS. Available from:

https://www.ventanasystems.com/wp-content/uploads/2013/12/ventana_nextgen_portfolio.pdf.
30. Harris B. IT Goes Strategic [Internet]. Government Technology Magazine, 2004 Winter; c2005 [cited 2020 Aug 20]. Available from: https://www.ventanasystems.com/wp-content/uploads/2013/12/itgoesstrategic.pdf.
31. Shahgholian K, Hajihosseini H. A Dynamic Model of air pollution, health, and population growth using system dynamics: a study on Tehran-Iran (with computer simulation by the software Vensim). World Acad Sci Eng Technol. 2009;59:245-52.
32. Ventana Systems: Our Work [Internet]. Harvard, MA: Ventana Systems; c2016. [cited 2020 Aug 7]. Available from: https://www.ventanasystems.com/examples_general/.
33. Holden BA, Resnikoff S. The role of optometry in Vision 2020. Community Eye Health. 2002;15(43):33-6.
34. Hong H, Mújica OJ, Anaya J, Lansingh VC, López E, Silva JC. The challenge of universal eye health in Latin America: distributive inequality of ophthalmologists in 14 countries. BMJ Open. 2016;6(11):e012819.
35. LXIV Legislatura Cámara de Diputados Boletin 2925: Se reforma Ley General de Salud para regular a optometristas [Internet]. Mexico City: Cámara de Diputados; c2014 [cited 2020 Jan 19]. Available from: http://www5.diputados.gob.mx/index.php/esl/Comunicacion/Boletines/2014/Febrero/06/2925-Se-reforma-Ley-General-de-Salud-para-regular-a-optometristas.
36. Espacio Virtual de Asesoría de Función Pública (EVA). Ley 372 de 1997. [Internet]. Bogotá (Colombia); c1997 [cited 2020 Dec 7]. Available from: https://www.funcionpublica.gov.co/eva/gestornormativo/norma.php?i=66193.
37. Ministerio de Salud de Colombia. Programa Nacional de Atención Integral en Salud Visual 2016-22 [Internet]. Bogotá (Colombia); c2016 [cited 2020 Dec 7]. Available from: https://pdfslide.tips/reader/f/programa-nacional-de-atencion-integral-en-salud-visual-optometria-clinica.
38. Number of Ophthalmologists in Practice and Training Worldwide [Internet]. Geneva, Switzerland: International Council of Ophthalmologists; c2020 [cited 2020 Jan 17]. Available from: http://www.icoph.org/ophthalmologists-worldwide.html.
39. Dall T, Chakrabarti R, Iacobucci W, Hansari A, West T. 2017 Update: The Complexities of Physician Supply and Demand: Projections from 2015 to 2030 [Internet]. Washington, DC: Association of American Medical Colleges; c2017 [2020 Jan 17]. Available from: https://aamc-black.global.ssl.fastly.net/production/media/filer_public/a5/c3/a5c3d565-14ec-48fb--74b-99fafaeecb00/aamc_projections_update_2017.pdf.
40. Dall T, Reynolds R, Jones K, Chakrabarti R, Jones K, Iacobucci W. The Complexities of Physician Supply and Demand: Projections from 2018 to 2033 [Internet]. Washington, DC: Association of American Colleges; c2020. Available from: https://www.aamc.org/system/files/2020-06/stratcomm-aamc-physician-workforce-projections-june-2020.pdf.
41. Young A, Chaudhry HJ, Pei X, Arnhart K, Dugan M, Snyder GB. A census of actively licensed physicians in the United States, 2016. J Med Regulation. 2017;103(2):7-21.
42. An Action-Oriented Analysis of the State of the Optometric Profession: 2013 [Internet]. San Diego, CA: Jobson Medical Information. Available from: https://www.reviewob.com/wp-content/uploads/2016/11/soop_070120134.pdf.

Follow

Share

Hydroxychloroquine Retinal Toxicity: a Teaching Case Report

Stanley Tang, OD, FAAO, and Angelina Tran, OD, FAAO | Optometric Education: Volume 46 Number 3 (Summer 2021)

PDF of Article

Background

Hydroxychloroquine (Plaquenil, Novartis, East Hanover, N.J.) is a drug initially developed in the mid-1950s for management of malaria and is a derivative of chloroquine. The hydroxylation of chloroquine has resulted in a decreased incidence of side effects while maintaining efficacy.[1] Currently, hydroxychloroquine is used for management of various rheumatologic conditions, including rheumatoid arthritis, systemic lupus erythematosus, and Sjogren's syndrome. In the future, hydroxychloroquine may also be used in the management of other medical conditions. Early studies show promising results in the control of hemoglobin A1c (HbA1c) levels for individuals with diabetes.[2,3] There is also anecdotal evidence suggesting hydroxychloroquine (used concurrently with azithromycin) may be an effective treatment for coronavirus disease 2019 (COVID-19) infections caused by the coronavirus initially discovered in late 2019.[4]

Hydroxychloroquine has been observed to cause significant ocular side effects, including retinal toxicity and, less commonly, anterior segment changes.[5] Symptoms include reduced vision, paracentral scotoma, photopsia and glare. The American Academy of Ophthalmology (AAO) released updated guidelines in 2016 for screening protocols for individuals who have been prescribed hydroxychloroquine.[12] Early detection of ocular toxicity is of utmost importance as retinal toxicity changes are irreversible and may continue to progress after discontinuation of the medication.

The following case report describes a 66-year-old White male who was diagnosed with retinal toxicity from hydroxychloroquine based on Humphrey visual field (HVF) 10-2 testing and macular optical coherence tomography (OCT) imaging. He subsequently discontinued hydroxychloroquine after consultation with rheumatology and was followed for progression of visual field damage.

Case Report

A 66-year-old Caucasian male presented as a new patient for his annual comprehensive eye exam. He had a history of hydroxychloroquine use for management of discoid lupus. His dosage was 200 mg orally BID, with a total daily dose of 400 mg. He had been followed previously by another eyecare provider but was lost to follow-up for four years. His total duration of dosing of hydroxychloroquine was approximately seven years.

The patient's medical history included discoid lupus, irritable bowel syndrome, hypertension and chronic obstructive pulmonary disease. There was a noted lack of renal impairment in the patient's medical history. His daily medications included hydroxychloroquine, amlodipine, hydrochlorothiazide and albuterol inhaler. He had no prior history of ocular trauma or surgery. His previous ocular health record from four years prior included cataracts and a choroidal nevus in the left eye, with no mention of maculopathy in either eye.

Entering uncorrected visual acuities were 20/30 OD and 20/30-2 OS. His best-corrected visual acuities after manifest refraction were 20/20 OD and 20/20 OS, with low astigmatic correction in both eyes. Pupil reactivity, confrontation visual fields and ocular motility were normal in both eyes. Intraocular pressure measured 18 mmHg OD and 17 mmHg OS with Goldmann applanation tonometry.

Slit lamp examination of the anterior segment was unremarkable in both eyes, including a noted absence of corneal deposits in both eyes. Dilated posterior segment examination revealed mild nuclear sclerotic changes of the lens in both eyes. The vitreous was clear in both eyes. The patient's optic nerve cup-to-disc ratio was 0.30H/0.35V OD and 0.35H/0.35V OS. His maculae were flat and evenly pigmented without obvious presence of bull's eye maculopathy or macular pigmentary disruption. The posterior pole in the left eye exhibited a flat choroidal nevus 1 disc-diameter in size along the superior arcade with overlying drusen and no observable lipofuscin. The peripheral retina was unremarkable in both eyes.

HVF 10-2 testing, performed prior to his dilated exam, revealed an early-to-moderate paracentral ring scotoma with sparing of the central two degrees in the right eye. The left eye visual field test revealed an early paracentral ring scotoma, also with sparing of the central two degrees **(Figure 1)**. This was a significant change from his baseline visual field testing from four

years ago, which was reliable and without evidence of a paracentral scotoma **(Figure 2)**.

Baseline spectral-domain OCT (SDOCT, Heidelberg Spectralis) of the macula revealed subtle thinning of the outer nuclear layer of the right eye and normal macular appearance in the left eye. Ellipsoid zone disruption was present in both eyes **(Figure 3)**. The image captured was a 25-line horizontal raster scan.

The patient was educated on his diagnosis and advised to return in three months for repeat HVF 10-2 testing to monitor for further progression of the visual field loss. The patient's rheumatologist was notified of the findings of early retinal toxicity and he discontinued the use of hydroxychloroquine immediately.



Figure 1. *Humphrey visual field 10-2 results for left eye (A) and right eye (B). Note the paracentral ring scotoma in the right more than left eye, with sparing of the central two degrees.*
Click to enlarge



Figure 2. *Baseline Humphrey visual field 10-2 results for the left eye (A) and right eye (B) from historical record review.*
Click to enlarge

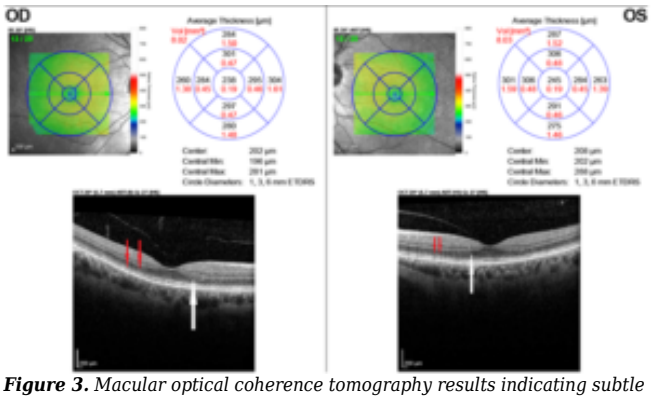

Figure 3. *Macular optical coherence tomography results indicating subtle inner segment/outer segment (IS/OS) junction disruption (red arrows) and thinning of the outer nuclear layer just nasal to the fovea in the right eye (white arrow). There is mild IS/OS junction disruption (red arrows) and outer nuclear thinning in the left eye (white arrow).* *Click to enlarge*



Figure 4.*Progression of the patient's visual field 10-2 results in both eyes. Note the progression of the visual field damage despite discontinuation of hydroxychloroquine. However, the field appears stable starting at seven months after discontinuation.*
Click to enlarge

The patient had repeat HVF 10-2 testing performed two months, six months and approximately 18 months later **(Figure 4)**. There was continual progression of visual field loss after discontinuation of hydroxychloroquine for approximately six months. The patient has been followed on an annual basis, and his visual field appeared stable at his most recent examination, 18 months post-discontinuation.

Educator's Guidelines

Key concepts

1. Overview of current AAO screening guidelines
2. Understanding high-risk characteristics and risk factors for hydroxychloroquine toxicity
3. Detection and observation of early ancillary testing changes associated with hydroxychloroquine toxicity

Learning objectives

At the conclusion of this case discussion, participants should be able to:

1. Review a patient's ocular and medical history to determine risk factors for retinal toxicity
2. Understand risk factors and tailoring of hydroxychloroquine screening guidelines based on individual patient medical history
3. Observe early changes in HVF, OCT, fundus autofluorescence (FAF) and multifocal electroretinography (mfERG) test results for early detection
4. Co-manage individuals taking hydroxychloroquine with rheumatology
5. Be familiar with future directions of hydroxychloroquine use outside of rheumatologic disorders

Discussion questions

1. Knowledge and concepts required for critical review of the case

a. What are current AAO screening guidelines for when to initiate annual screening?
b. Which risk factors have the greatest impact on development of retinal toxicity?
c. How does early retinal toxicity manifest in HVF, OCT, FAF and mfERG?

2. Differential diagnoses

a. What are likely differential diagnoses to be considered for this case?
b. When is ancillary testing recommended?
c. What additional testing can be done to differentiate hydroxychloroquine toxicity from other differential diagnoses considered above?

3. Disease management

a. What management would you recommend to this patient or similar patients?
b. How often would you follow this patient after diagnosis of toxicity?
c. Are there any at-home tests or other methods for these patients to monitor for changes?

4. Patient education

a. What would you tell the patient about the prognosis of this condition?
b. How would you discuss systemic risk factors that may relate to retinal toxicity?
c. How would you educate this patient to understand continued follow-up with rheumatology is necessary?

5. Critical thinking

a. Would you have done anything differently in management of this case? Please elaborate.
b. Would your screening of this patient vary if he were a different race? If so, what would you change?

Discussion

Teaching instructions

This case report targets third- and fourth-year optometry students and optometry residents. Prior knowledge of visual field testing and observation of retinal layers on OCT are expected. Readers should study the entire background and case report, including OCT scans and visual field test results, and answer all discussion questions in the Education Guidelines section. The questions will guide assessment in the success of learning objectives. This case will likely be best presented as a PowerPoint presentation due to its graphical nature and need for interpretation of ancillary testing. In addition, a combination of PowerPoint and verbal case discussion will best convey background concepts within this teaching case report.

Background

Hydroxychloroquine is a chloroquine derivative originally developed for management of malaria. Although it has limited use as an anti-malarial due to development of chloroquine-resistant strains of malaria, historical experimentation during the early to mid-1950s led to the discovery of its anti-inflammatory properties.[1] It has since been used for management of rheumatoid arthritis, systemic lupus erythematosus and other rheumatic conditions.[1]

Hydroxychloroquine may also be useful in the management of diabetes as an alternative to traditional diabetic medications.[2,3] Hsia et al. reviewed diabetic management in patients taking the maximum dose of metformin and a sulfonylurea. 400-mg dosing of hydroxychloroquine was compared with 45 mg pioglitazone as third-line drugs for diabetic management. After a two-month clinical trial, the authors noted a decrease in HbA1c levels of 1.2% for patients in the hydroxychloroquine group, and a 2.8% decrease in HbA1c levels for patients in the pioglitazone group. The authors noted cost efficiency should be considered, as hydroxychloroquine is available for substantially lower cost than pioglitazone.[3]

The global COVID-19 pandemic shined a new light on hydroxychloroquine (combined with azithromycin) as a potential treatment for the symptoms caused by COVID-19.[7] Although studies have produced mixed results and are limited in size and scope, some evidence has been found to suggest hydroxychloroquine, when combined with azithromycin, may decrease viral load of the novel coronavirus.[7] Gautret et al. observed in a small study that 600 mg of hydroxychloroquine daily, combined with azithromycin, led to a significant reduction in viral load after six days of treatment.[8] All six patients treated with combined azithromycin and hydroxychloroquine showed a negative nasopharyngeal polymerase chain reaction test at day six. This is in contrast with using hydroxychloroquine alone, which led to eight of 14 patients testing negative after six days.[8] As COVID-19 is an ever-changing public health crisis, further studies indicated limited justification for the use of hydroxychloroquine for management of the virus. This ongoing debate centered around hydroxychloroquine led to shortages in supply of the drug, causing concern for both rheumatologists and patients.[9] A more recent study by Geleris and Sun followed 1,376 patients, with 58.9% receiving hydroxychloroquine. Patients receiving hydroxychloroquine were dosed at 600 mg BID on day one, then 400 mg daily for an additional four days. Respiratory failure developed in 25.1% of patients studied, which the authors defined as the primary endpoint for their study. The authors stated there was no significant association between hydroxychloroquine use and the primary endpoint.[10] The risk of respiratory failure or death was not significantly higher or lower among those who were administered hydroxychloroquine according to the regimen above, contradicting the prior smaller-scale European study.[10]

Individuals who have been prescribed hydroxychloroquine are at risk to develop both anterior and posterior segment ocular side effects.[5] Although rare, corneal epithelial deposition is possible and generally occurs within the inferior cornea.[5,6] Grierson noted an overall incidence of keratopathy of 0.8% (six cases of 758 patients studied).[6] However, in four of these cases, the dosing was greater than 6.5mg/kg daily.[6] These corneal deposits are typically not visually significant and are reversible upon discontinuation of therapy.[5,6] Cataract and accommodative dysfunction have been found to occur in patients taking chloroquine; however, these side effects have not been observed in individuals prescribed hydroxychloroquine.[19]

Retinal toxicity can have devastating visual consequences if not detected early. Current guidelines released by the AAO in 2016 include a few changes from the previous revision in 2011.[12] The AAO accumulated significant data from 2,361 patients who were prescribed hydroxychloroquine for more than five years. The authors noted an overall 7.5% prevalence of hydroxychloroquine retinopathy. Incremental risk for an individual using ≤ 5.0 mg/kg daily dosing is less than 1% during the first 10 years of use. This increases to 4% after 20 years. However, it can reach an approximate risk of 20% after 20 years of use with higher dosing.[16] Current AAO guidelines state that annual screenings are recommended after five years of use. Marmor et al. noted that patients prescribed hydroxychloroquine at ≤ 5.0 mg/kg daily for less than five years have less than 1% risk of developing retinal toxicity.[12]

The daily dose recommendation of hydroxychloroquine has changed from < 400 mg daily in 2011 to < 5mg/kg daily.[12] The historical 400-mg daily dosing calculation was calculated from a patient's ideal body weight (IBW) and recommendations of hydroxychloroquine dosing to be 6.5 mg/kg IBW. However, Walvick et al. noted that dosing through IBW led to 56% of females and 46% of males receiving higher than the recommended dose of hydroxychloroquine.[13] Marmor et al. also determined that there is a stratification of risk based on actual body weight (ABW) dosing of hydroxychloroquine: 5mg/kg daily dosing ABW led to two to three times greater risk of developing hydroxychloroquine retinopathy compared with 4-mg/kg daily dosing ABW.[12]

The cumulative dosing guideline of > 1,000 g total dose established in 2011 has been removed. A total cumulative dose of 1,000 g can be established through 400-mg daily dosing for 6.85 years, or 200-mg daily dosing for 13.7 years.[16] Because the AAO already recommends screening after five years, this guideline is no longer thought to be relevant.

Systemic risk factors for hydroxychloroquine retinal toxicity include renal impairment and current tamoxifen use. Renal impairment has been associated with higher serum hydroxychloroquine concentration, as hydroxychloroquine is excreted through the renal system.[14] Melles and Marmor stated that a 50% reduction in glomerular filtration rate is associated with doubling of hydroxychloroquine retinopathy risk.[15] Also, it should be noted that although hydroxychloroquine is partially metabolized within the liver, the authors found no increase in risk of hydroxychloroquine retinopathy for individuals with documented liver disease.[12,24] Tamoxifen, commonly used in the management of breast cancer, is now noted as a significant risk factor for development of retinopathy when taken concomitantly with hydroxychloroquine; there is an up-to-five-fold increased risk of development of retinopathy when the two are taken in combination.[12] Although the underlying physiology of this increased risk is not known, it is speculated that the two drugs have an adverse metabolic synergistic effect.[12] This is another

major change from the AAO 2011 guidelines to its 2016 revision.

Upon encountering a patient with current hydroxychloroquine usage, it is imperative to ask specific questions about his/her medical and ocular history to determine the risk of retinal toxicity. As outlined above, one should confirm the patient's dosing and duration of use and inquire about an estimated weight. This will allow for calculation of the ABW dosing, which can be used to determine whether a patient is taking a high-risk or low-risk dose of hydroxychloroquine. In addition, a careful review of medications and patient medical history (including presence or absence of renal disease) should be performed to determine risk of toxicity.

Currently, baseline examination is recommended within the first year of initiating hydroxychloroquine and annually after five years of use. In addition, the drug manufacturers also recommend baseline examination prior to starting therapy to rule out pre-existing maculopathies.[16] The current AAO guidelines also state that pre-existing maculopathy is a risk factor for development of hydroxychloroquine retinopathy; however, Yusuf et al. found no data to suggest pre-existing maculopathy leads to increased susceptibility of hydroxychloroquine retinopathy.[16] Patients with minimal baseline macular abnormality, including mild macular drusen, should not be excluded from therapy.[16] However, pre-existing macular conditions may interfere with interpretation of ancillary testing and detection of early toxic retinopathy. Major macular pathology is a contraindication to hydroxychloroquine use.[16]

Diagnosis and clinical findings

Diagnosis of early-stage hydroxychloroquine retinopathy largely relies on ancillary testing, including HVF 10-2 and 24-2, macular OCT, FAF and mfERG. AAO guidelines state that the recommended tests are HVF 10-2 and SDOCT; FAF and mfERG are noted as discretionary.[16] Of note, the 2016 guidelines recommend HVF 24-2 and widefield SDOCT testing for patients of Asian descent as these patients tend to exhibit extramacular toxicity.[14]

Toxicity detected through HVF 10-2 testing is typically observed as a paracentral ring scotoma, normally from two to six degrees of fixation, with sparing of the central two degrees.[27] Particular attention should be given in the superior nasal region as the inferior temporal retina tends to be affected early.[20] A low threshold for suspicion is important in early diagnosis; defects may initially be discounted as non-specific scatter due to the subjective nature of visual field testing. In addition, patients of Asian descent may have visual field loss beyond eight degrees from the fovea.[18] It should also be noted that central defects found on HVF 24-2 testing warrant further testing with the 10-2 test strategy. A single-point depression centrally in the HVF 24-2 testing strategy may be a significant central loss on HVF 10-2 testing.[27] In this clinical case, Figures 2A and 2B show an early paracentral defect that notably is sparing the central two degrees from fixation. The defect also appears to be limited to no further than six degrees from fixation. The characteristic pattern of visual field defect in the case outlined above was concerning for possible hydroxychloroquine toxicity.

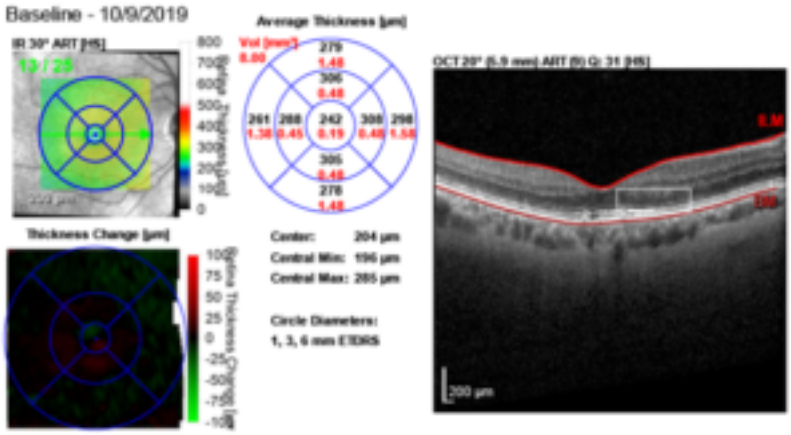

Figure 5. *Example of outer nuclear layer thinning noted within the white box. Compare outer nuclear layer nasally vs. laterally in the same image.*
Click to enlarge

OCT is another essential tool for diagnosing maculopathy. It provides objective, detailed measurements of retinal structure. SDOCT testing is preferred over time-domain OCT, as the latter does not provide adequate resolution.[12] Loss within macular OCT testing may be subtle on interpretation and requires careful attention. Disruption of the ellipsoid zone (also known as the inner segment/outer segment junction or the photoreceptor integrity line) may be observed in early stages of disease.[26] Paracentral outer nuclear layer loss presents in moderate-stage disease; disruption and loss of the external limiting membrane may be observed as well.[23] **Figure 5** highlights an example of outer nuclear layer thinning on SDOCT (Heidelberg Spectralis) macular imaging. For the clinical case outlined here, Figures 3A and 3B show a disruption of the outer nuclear layer as well as the ellipsoid zone in both eyes on SDOCT (Heidelberg Spectralis) testing. The appearance of the SDOCT scan, in conjunction with the visual field findings noted above, were of concern for hydroxychloroquine toxicity.

OCT may also provide additional benefit due to widefield imaging capabilities that are now emerging in clinical care settings. Widefield imaging is beneficial for Asian patients who may develop extramacular toxicity.[18,20,22] Choudhry et al. defined widefield imaging as up to a 50-degree field of view, with ultra-widefield imaging described as a 200-degree field of view in a single image.[17] A study by Lee et al. reported that in eight out of nine patients with diagnosed retinal toxicity in a Korean population, the appearance was pericentral as opposed to the classic parafoveal.[18] Particular attention is needed with observation of the inferior temporal retina as this area tends to be where early toxicity is first observed.[16]

FAF is another useful tool in evaluation of hydroxychloroquine retinopathy. Early toxicity may present itself as subtle paracentral hyperautofluorescence (or along arcades for Asians), with later stages appearing as hypoautofluorescence centrally surrounded by areas of hyperautofluorescence.[19] Ahn et al. demonstrated observation of extramacular hydroxychloroquine retinopathy through widefield FAF in 70.7% of eyes examined in a Korean population.[20] Imaging systems by Optos are able to achieve a field of view up to 200 degrees (Optos, Optomap Ultra-Widefield). Heidelberg also has developed widefield imaging techniques, which can provide a 105-degree field of view using a lens modification to the Heidelberg Retinal Angiograph.[21]

mfERG is considered the gold standard for hydroxychloroquine retinopathy screening as it may possibly detect toxicity earlier than other testing methods.[22] The test produces a topographic map of ERG responses across the posterior pole. Reduced paracentral retinal responses are indicative of hydroxychloroquine toxicity.

Eyecare practitioners should recognize the importance of multiple modalities in confirming a diagnosis of hydroxychloroquine retinopathy. Greenstein et al. noted that functional changes in hydroxychloroquine retinopathy patients may be observed even before structural changes exist. Although OCT is a significant diagnostic tool, approximately half of patients with diagnosed toxicity in one study had normal SDOCT findings in the presence of abnormal HVF 10-2 and mfERG findings.[23] In another study, Marmor and Melles observed 10% of patients examined with hydroxychloroquine toxicity showed a significant paracentral scotoma in absence of SDOCT abnormalities.[19] Not only does this suggest that functional changes may present before structural changes, this also highlights the importance of using multiple ancillary tests to screen for hydroxychloroquine toxicity.

Patients may inquire about any possible at-home tests that may help them determine new presence of toxicity. Historically, the Amsler grid was thought to be a viable screening tool in hydroxychloroquine toxicity. However, the current AAO screening guidelines (2016 revision) list Amsler grid as not recommended for screening. Currently, there are no tests that can be done at home to screen for retinal toxicity.

Differential diagnosis

The differential diagnoses for hydroxychloroquine retinopathy include:

1. Age-related macular degeneration (ARMD). Risk factors for ARMD include increased age, family history and personal history of smoking. Changes observed on macular OCT include central macular drusen and possibly intraretinal and/or subretinal fluid in cases of exudative macular degeneration. Symptoms include reduced vision, metamorphopsia, and central scotoma. The characteristic presence of drusen may be used to differentiate the two conditions.
2. Cone or cone/rod dystrophy. Cone or cone/rod dystrophy is a result of congenital mutations in more than 30 genes, inherited through autosomal recessive patterns. These are typically diagnosed at a young age through genetic testing. Patients present with reduced vision, reduced color vision, central scotoma and peripheral vision loss. Peripheral vision loss is not typical of hydroxychloroquine retinopathy.
3. Stargardt’s disease. Stargardt’s is a form of macular degeneration typically affecting children and young adults. Like cone/rod dystrophies, Stargardt’s is an inherited condition leading to reduced visual acuity, color vision and development of central scotoma. Diagnosis can be made through observation, ERG testing or genetic testing. One can differentiate Stargardt’s disease from hydroxychloroquine retinopathy due to age because Stargardt’s disease tends to affect a younger age cohort.

Management and prognosis

Currently, no treatment exists for hydroxychloroquine retinopathy, highlighting the significance of early diagnosis and communication with rheumatology. Retinal toxicity may be limited with early diagnosis, which is important as progression of visual field loss has been noted for years after discontinuation of therapy. Careful follow-up is necessary to continually monitor for changes in visual acuity and visual field. According to AAO screening guidelines, HVF 10-2 (or 24-2 in Asian patients) and OCT macular testing are used in diagnosis of hydroxychloroquine retinopathy.[12] For individuals with suspected toxicity who are physically unable to perform HVF testing, referral to tertiary care centers or educational institutions with access to mfERG or FAF may be indicated. **Table 1** highlights the newest guidelines for hydroxychloroquine screening.

Upon diagnosis of retinal toxicity, eyecare providers should be in contact with rheumatology regarding the evidence of toxicity and recommendations to discontinue therapy. A balance of vigilance and understanding of expected functional and structural changes is needed to avoid premature discontinuation of therapy.

As noted by Marmor et al., the progression of structural changes on SDOCT depends on the stage of toxicity when diagnosed (and thus, how quickly hydroxychloroquine is discontinued). The authors stated that cases of early hydroxychloroquine toxicity showed little to no foveal structure changes measured on the Cirrus ETDRS cube. In contrast, individuals with moderate toxicity at time of diagnosis had progressive foveal thinning for at least three years. Severe toxicity at time of discontinuation had the most prominent progression of foveal thinning during this time frame. The authors defined early toxicity as "patchy damage within the parafoveal zone shown by field or objective testing." Moderate toxicity was defined as "50% to 100% parafoveal ring of damage and marked thinning of the parafoveal retina on SDOCT without retinal pigment epithelium (RPE) damage." Severe toxicity was defined as "bull's-eye damage with RPE involvement on SDOCT (visible retinopathy)."[26]

TABLE 1
Summary of AAO Guidelines for Hydroxychloroquine Retinal Toxicity Screening

Drug-Related Risk Factors	• Greater than five years treatment • > 5.0 mg/kg ABW daily (HCQ) • > 2.3 mg/kg ABW daily (CQ)
Cumulative Dose	• None
Systemic Disease	• Renal impairment
Ocular Disease	• Pre-existing maculopathy
Drugs	• Tamoxifen
Age	• None
Screening Frequency	• Baseline fundus examination within one year of beginning therapy • Annual screening after five years of use • Obtain visual field and SDOCT if abnormality present at baseline
Screening Protocols	• HVF 10-2 and SDOCT (non-Asian) • HVF 24-2/30-2 and WF SDOCT (Asian)
Extra Screening Methods (May not be easily accessible)	• mfERG • Fundus autofluorescence

AAO = American Academy of Ophthalmology; ABW = actual body weight; HCQ = hydroxychloroquine; CQ = chloroquine; SDOCT = spectral-domain optical coherence tomography; HVF = Humphrey visual field; WF SDOCT = widefield spectral-domain optical coherence tomography; mfERG = multifocal electroretinogram

Table 1. *Click to enlarge*

The authors also noted the ellipsoid zone, which needs to maintain structural integrity for preservation of visual acuity, is left intact after three years in cases of early and moderate toxicity. This further highlights the importance of early detection in preservation of visual acuity, as severe toxicity showed progressive loss of the foveal ellipsoid zone.[23]

Patients should be aware of their hydroxychloroquine screening results and prognosis should any presence of toxicity occur. It is imperative to highlight the importance of retinal toxicity screening and advise them that early discontinuation of therapy is necessary to limit the continual progression of visual field defects. Patients should also be educated about the risk of continual progression of visual field changes even years after discontinuation. Several risk factors, such as renal impairment, tamoxifen use and > 5mg/kg daily dosing are associated with an increased risk of retinal toxicity development. Therefore, changes to a patient's medical history should be reported to the eyecare practitioner so modifications can be considered to the screening regimen. Follow-up with rheumatology is also important because rheumatologic symptoms may worsen after discontinuation of hydroxychloroquine.

Conclusion

The case presented demonstrates important concepts related to careful evaluation and review of patient medical history, detection and communication in relation to hydroxychloroquine retinal toxicity. Optometrists play a crucial role in screening and detection related to hydroxychloroquine, which remains one of the most commonly prescribed drugs for rheumatologic conditions today. Individual medical history must be reviewed in great detail, as factors such as medication use and renal disease may greatly increase the risk of toxicity. Optometrists must be aware of both a patient's hydroxychloroquine dosing and ABW to determine his or her risk of retinal toxicity through calculation of mg/kg daily dosing. The authors of this teaching case report choose to screen prior to five years of use for individuals who have documented renal impairment, tamoxifen use or sustained dosing of > 5mg/kg daily. In addition, one may consider screening sooner than five years for patient peace of mind. Both objective and subjective ancillary testing is recommended, and thorough evaluation of results is paramount in early detection because progressive visual field loss can occur for years even after discontinuation of the medication. Early-stage toxicity may cause no visual symptoms, but late-stage toxicity may have devastating visual consequences.

References

1. Bergman M. The Nine Lives of Hydroxychloroquine [Internet]. Dallas: RheumNow; c2015 [cited 2020 Sep 28]. Available from: http://rheumnow.com/blog/nine-lives-hydroxychloroquine.
2. Chen YM, Lin CH, Lan TH, et al. Hydroxychloroquine reduces risk of incident diabetes mellitus in lupus patients in a dose-dependent manner: a population-based cohort study. Rheumatology (Oxford). 2015 Jul;54(7):1244-9.
3. Hsia S, Duran P, Lee M, Davidson MB. Randomized controlled trial comparing hydroxychloroquine with pioglitazone as third-line agents in type 2 diabetic patients failing metformin plus a sulfonylurea: a pilot study. J Diabetes. 2020 Jan;12(1):91-4.
4. Scuccimarri R, Sutton E, Fitzcharles M. Hydroxychloroquine: a potential ethical dilemma for rheumatologists during the COVID-19 pandemic. J Rheum. 2020 Jun 1;47(6):783-6.
5. Yam J, Kwok A. Ocular toxicity of hydroxychloroquine. Hong Kong Med J. 2006 Aug;12(4):294-304.
6. Grierson D. Hydroxychloroquine and visual screening in a rheumatology outpatient clinic. Ann Rheum Dis. 1997 Jan;56(3):188-90.
7. Agrawal S, Goel AD, Gupta N. Emerging prophylaxis strategies against COVID-19. Monaldi Arch Chest Dis. 2020 Mar 30;90(1).
8. Gautret P, Lagier J, Parola P, et al. Hydroxychloroquine and azithromycin as a treatment of COVID-19: results of an open-label non-randomized clinical trial. Int J Antimicrob Agents. 2020 Jul;56(1):105949.
9. Yazdany J, Kim A. Use of hydroxychloroquine and chloroquine during the COVID-19 pandemic: what every clinician should know. Ann Intern Med. 2020 Mar;172(11):754-5.
10. Geleris J, Sun Y, Platt J, et al. Observational study of hydroxychloroquine in hospitalized patients with Covid-19. New Eng J Med. 2020 Jun 18;382(25):2411-2418.
11. Rynes RI. Ophthalmologic safety of long-term hydroxychloroquine sulfate treatment. Am J Med 1983 Jul;75(1A):35-9.
12. Marmor MF, Kellner U, Lai TYY, Melles R,B Mieler WF. Recommendations on screening for chloroquine and hydroxychloroquine retinopathy (2016 revision). Ophthalmology. 2016 Jun;123(6):1386-94.
13. Walvick MD, Walvick MP, Tongson E, Ngo CH. Hydroxychloroquine: lean body weight dosing. Ophthalmology. 2011 Oct;118(10):2100.
14. Paperis K, Al-Charakh M, Nzuonkwelle S, McPherson M, Al-Marzooq A, Bhattarai B. Characteristics and outcomes among patients with autoimmune rheumatic diseases requiring a higher level of care. J Clin Rheum. 2020 Feb 12. Advance online publication: https://doi.org/10.1097/rhu.0000000000001321.
15. Melles RB, Marmor MF. The risk of toxic retinopathy in patients on long-term hydroxychloroquine therapy. JAMA Ophthalmol. 2014 Dec;132(12):1453-60.
16. Yusuf IH, Sharma S, Luqmani R, Downes SM. Hydroxychloroquine retinopathy. Eye. 2017 Jun;31(6):828-45.
17. Choudhry N, Golding J, Manry MW, Rao RC. Ultra-widefield steering-based spectral-domain optical coherence tomography imaging of the retinal periphery. Ophthalmology. 2016 Jun;123(6):1368-74.
18. Lee DH, Melles RB, Joe SG, et al. Pericentral hydroxychloroquine retinopathy in Korean patients. Ophthalmology. 2015 Jun;122(6):1252-6.
19. Marmor MF. Comparison of screening procedures in hydroxychloroquine toxicity. Arch Ophthalmol. 2012 Apr;130(4):461-9.
20. Ahn SJ, Joung J, Lee BR. Evaluation of hydroxychloroquine retinopathy using ultra-widefield fundus autofluorescence: peripheral findings in the retinopathy. Am J Ophthalmol. 2020 Jan;209:35-44.
21. Yung M, Klufas MA, Sarraf D. Clinical applications of fundus autofluorescence in retinal disease. Int J Ret Vit. 2016 Apr 8;2:12.
22. Tsang AC, Pirshahid SA, Virgili G, Gottleib CC, Hamilton J, Coupland SG. Hydroxychloroquine and chloroquine retinopathy: a systematic review evaluating the multifocal electroretinogram as a screening test. Ophthalmology. 2015 Jun;122(6):1239-51.
23. Greenstein VC, Amaro-Quireza L, Abraham ES, Ramachandran R, Tsang SH, Hood DC. A comparison of structural and functional changes in patients screened for hydroxychloroquine retinopathy. Doc Ophthalmol. 2014 Dec 12;130(1):13-23.
24. Marmor MF, Melles R.B Disparity between visual fields and optical coherence tomography in hydroxychloroquine retinopathy. Ophthalmology. 2014 Jun;121(6):1257-62.
25. Korah S., Kuriakose T. Optical coherence tomography in a patient with chloroquine-induced maculopathy. Indian J Ophthalmol. Nov-Dec 2008;56(6):511-3.
26. Marmor MF, Hu J. Effect of disease stage on progression of hydroxychloroquine retinopathy. JAMA Ophthalmol. 2014;132(9):1105-12.
27. Anderson C, Blaha GR, Marx JL. Humphrey visual field findings in hydroxychloroquine toxicity. Eye. 2011 Dec;25(12):1535-45.

Follow

Share

Utilization Survey of the First Two Cohorts of Optometry Graduates from the University of Medicine Pham Ngoc Thach in Ho Chi Minh City, Vietnam

Robert E. Molter, Jr., OD, FAAO, Jeffrey L. Weaver, OD, MS, FAAO, and W. Howard McAlister, OD, MA, MPH, FAAO |
Optometric Education: Volume 46 Number 3 (Summer 2021)

PDF of Article

Background

The purpose of this study is to explore what the optometry graduates of the University of Medicine Pham Ngoc Thach (UPNT) have experienced working within the Vietnamese health system. Secondary purposes are to educate the public on the ideal use of the optometrist in the Vietnamese health system and to discuss current barriers to autonomous practice within the public hospital system.

Until recently, eye care in Vietnam consisted only of a limited number of ophthalmologists, working primarily in a problem-focused way, and of refracting opticians at public hospitals and commercial optical shops. The system of ocular care follows the traditional system previously seen in China.[1,2] The opticians perform refractions primarily using trial lens sets; phoropter use is rare. The current quality of refraction varies widely and there is no requirement for formal refractive training. Some of the lower-quality refractions may consist of only a spherical equivalent refraction or a prescription from an autorefractor reading. There has been little preventive eye health and vision care. Furthermore, the more advanced eyecare resources are concentrated in the larger cities, primarily Ho Chi Minh City (HCMC) (south), Hanoi (north), and DaNang (central). As a result of this situation, many conditions such as glaucoma, cataract and retinal breaks progress undetected and untreated, leading to blindness. Early recognition of these conditions can lead to more effective treatment and improved visual outcomes. The lack of ocular surveillance is especially pronounced in the countryside where people need to travel relatively large distances to seek eye care. Optometry is being developed to bring comprehensive eye care and ocular health monitoring to Vietnam to reduce preventable blindness.

Optometry was first introduced to Vietnam as a profession with the graduation of 12 Vietnamese optometrists from the UPNT Optometry program in 2018. The first four classes admitted consisted of 49 females and 27 males. The optometry program awards a four-year bachelor's-level degree following high school. Entrance to both optometry and medical schools is competitive and there is no four-year general education before beginning a course of medical or optometric study. In contrast, ophthalmologists in Vietnam must complete a three-year residency following a four- to five-year course of study in general medicine. Medical students enter their program directly from high school as the optometry students do, and from the same applicant pool. This is similar to many education systems around the world, but unlike American medical/optometric education where an undergraduate degree is generally obtained prior to entry into professional school. There are no separate standardized entrance exams such as the Optometry Admission Test or Medical College Admission Test.

Tuition for the optometry program was subsidized partially by the Human Development Committee of Ho Chi Minh City for the first three years of the program. That support has now ended (recent graduate, oral communication, February 2020). The current tuition paid annually by the students is approximately $500 USD, which covers both semesters.[3] The tuition at the sister program in Hanoi is 10% higher at $550 USD.[4]

The instruction in the UPNT Optometry department mirrors a traditional Western-style optometry school curriculum but with perhaps a greater portion of the first year dedicated to basic science classes such as physics and anatomy. Some political and military training is required, which is standard for all students in Vietnam. The second and third years are intense with didactic and lab instruction in the core optometry subjects, followed by a fourth year primarily of practical clinical experience. The clinical experiences include working within the various departments at the main public eye hospital in HCMC. Unfortunately, the students often only observe and do not participate in the care delivered. The core clinical experience is in the Academic Vision Center (AVC), which was started as part of the general health clinic within UPNT and exists to serve the needs of the medical students and staff of UPNT. Although the facility is open to the public, its current clinic patient base is primarily young, healthy students. The curriculum used for the didactic instruction has been developed by the Brien Holden Vision Institute (BHVI) with the input of recognized experts in optometry from around the world. This curriculum is freely available to all at the BHVI website.[5]

TABLE 1
World Council of Optometry
Global Competency-Based Model of Scope of Practice in Optometry

Category 1	Category 2	Category 3	Category 4
Optical Technology Services (OT)	**Visual Function Services (VF)**	**Ocular Diagnostic Services (ODx)**	**Ocular Therapeutic Services (OTx)**
Management and dispensing of ophthalmic lenses, ophthalmic frames and other ophthalmic devices that correct defects of the visual system	Optical Technology Services, plus investigation, examination, measurement, diagnosis and correction/management of defects of the visual system	Visual Function Services, plus investigation, examination and evaluation of the eye and adnexa, and associated systemic factors, to detect, diagnose and manage disease	Ocular Diagnostic Services, plus use of pharmaceutical agents and other procedures to manage ocular conditions/disease

Table 1. Click to enlarge

The founding of the Vietnamese optometry program has been supported by the Vietnamese Ministry of Health (MOH), UPNT, BHVI, VOSH International and several other non-governmental organizations and interested parties. The program is designed to produce World Council of Optometry Competency Level 3 optometrists. This is an optometrist who investigates, examines and evaluates the eye and adnexa and associated systemic factors to detect, diagnose and manage disease, including the use of diagnostic drugs.[6] See **Table 1** for an explanation of the four WCO levels. Therapeutic drugs are taught in the program, but it is expected that the optometrist will not have prescription drug privileges when the law is formalized. There is hope that, when better established, the program could be expanded to award a five-year master's or eventually a Doctor of Optometry degree.

A possible near-term model for the Vietnamese program is the optometry program in Hong Kong. The Hong Kong system has had varying levels of certification, with the highest level allowing full diagnosis and dilation, though the drug formulary is minimal.[7] The lowest level is refraction-only optometrists.[8] Having a multilevel certification would allow for the uncertified refractionists in the country to continue to practice, and in time require certifications for all levels of those working with optical/eyecare patients. A similar law was initiated in Taiwan requiring all refractionists to be certified.[9] The authors' best hope is that the Vietnamese will model the American system of optometry, with full diagnosis, treatment and even some minor surgical procedures such as foreign body removal allowed. This training has already been part of the Vietnamese course at UPNT. The optometric scope of practice in the United States and other parts of the world has been a slow progression over many years, and Vietnam may expect the same. Hong Kong started a board of optometry only as recently as 1984. Ideally, the profession of optometry in Vietnam will evolve into a broad practice to mirror the training that the new optometrists have received. Realistically, however, it will take some time for the general public and the authorities to understand and better appreciate the role of optometry in safeguarding the public health regarding eye care.

Although the first two cohorts from UPNT have begun their careers, Vietnam has not yet adopted a statute to govern the profession of optometry within the public health system. This issue, commonly referred to as the job code, is currently being discussed in the MOH in Hanoi. The job code is the law within the MOH that will govern the profession of optometry in Vietnam. A job code is required for every profession operating within Vietnam's health system. Each job code not only sets salary and remuneration guidance for hospital administrators, but also defines the scope of practice for each profession. Job codes cannot be introduced at any time, but rather only during a period of review. The review happens once every five years, and 2020 was a year of review, and an optometry job code was discussed. However, before being sent to the Prime Minister for signature, the job code must have input and review from several relevant ministries including the Ministry of Home Affairs, the Ministry of Labor and the Ministry of Finance, as well as several committees within the MOH. Until a decision is reached, hospital administrators or department heads have no official information to use in assigning tasks for the optometrists.

This study explores how the first two cohorts of graduates from the UPNT Optometry program have been utilized by the various hospitals to which they have been assigned, as well as their other modes of employment when reported. No review board nor ethics committee was known to be available. However, the World Medical Association's Declaration of Helsinki guidelines for medical research were followed. In addition, this research is eligible for exemption from regulations because it involved only a survey; the primary investigator recorded information in such a way that subjects cannot be readily identified; and any disclosure of identifiable information would not place the subjects at risk.

Methods

The survey was sent online to all 29 graduates from the first two UPNT classes. The response rate was 86% (25 anonymous responses were received). Data analysis was performed using Microsoft Excel (version 365).

Data was organized in simple spreadsheet form. The respondents were nine males (35%) and 17 females (65%). Age was not asked on the survey, but the age of most graduates is within one year of 22. No "non-traditional" students have been admitted to the program to date.

Results/Discussion

Question 1: In what type of work are you currently employed?

The distribution of the graduates' practice locations has been dictated in part by the local health department **(Figure 1)**. Each graduate was guaranteed an assigned job in a public hospital. Several have left these positions to pursue other practice

opportunities. Seven graduates have been assigned to the optometry program at UPNT to serve as the future teaching core of the optometry department. One of these is abroad taking a master's in optometry course, and the rest are working as teaching assistants in both the UPNT Optometry department and in the school's AVC. The AVC is the primary teaching clinic associated with the optometry program. Interestingly, the optometry students are the only student clinicians in the clinic. The medical students are not allowed to practice at the facility. The college clinic was not established as a teaching clinic for the medical students, but rather as a clinic to generate additional income for the university. The medical school's faculty are able to supplement their earnings by working at this clinic. As in the United States, medical educators are among the lowest paid segments of their professions. Several private eye hospitals and ophthalmological offices in the city have employed some graduates as well. Most of the graduates report working more than one job.

The demand for optometrists is expected to grow significantly once the practice parameters are defined by the anticipated job code. Increased demand will likely lead to higher salaries for the new optometrists. Currently, while the average wage in Vietnam is $150 (U.S. dollars, USD) per month, total salary for the optometrists surveyed averaged $425 USD per month for all work undertaken.[10] Although low by Western standards, the wages reflect the scales under which health care is delivered in Vietnam. A basic visit to a public eye hospital costs an uninsured patient approximately 100,000 Vietnamese Dong (VND) ($4.27 USD). Comprehensive exams are not offered, rather everything is problem-focused. If warranted by the initial visit, which includes visual acuity and slit lamp exam, by the ophthalmologist, a refraction may be ordered ($1-$2 USD additional fee). A fundus exam may also be ordered for a nominal additional fee. Examination fees at private ophthalmology offices can range from 200,000 to 500,000 VND ($8.54-$21.34 USD), and services included vary widely from office to office.

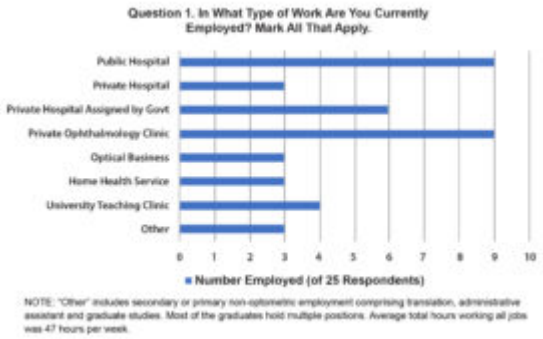

Figure 1. Click to enlarge

Question 2: What exam skill are you personally performing?

The data clearly show that the group of new Vietnamese optometrists are not routinely performing comprehensive examinations in their daily assigned tasks **(Figures 2-7)**. If one considers any average score value over three as what is usually performed as part of the exam, it can be seen that the young optometrists are typically used as refractionists. This would include history-taking, refractive services and some patient education regarding visual status. While disheartening to the graduates and faculty at UPNT who desire that comprehensive optometric exams would be routinely practiced, the level of practice is anticipated to improve when the MOH defines the job code for optometry. When optometrists are recognized as part of the healthcare system, it is expected they will be able to operate independently and perform comprehensive eye care within their given departments. As it is now, the optometrists are not allowed to independently examine patients without a licensed professional, usually an ophthalmologist, signing off on the patient.

Question 2. What Exam Skill Are You Personally Performing?

0 = Never, 1 = Rarely, 2 = Sometimes, 3 = Often, 4 = Always

Survey Question	Mean	Median	Mode	Standard Deviation
A. Receiving patients and taking intake data such as name, date of birth, phone	2.37	3	4	1.45
B. Taking patient history including chief complaint, medical/family history	3.19	3	4	0.96
C. Visual acuity assessment	3.74	4	4	0.81
D. Cover testing/checking for binocularity via other means	2.48	2	2	1.05
E. Ocular muscle testing (versions/saccades)	2.04	2	1	1.06
F. Pupillary testing	2.26	2	2	1.16
G. Amsler grid or another visual field method	1.30	1	1	0.95
H. Objective refraction/retinoscopy	3.41	4	4	1.05
I. Subjective refraction	3.67	4	4	0.73
J. Slit lamp examination	2.11	2	3	1.50
K. Tonometry/IOP measurement	2.30	2	2	1.39
L. Fundus examination	1.74	2	3	1.32
M. Final decision-maker on optical/glasses prescriptions	3.37	4	4	1.04
N. Make ocular health assessments	1.59	1	0	1.42
O. Make ocular health treatment recommendations/referrals	1.56	2	0	1.37
P. Participate in patient education	3.22	4	4	1.09
Q. I have used my other optometric skills such as contact lenses, binocular vision, low vision, myopia control	1.93	2	1	1.17

Figure 2. Click to enlarge

Figure 3. Click to enlarge

Figure 4. Click to enlarge

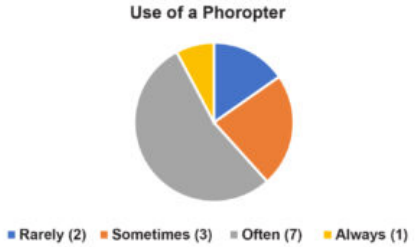

Figure 5. Click to enlarge

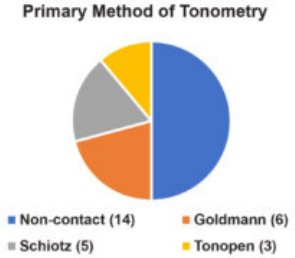

Figure 6. Click to enlarge

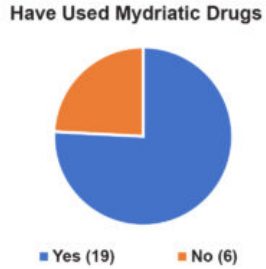

Figure 7. Click to enlarge

Question 3: What are your attitudes and job satisfaction thus far?

Understandably, the young graduates are not fully satisfied with the scope of optometry currently allowed by their direct supervisors (ophthalmologists) **(Figure 8)**. Some ophthalmologists are unaware of what optometrists are trained to do other than refractive care, while others perhaps worry about optometry taking over some of their duties if allowed to become proficient. The young graduates recognize that they have unique training and skills but are not permitted to use their expertise in the current situation. In general, most believe they are underutilized and underpaid for the work they do.

The young optometrists also face some interesting cultural barriers to becoming independent practitioners in the Vietnamese public hospital/public health setting. The culture for young people in this environment is to not speak up or try to educate their superiors about new things. It is expected that the new worker will remain quiet and obediently perform the tasks they are assigned. Although the graduates possess unique knowledge and skill sets as fully trained optometrists, culturally they are not comfortable with advocating for their abilities to their department heads. Furthermore, as newly trained optometrists, they are not yet confident in those optometric skills. Optometric skills need to be practiced and honed daily. They are not able to do this, so it becomes a vicious cycle of improper utilization leading to lack of confidence. The description of knowledge, skills and abilities of an optometrist must come from the job code. Ministerial guidelines in the form of a job code should better inform the administrators and heads of departments and lead to proper utilization.

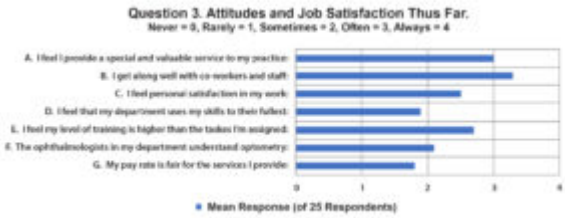

Figure 8. Click to enlarge

When compared with other countries that have established optometric professions in Southeast Asia, the newly trained optometrists in Vietnam will have several crucial tasks to perform as they fight for relevance within the established healthcare norms of their country. The primary task will be to educate the healthcare system of their capability. An equally crucial task will be to educate the public about the value of preventive eye care. While the job code will outline their practice limits, it will be necessary for the optometrists to be well-educated in eye care beyond their practice limits and to develop a system of continuing education within the profession. Finally, creating a Vietnamese optometric association to help organize these efforts would allow the young professionals to form a united voice.

Limitations of this study include the small sample size, the fact that there is no data at this point from the school of optometry in Hanoi regarding these questions, and the possible reticence of some graduates to answer the questions. Another limitation is that no previous studies of this type were found to contrast the findings presented here. One recent study of Nepalese optometrists focused on their attitudes toward the formation of a new optometry school, but not on the satisfaction of the graduates in performing the assigned duties of a new profession in their country.[11]

Conclusion

The first two cohorts of classically trained, WCO Level 3, Vietnamese optometrists have dispersed into a variety of practice settings. The graduates by and large are not fulfilling the role of providing independent comprehensive eye examinations. The graduates are currently being hindered in developing their talents and skills due to the lack of a national optometry law/practice definition and lack of understanding from hospital administrators and department heads about the services

optometrists are trained to provide. They are further hampered by the culture of respect for their elders. This situation has made the daily working routines of the graduates less fulfilling for them. With the adoption of the anticipated job code for optometrists and better organization among the new Vietnamese optometrists, it is hoped that the current situation will change both in terms of the service optometrists will be providing to the public as well as their satisfaction in their new profession.

References

1. Thai V, Yap M. Optometry in Asia. In: Hatch SW, Whitener JC, McAlister WH, Block SS, ed. Optometric Care within the Public Health Community. Cadyville, NY: Old Post Publishing, 2010:5.1-5.27.
2. Zhang Z, McAlister WH, Weaver JL. Scope of Practice and License Regulation of China's Optometrists in the 21st Century: Findings from an Anonymous Survey on Social Media. Poster presented at American Public Health Association Annual Meeting and Expo, Atlanta, GA, Nov. 4-8, 2017.
3. University of Medicine Pham Ngoc Thach [Internet]. Ho Chi Minh City, Vietnam: University of Medicine Pham Ngoc Thach; c2017 [cited 2020 June 12]. Available from: https://www.pnt.edu.vn/university-of-medicine-pham-ngoc-thach.
4. Hanoi Medical University [Internet]. Hanoi, Vietnam: Hanoi Medical University; c2017 [cited 2020 Nov 11]. Available from: https://en.hmu.edu.vn/.
5. Global Optometry Resources [Internet]. Sydney, NSW, Australia: Brien Holden Foundation; [cited 2020 Nov 11]. Available from: https://brienholdenfoundation.org/international-program/learning-resources/global-optometry-resources/.
6. A Global Competency-Based Model of Scope of Practice in Optometry, 2015 [Internet]. World Council of Optometry; [cited 2020 Nov 11]. Available from: https://worldcouncilofoptometry.info/wp-content/uploads/2020/09/Scope-of-Practice.pdf.
7. Optometrist Board Hong Kong Code of Practice [Internet]. Wan Chai, Hong Kong: Supplementary Medical Professions Council; 2008 [cited 2020 Nov 11]. Available from: https://www.smp-council.org.hk/op/file/pdf/op_practice_e.pdf.
8. The Ultimate Guide to Optometrists in Hong Kong [Internet]. Sheung Wan, Hong Kong: Healthy Matters Limited; c2021 [cited 2020 Nov 11]. Available from: https://www.healthymatters.com.hk/the-ultimate-guide-to-optometrists-in-hong-kong.
9. I-chia L. New law to regulate eye exams (Dec 20, 2015) [Internet]. Taipei City, Taiwan: Taipei Times; c1999-2021; [cited 2020 Nov 11]. Available from: https://www.taipeitimes.com/News/taiwan/archives/2015/12/20/2003635237.
10. Average Salary [Internet]. Vietnam Online; c2021 [cited 2020 Nov 11]. Available from: https://www.vietnamonline.com/az/average-salary.html.
11. Kaphle D, Kandel H, Paudel P, Naidoo K. Profile of Nepalese optometrists and their perspectives about a new optometry school. African Vision and Eye Health. 2019;78(1).

Follow

Share

An Incidental Case of Bilateral Multifocal Retinal Pigment Epithelial Detachments in a Patient with Post-Traumatic Stress Disorder: a Teaching Case Report

Catherine Tsang, OD, Justin Simbulan, OD, and Bhagya Segu OD, MPH, FAAO | Optometric Education: Volume 46 Number 3 (Summer 2021)

PDF of Article

Background

Pigment epithelial detachment (PED) results from separation of the basal layer of the retinal pigment epithelium (RPE) and the innermost layer of Bruch's membrane.[2-4] They are most commonly associated with age-related macular degeneration (AMD) but also present in polypoidal choroidal vasculopathy (PCV),[5] hypertensive choroidopathy and conditions that lead to inflammation and ischemia of the choroid, such as Vogt-Koyanagi-Harada disease (VKH).[2,4,6] In addition to hypertension and VKH (a rare autoimmune condition that causes inflammation of multiple organ systems), other systemic associations include renal disease, systemic lupus erythematosus, sarcoidosis and leukemia.[4] Multifocal PEDs are characterized by numerous retinal patches of separated RPE and Bruch's membrane. They are rare but have been proposed to be a variant of central serous retinopathy (CSR). Because affected patients often remain asymptomatic when these lesions are located extrafoveally, they can be monitored without treatment.[1,2] When associated subretinal fluid (SRF) is present with the PED, however, intravitreal anti-vascular endothelial growth factor (anti-VEGF) injections, which suppress new retinal blood vessel growth and permeability, are more readily considered a treatment option. Here, we explore a case of bilateral, extrafoveal, multifocal PEDs by discussing etiological and pathophysiological mechanisms involved and management strategies for the eyecare provider. The objective of this report is to provide fourth-year optometry students an example of an atypical retinal case, as not all patients encountered in the clinical setting present with classic, textbook findings and may be managed differently between clinicians.

Case Description

History

A 73-year-old African American male presented to our clinic with a chief complaint of blurry vision OS without correction. Other than diagnoses of myopia and cataracts OU at his last eye exam three years prior, his ocular history was unremarkable. The patient's medical history included controlled hypertension and a psychiatric diagnosis of post-traumatic stress disorder (PTSD) since 1999. His mental health notes described him as having poor sleep, nightmares, feelings of isolation and paranoia, but the specific experience that contributed to a diagnosis of PTSD, a mental health condition rooted in a past traumatic or life-threatening event, was unknown.[7] Furthermore, this patient's active problem list included alcohol abuse, which is consistent with clinical documents that described him as a "heavy drinker" who was charged with at least three driving offenses for operating a vehicle while intoxicated. He was not taking any medications other than those prescribed for hypertension, and he reported no known drug allergies.

Examination findings

The patient was correctable to 20/20 OD and 20/60 OS, which improved to 20/40 with pinhole. His best-corrected visual acuity (BCVA) was 20/20 in each eye at his last eye exam. Pupils were round and reactive to light and did not exhibit a relative afferent pupillary defect. Extraocular motilities, confrontation visual fields and alternating cover test were all normal. Intraocular pressures measured by Goldmann applanation tonometry were 17 mmHg OD and 15 mmHg OS.

Slit lamp exam revealed a 1+ nuclear sclerotic cataract OD and a 3+ nuclear sclerotic cataract OS, which was the cause of reduced vision OS. All other anterior segment findings were unremarkable. Healthy optic nerves with cup-to-disc ratios of 0.45 OD and 0.50 OS were assessed on fundoscopy. Additionally, several well-delineated, round, orange-reddish posterior pole lesions were observed OU, but were more pronounced OD. These lesions appeared subretinal and extrafoveal and were not associated with other retinal findings.

Optical coherence tomography (OCT) images were acquired OU. While center macular thickness, measuring 248 microns OD and 238 microns OS, and foveal contour were normal OU, multiple extrafoveal PEDs corresponding with the lesions noted on

fundoscopy were visualized on the scans. Of note was a large PED with overlying SRF that was approximately 0.75 disc diameters in size and located superonasal to the macula OD **(Figures 1 and 2)**. An additional PED of approximately the same size was present just inferior to the macula, and a third, smaller PED was visualized temporal to the macula OD. OS images revealed a few small PEDs in the superior, inferior and temporal macula, none of which were associated with SRF **(Figure 3)**. All PED findings on OCT were consistent with serous PED, which typically appears dome-shaped and well-delineated with an elevated, hyper-reflective RPE overlying a hyporeflective and optically empty space.[2,8,9]

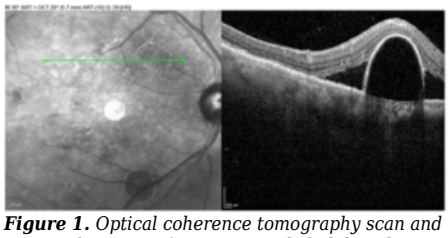

Figure 1. *Optical coherence tomography scan and gray-scale image of pigment epithelial detachment with surrounding subretinal fluid in the right eye. Click to enlarge*

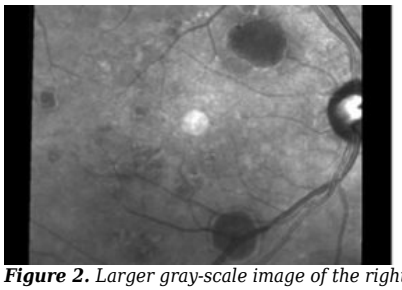

Figure 2. *Larger gray-scale image of the right posterior pole. The dark, round lesions are the pigment epithelial detachments noted on exam and confirmed with optical coherence tomography. Click to enlarge*

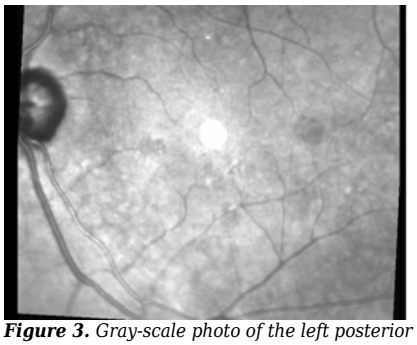

Figure 3. *Gray-scale photo of the left posterior pole. Fewer pigment epithelial detachment lesions are evident in this image. They also appear more faint compared with the pigment epithelial detachments in Figure 2. Click to enlarge*

Treatment

Although asymptomatic patients with PED that spares the fovea can be monitored without treatment, the retinal specialist consulted in this case recommended a monthly series of anti-VEGF injections for the right eye due to the associated SRF. The presence of SRF was suggestive of underlying RPE decompensation that allowed fluid entry into subsensory space, which placed the patient at higher risk for visual compromise.[10] Consequently, he was treated at his first and second follow-up visits, after which SRF in the right eye nearly completely resolved **(Figure 4)**. The underlying PED also exhibited a reduction in height. During his last scheduled injection appointment, however, recurrence of SRF over the superior PED was noted **(Figure 5)**. Given re-emergence of SRF, the patient's treatment schedule was altered from an original treat-and-extend regimen, which would have lengthened follow-up intervals to longer than one month, to two additional monthly injection visits.

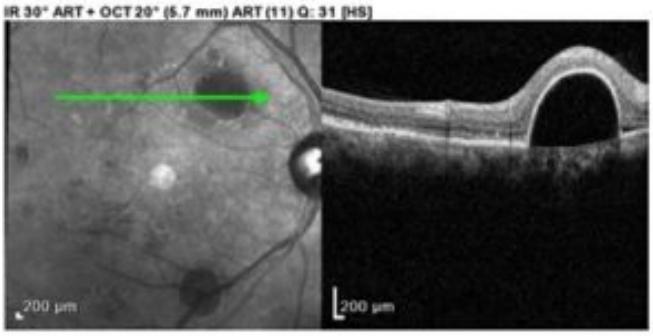

Figure 4. *Optical coherence tomography of the right posterior pole with raster scan of the superior pigment epithelial detachment showing resolved subretinal fluid after two anti-vascular endothelial growth factor injections. Click to enlarge*

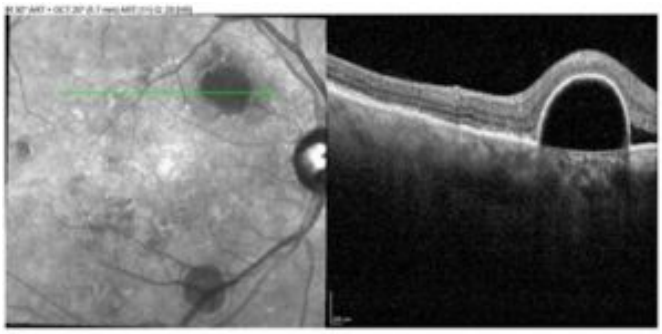

Figure 5. *Optical coherence tomography scan showing recurrent subretinal fluid nasal to the superior pigment epithelial detachment after four anti-vascular endothelial growth factor injections. Click to enlarge*

Educational Guidelines

Key concepts

1. Patients with PED do not always present with symptoms; therefore, careful fundus examination is necessary for detection of pathology
2. Obtaining a thorough medical history is important in atypical cases of PED
3. Specific characteristics of PED on OCT can aid in distinguishing the underlying disease process

4. There is no definite treatment protocol for addressing extrafoveal PED; therefore, co-management with a retinal specialist and close follow-up intervals are important in the prevention of vision loss in patients with these retinal lesions
5. Intraretinal fluid (IRF) and SRF respond more effectively than PED to anti-VEGF therapies

Learning objectives

At the conclusion of this case discussion, participants should be able to:

1. Name ocular conditions most commonly associated with PED
2. Identify helpful ancillary tests that can be used to elucidate the underlying cause of PED
3. Describe the pathophysiology of PED formation in the retina
4. Understand the prognosis of extrafoveal PED and associated findings and how these characteristics determine treatment strategies
5. Comprehend how anti-VEGF therapies work, as well as their relative effectiveness compared with other treatment options

Discussion questions

1. What range of symptoms do patients with PED experience?
2. Which ocular and systemic conditions are most commonly associated with PED?
3. What is the relationship between PED formation and choroidal neovascular membrane (CNVM)?
4. What other retinal findings might be seen in patients with PED and how do these usually impact visual prognosis?
5. Under what conditions would anti-VEGF drugs be indicated for patients with PED?

Assessment of learning objectives

The following ideas are designed to aid the educator in effectively teaching this material and assessing students' learning progress and knowledge.

Students' mastery of retinal anatomy and physiology should be assessed, as a thorough understanding of retinal layers is necessary for accurate OCT interpretation. Using OCT images with different examples of IRF, SRF and PED in the form of a slideshow quiz is one possible evaluation method. Having students draw a cross section of the fundus with appropriate labels and corresponding descriptions of the role of each anatomical part would also be an effective way to measure understanding of retinal anatomy.

Slide quizzes containing images of different PED subtypes, whether in the form of OCT, fundus photographs, fluorescein angiography (FA) or indocyanine green angiography (ICGA), would be useful for evaluating fourth-year students' ability to analyze results of these diagnostic tests and to generate a list of reasonable differential diagnoses based on what the images reveal. After a set of differentials is formed, students should be able to identify the concomitant ocular and systemic manifestations a patient may exhibit for each differential diagnosis.

Finally, assessing students' ability to formulate an effective treatment and management plan can be accomplished by written and/or oral exercises For example, students can document their assessment and plan in a format similar to those in clinical charts, or organize a doctor-patient role-play during which they would provide their patients with exam findings, treatment plans and follow-up intervals.

Discussion

Classification and pathophysiology

PED, which occurs when the RPE and Bruch's membrane separate, can be classified as turbid, hemorrhagic and serous. Additional subtypes based on differing classification systems and underlying pathophysiology include drusenoid, pseudovitelleform, fibrovascular and vascular.[8,9] Currently, the pathological process behind PED is not well-defined and involves myriad pathways.[10] It has been proposed that detachment of the RPE from Bruch's membrane occurs when normal retinochoroidal flow, which is maintained by a net fluid and pressure gradient traveling from the vitreous towards the outer retina, is disrupted. Disturbance of normal chorioretinal osmotic gradients can occur when the choriocapillaris becomes hyperpermeable, as in cases of CSR, or when neovascular vessels leak, as in the setting of wet AMD. Hemidesmosome attachments between the RPE and its basement membrane may also become compromised when hydraulic forces in the eye are altered, further weakening the structural bond between these layers.[4]

While PED is non-specific in nature, it is most commonly observed in wet AMD.[4,9] Serous PED, in contrast, has been

hypothesized to be a variant of CSR, though several PED subtypes can exist simultaneously and are termed "mixed PED."[8,11] PTSD patients may be more prone to developing CSR due to increased levels of norepinephrine in their systems. If these individuals lack proper coping skills and address depression and anxiety with excessive alcohol intake, they may become even more susceptible to retinal disease as multiple, possibly synergistic risk factors would be at play in their ocular and systemic health. The patient in this case was asymptomatic, but many individuals with similar PED presentations complain of blur, metamorphopsia,and shadows or darkening of vision.[4]

Diagnostic testing

OCT is an effective tool for characterizing different PED subtypes. On OCT, serous PED appears optically empty and underlies a hyper-reflective band of RPE, whereas turbid and granular sub-RPE spaces usually indicate the presence of drusenoid and fibrovascular material.[9,11] Fundus autofluorescence (FAF) is also useful for classifying and delineating PED lesions. The serous type features a hyperfluorescent lesion with a hypofluorescent border, while drusenoid PED are either isofluorescent or hyperfluorescent and may be seen with irregular, hyperfluorescent patches corresponding to pigmentary migration.[12] Although OCT and FAF are non-invasive techniques that have been shown to outperform FA in many cases, determining a definitive etiology and prognosis for PED are still successfully achieved with FA and ICGA — gold standard diagnostic tests for cases involving questionable subsensory and sub-RPE fluid.[9,12] In the case of our patient, however, IGCA was not acquired because the retina specialist deemed the PEDs low-risk for spreading or causing visual degradation, and the localized pocket of SRF was being addressed with anti-VEGF injections.[5,9,13]

On FA, serous PED presents as a well-circumscribed area of progressive and evenly distributed hyperfluorescent pooling, whereas slow, irregular filling on FA is consistent with fibrovascular PED.[4,9,12] Due to blockage of fluorescent signal from the choroid in cases of drusenoid PED, ICGA scans appear hypofluorescent during the entire transit time. ICGA images of vascular PED show an area of hyperfluorescence, referred to as a "hot spot," which is suggestive of an underlying neovascular membrane. ICGA scans of serous PED are characterized by mild hypofluorescence in late stages due to obstruction of choroidal signals.[4]

Differential diagnosis

A lack of concomitant ocular findings in our patient led to a working diagnosis of idiopathic, bilateral, multifocal retinal PEDs. AMD, while on the list of differential diagnoses given its common association with PED, was less likely due to the absence of central drusen and pigmentary mottling found in earlier stages of this progressive condition. PCV, which has been proposed to be a subset of AMD and is often associated with multifocal PED secondary to the formation of choroidal aneurysms, typically presents with additional findings including orange bulb-like nodules, exudates and submacular retinal hemorrhages, none of which this patient exhibited.[5,14]

Hypertensive choroidopathy, another potential etiology of PED formation, tends to occur in younger patients with histories of sudden spikes in blood pressure related to life-threatening conditions such as preeclampsia and renal hypertension.[9,15] Accompanying ocular findings include arteriole narrowing, retinal hemorrhages, cotton wool spots, optic disc edema, Elschnig spots and Siegrist streaks.[15] Considering this patient's history of controlled hypertension, age and otherwise normal ocular exam, hypertensive choroidopathy was lower on the list of differentials.

Interestingly, PTSD, a mental health condition stemming from traumatic life experiences that can lead to recurrent panic attacks, prolonged anxiety and depression[16] as well as alcohol abuse — both conditions this patient suffered from — have been suspected etiologies in some reports of multifocal PED. A study published by Roberts and Haine described observations of multifocal PED possessing similar features to CSR in psychologically distressed patients.[17] Lumbroso et al. observed that serous PED, which is consistent with this patient's retinal profile, presents in conjunction with CSR more frequently than other forms of PED, such as multilobular, granular or drusenoid lesions on OCT — findings more commonly seen in AMD.[11] Pan et al. established that endogenous levels of the catecholamine norepinephrine, which plays a role in the CSR disease process, are elevated in PTSD patients compared with psychiatrically healthy patients.[18] Other studies have demonstrated that individuals with poor stress coping mechanisms, including alcohol abuse, are also more likely to exhibit CSR.[18] Regarding the effects of alcohol, Gkotsi et al. introduced a rare case of bilateral multifocal CSR in a patient with alcohol liver disease, hypothesizing that a damaged liver alters fluid homeostasis and choroidal autoregulation while increasing oxidative stress on retinal vasculature.[19]

Although the precise cause of bilateral multifocal PEDs in our patient was unclear and labeled idiopathic in nature, his medical health history of PTSD and alcohol abuse led us to conjecture that a pathophysiological process similar to that of CSR was at play in the alteration of his retinal anatomy and integrity.

Treatment and prognosis

Elucidation of the underlying cause of PED can aid in determining an appropriate treatment plan for patients. If patients are asymptomatic and do not present with complaints characteristic of underlying systemic conditions such as VKH, and if there is lack of co-existing retinal findings, such as those pathognomonic for AMD, PCV and hypertensive choroidopathy, intervention may not be warranted.[2,8] Results of the Prospective OCT Imaging of Patients with Neovascular AMD Treated with Intra-Ocular Lucentis (PrONTO) study showed that PED does not readily respond to anti-VEGF injections when compared with cystic IRF or SRF. It also does not act as a limiting factor in the final visual outcome of patients with neovascular AMD.[20,21] Therefore, observation is a valid management option for PED patients who do not present with neurosensory retinal edema.

Conversely, the PrONTO study confirmed that resolution of IRF or edema within the retinal layers, and SRF or fluid between the neurosensory retina and the RPE, did correlate with improvement in BCVA in study subjects.[20,21] This understanding prompts retinal specialists to recommend anti-VEGF therapy in cases of PED with associated SRF, as was observed in the right eye of the patient in this case. The presence of SRF indicates that there has been breakdown of the outer blood-retinal barrier due to RPE decompensation, which warrants anti-VEGF therapy to prevent risk of vision loss and metamorphopsia.[4,8] If a PED is suspected to be secondary to another ocular or systemic condition, appropriate testing, referrals and therapies should be initiated in a timely manner.

Anti-VEGF therapy acts by inhibiting the angiogenic pathway triggered by vascular endothelial growth factors, cell mediators required for new blood vessel formation. Overproduction of VEGF can lead to pathological neovascularization and hyperpermeability of vessels, resulting in leakage and subsequent retinal edema in an ocular setting.[10,22] By mitigating this process with anti-VEGF agents, neovascularization and its resulting complications can be controlled. This line of therapy has been shown to be more effective than verteporfin photodynamic therapy (PDT) in improving final BCVA.[10,22] Kumar et al. found that aflibercept was superior to ranibizumab in non-responsive patients.[23] Refractory cases of PED in the context of long term anti-VEGF treatment, however, often need to be managed with adjunctive PDT, which selectively kills unhealthy blood vessels through laser activation of an injected photosensitive drug with an affinity for vascular endothelial cells. Laser application post-verteporfin injection leads to inflammation and thrombosis of leaky vessels, halting their pathologic activity.[6,24]

Visual prognosis in extrafoveal cases of PED tends to be positive.[2] Acute presentations that self-resolve or respond well to therapy result in little vision loss. Chronic and refractory cases that lead to fibrotic changes in the retina (especially subfoveally) and those associated with IRF and SRF, however, can impact visual acuity, sometimes permanently. Closely observing these patients is crucial for the preservation of their sight and quality of life.

Conclusion

Bilateral extrafoveal presentations of PED, as seen in this case, are rare. AMD, PCV, CSR, hypertensive choroidopathy and choroidal infection and inflammation are among differential diagnoses to consider. Due to the non-specific nature of PED, it is important to consider the patient's overall health and medications as well as ocular and systemic histories to arrive at an accurate diagnosis. In this patient's case, it was hypothesized that PTSD and alcohol abuse may have played a role in the pathogenesis of the atypical PED lesions noted during the initial exam. This theory, however, is speculative given the amount of research that is still required to clarify the disease process of multifocal PED. FA and IGCA were not obtained during this patient encounter, but the retina specialist elected to follow a treatment plan involving anti-VEGF injections and short follow-up intervals due to concomitant SRF findings. Serous PED that spares the fovea and has no detectable CNVM can often be observed without treatment.[8,21]

References

1. Nagesha CK, Megbelayin EO. Bilateral multifocal retinal pigment epithelium detachment and pachychoroidopathy. Indian J Ophthalmol. 2018;66(4):570-1.
2. Dave VP, Pappuru RR. Idiopathic multiple retinal pigment epithelial detachments – a case report. Saudi J Ophthalmol. 2015 Oct-Dec;29(4):295-7.
3. Pasyechnikova NV, Naumenko VA, Korol AR, Zadorozhnyy OS, Kustrin TB, Nasinnyk IO. Serous pigment epithelium detachment associated with age-related macular degeneration: a possible treatment approach. Med Hypothesis Discov Innov Ophthalmol. Winter 2012;1(4):72-5.
4. Pigment Epithelial Detachment [Internet]. EyeWiki, American Academy of Ophthalmology [cited 2020 Apr 10]. Available from: https://eyewiki.aao.org/Pigment_Epithelial_Detachment.
5. Agange N. Polypoidal Choroidal Vasculopathy [Internet]. EyeWiki, American Academy of Ophthalmology [cited 2020Feb]. Available from: https://eyewiki.aao.org/Polypoidal_Choroidal_Vasculopathy.
6. Lommatzsch A, Heimes B, Gutfleisch M, Spital G, Zeimer M, Pauleikhoff D. Serous pigment epithelial detachment in age-related macular degeneration: comparison of different treatments. Eye. 2009 Dec;23(12):2163-8.
7. Yehuda R. Post-traumatic stress disorder. N Engl J Med. 2002 Jan 10;346(2):108-14.

8. Altintas AGK, Ilhan C. Treatment of Retinal Pigment Epithelial Detachment. Int J Clin Exp Ophthalmol. 2018;2:008-014.
9. Hashas ASK, Göktas A, Atas M. Isolated multiple pigment epithelial detachments with unknown cause. Case Rep Ophthalmol Med. 2014;2014:289107.
10. Nattis A, Josephberg R. Update on the Diagnosis and Treatment of CSC, Retinal Physician, Oct 1, 2015 [Internet]. Doylestown, PA: PentaVision Media; c2021 [cited 2020 Jun 18]. Available from: https://www.retinalphysician.com/issues/2015/october-2015/update-on-the-diagnosis-and-treatment-of-csc.
11. Lumbroso B, Savastano MC, Rispoli M, Balestrazzi A, Savastano A, Balestrazzi E. Morphologic differences, according to etiology, in pigment epithelial detachments by means of en face optical coherence tomography. Retina. 2011;31(3):553-8.
12. Amaro MH, Motta MMDS, Mitre J, Junior JJN, Leite A, Aihara T. Drusenoid retinal pigment epithelium detachments. Rev Bras Oftalmol. 2015 Oct;74(5):325-8.
13. Arias L. Treatment of retinal pigment epithelial detachment with antiangiogenic therapy. Clin Ophthalmol. 2010 Apr 26;4:369-374.
14. Boughton B. Update on Polypoidal Choroidal Vasculopathy [Internet]. American Academy of Ophthalmology, EyeNet Magazine. 2012 Dec [cited 2020 Apr 8]. Available from: https://www.aao.org/eyenet/article/update-on-polypoidal-choroi-al-vasculopathy.
15. Richwine K, Mah D, Mercado KJ. Hypertensive choroidopathy: a teaching case report. Optometric Education. Winter-Spring 2018;43(2).
16. Post-Traumatic Stress Disorder [Internet]. National Institute of Mental Health. U.S. Department of Health and Human Services; 2019 [cited 2020 Jun 16]. Available from: https://www.nimh.nih.gov/health/topics/post-traumatic-stress-disor-er-ptsd/index.shtml.
17. Roberts DK, Haine CL. Idiopathic multiple serous detachments of the retinal pigment epithelium: a report of two cases. J Am Optom Assoc. 1991 Jun;62(6):464-71.
18. Pan X, Kaminga AC, Wen SW, Liu A. Catecholamines in post-traumatic stress disorder: a systematic review and meta-analysis. Front Mol Neurosci. 2018 Dec 4;11:450.
19. Gkotsi D, Gupta M, Lascaratos G, Syrogiannis A, Dhillon B. Alcoholic liver disease and bilateral multifocal central serous retinopathy: a case report. J Med Case Rep. 2013 Feb 13;7(43).
20. Lalwani G, Fung AE, Michels S, Venkatraman AS, Puliafito CA, Rosenfeld PJ. Optical coherence tomography findings in a variable-dosing regimen with ranibizumab (LucentisTM): the PrONTO Study. Invest Ophthalmol Vis Sci. 2006; 47(13):2147.
21. Todorich B, Pepple K, Mruthyunjaya P. Treatment of Pigment Epithelial Detachments in Age-Related Macular Degeneration, Retinal Physician, Nov 1, 2012 [Internet]. Doylestown, PA: PentaVision Media [cited 2020 Jun17]. Available from: https://www.retinalphysician.com/issues/2012/nov-dec/treatment-of-pigment-epithelial-detachments-in-age.
22. Gao Y, Yu T, Zhang Y, Dang G. Anti-VEGF monotherapy versus photodynamic therapy and anti-VEGF combination treatment for neovascular age-related macular degeneration: a meta-analysis. Invest Ophthalmol Vis Sci. 2018 Aug 1;59(10):4307-17.
23. Kumar N, Marsiglia M, Mrejen S, et al. Visual and anatomical outcomes of intravitreal aflibercept in eyes with persistent subfoveal fluid despite previous treatments with ranibizumab in patients with neovascular age-related macular degeneration. Retina. 2013 Sep;33(8):1605-12.
24. Bashshur ZF, Schakal A, Hamam RN, El Haibi CP, Jaafar RF, Noureddin BN. Intravitreal bevacizumab vs verteporfin photodynamic therapy for neovascular age-related macular degeneration. Arch Ophthalmol. 2007;125(10):1357-61.

Follow

Share

Industry News

| Optometric Education: Volume 46 Number 3 (Summer 2021)

PDF of Article

Follow

Share

Interprofessional Coordination of a Patient with Hypertension: a Teaching Case Report

Diane Russo, OD, MPH, FAAO, and Benjamin Young, OD, FAAO | Optometric Education: Volume 46 Number 3 (Summer 2021)

PDF of Article

Background

Hypertension (HTN) is a common systemic condition affecting more than 70 million people in the United States with a global age-standard prevalence of approximately 30%.[1] Left untreated, this condition is responsible for significant cardiovascular disease (CVD) and premature death as a result of end organ damage.[1] The increasing complexity of patient care and health system fragmentation make interprofessional collaboration more important than ever.

Case Description

A 55-year-old male presented to a community health center clinic with complaints of gradual onset, bilateral blur at near with and without correction over the past several months. He had been using +2.50 over-the-counter reading glasses, which previously helped but no longer did. He had no visual complaints at distance. He was not experiencing diplopia, flashes, floaters, burning, itching, redness or tearing.

The patient's last eye exam was three years ago in Haiti, and he had no history of ocular trauma or surgery. His last medical exam was approximately two months prior, and he was a newly established patient to the health center, having recently moved from Florida. His medical history was positive for HTN, although he was unsure how long he had the disease. He was seen by his primary care physician (PCP) two months prior to the eye exam and was restarted on hydrochlorothiazide (HCTZ) 25 mg once a day (QD). According to the patient's medical record, his PCP was considering adding amlodipine if his blood pressure (BP) was not well-controlled on HCTZ alone. At the time of the eye exam, the patient had not taken his medication for the past two weeks because he was on vacation.

The patient had no known drug allergies. His social history was remarkable for former smoking (quit 20 years ago) and drinking alcohol regularly. He was drinking approximately four drinks per day, down from six per day. He was trying to cut down on his own, with a goal of one per day.

His entering uncorrected distance visual acuities were 20/80 OD and 20/100 OS. Entering corrected near visual acuities were 20/50 OD and 20/63 OS. Pupils, extraocular muscles and confrontation visual fields were unremarkable. Manifest refraction findings were +1.75-0.50×090 OD and +2.00-0.50×090 OS, with best-corrected distance visual acuities of 20/25+2 OD and 20/20 OS. His near ADD was +2.25 with 20/20 OU near visual acuity.

Anterior segment findings revealed corneal arcus 360 degrees OU. All other anterior segment findings were unremarkable OU. Intraocular pressures were 19 mmHg OD and 20 mmHg OS with Goldmann applanation tonometry.

Dilated posterior segment findings revealed trace nuclear sclerotic cataracts OU with additional 1+ anterior cortical cataracts with spoking into the visual axis in the right eye. Optic nerves appeared pink, round and healthy with 0.4 cupping OU. The maculae were flat and there was mild arteriolar attenuation OU, indicating stage one hypertensive retinopathy. The peripheral retina OU was flat and intact with no holes or tears.

Knowing the patient had not been taking his HTN medications, we checked his BP in-office. The BP reading (right arm, sitting) was 218/135 mmHg. Because the eye clinic is in a multidisciplinary health center, we contacted Urgent Care to speak with a medical provider and, subsequently, walked the patient down to the Urgent Care department to expedite his care. All healthcare providers at the health center share the electronic health record, Epic, and are able to see each other's records. They also regularly message each other directly through Epic to discuss patient care, ask questions or make requests regarding shared patients. There are also instances when providers may walk to another clinic to have a face-to-face discussion about a patient, but that did not occur in this case. Because the patient faced frequent challenges managing his medication regimen, having access to his health records allowed the providers to obtain a clearer picture of his medication changes and fluctuating BP measurements, which proved helpful in managing his ocular health.

Urgent Care gave the patient clonidine 0.1 mg in-office and restarted him on HCTZ 25 mg PO QD. They also started him on

amlodipine 2.5 mg PO QD. Patient education included discussion of diet, exercise and alcohol restriction.

The patient was advised to return to the eye clinic in one year to monitor his retinopathy because, although he was currently in a hypertensive crisis, his level of retinopathy was mild and indicative of chronic, rather than acute, HTN. He was educated that if he noticed any changes in his vision within the next year, including new onset blur, to return to the eye clinic right away for evaluation. The patient was also educated regarding the presence of cataracts OU with a slight impact on vision in the right eye compared with the left and advised to wear ultraviolet-protective eyewear when outdoors. He was given the glasses prescription found that day and educated regarding potential adaptation to the new prescription because it was his first pair of prescription eyewear.

Following the visit to Urgent Care, the patient saw his PCP two times for adjustment of his HTN medications. Losartan was added, and amlodipine was discontinued. However, one month later the patient was seen in the dental clinic with elevated BP again. The patient was sent to Urgent Care, and his BP at that time was 190/110. At Urgent Care, it was discovered that there was a misunderstanding at the last PCP appointment, which led the patient to discontinue both the HCTZ and amlodipine instead of only the amlodipine. Medications were reviewed, and he was educated to take both the HCTZ and losartan. The provider in Urgent Care also discussed the link between alcohol consumption, BP and end organ damage.

Over the next 10 months, the patient was prescribed HCTZ, losartan, amlodipine and diltiazem in varying dosages and followed closely by his PCP, who adjusted the medications until sufficient BP control was achieved. A summary of patient visits can be found in **Table 1**.

TABLE 1
Summary of the Patient's Clinic Visits

Visit No.	Date	Clinic Visited	HTN Medication Currently Taking	BP (mmHg)	Visit Outcome	RTC
1	8/3/18	Fam Med	None	180/100	Establish care, re-initiate HCTZ, educated on medications and to reduce alcohol consumption	4 days
2	8/7/18	Fam Med	HCTZ 25 mg	178/100	Reinforced patient education, continue to monitor	1 week
3	9/20/18	Eye Care	None	218/135	Walked to Urgent Care same day	1 year
4	9/20/18	Urgent Care	None	225/140 202/120	Given clonidine 0.1 mg in clinic, restart HCTZ 25 mg, start amlodipine 2.5 mg	1 day
5	9/21/18	Internal Med	HCTZ 25 mg, amlodipine 2.5 mg	181/96	Educated on medications and to reduce alcohol consumption	3 weeks
6	10/9/18	Internal Med	HCTZ 25 mg, amlodipine 2.5 mg (skips sometimes)	170/110	Continue HCTZ 25 mg, stop amlodipine, start losartan 50 mg, patient education on the medication directions	2 weeks
7	10/18/18	Dental	losartan 50 mg	> 200/ > 120	Sent to Urgent Care same day	NA
8	10/18/18	Urgent Care	losartan 50 mg	190/110	Continue losartan 50 mg, restart HCTZ 25 mg, patient education on the medication directions	1 week
9	10/26/18	Internal Med	HCTZ 25 mg, losartan 50 mg	170/106	Continue HCTZ 25 mg, increase losartan to 100 mg	3 weeks
10	11/13/18	Internal Med	HCTZ 25 mg, losartan 100 mg	168/100	Continue HCTZ 25 mg and losartan 100 mg, add diltiazem 180 mg	3 weeks
11	12/4/18	Internal Med	HCTZ 25 mg, losartan 100 mg, diltiazem 180 mg	163/78	Continue HCTZ 25 mg and losartan 100 mg, increase diltiazem to 300 mg	2 weeks
12	12/18/18	Internal Med	HCTZ 25 mg, losartan 100 mg	170/100	Continue HCTZ 25 mg and losartan 100 mg, initiate diltiazem 300 mg. Set up with nurse to resolve insurance issues for diltiazem coverage	1 week
13	12/27/18	Internal Med	HCTZ 25 mg, losartan 100 mg, diltiazem 300 mg	159/89	Continue HCTZ 25 mg, losartan 100 mg and diltiazem 300 mg	3 months
14	5/4/19	Dental	HCTZ 25 mg, losartan 100 mg	195/122	Sent to Urgent Care same day	NA
15	5/4/19	Urgent Care	HCTZ 25 mg, losartan 100 mg	160/101	Continue HCTZ 25 mg and losartan 100 mg, restart diltiazem 300 mg, patient education on the use of all three medications	2 weeks
16	7/19/19	Internal Med	HCTZ 25 mg, losartan 100 mg, diltiazem 300 mg	126/80	Continue HCTZ 25 mg, losartan 100 mg and diltiazem 300 mg	3 weeks
17	8/27/19	Internal Med	HCTZ 25 mg, losartan 100 mg, diltiazem 300 mg	124/82	Continue HCTZ 25 mg, losartan 100 mg and diltiazem 300 mg	6 weeks
18	10/4/19	Eye Clinic	HCTZ 25 mg, losartan 100 mg, diltiazem 300 mg	NA	Reviewed medications with patient reporting good adherence to regimen	1 year, next PCP appointment in 4 days
19	10/8/19	Internal Med	HCTZ 25mg, losartan 100 mg, diltiazem 300 mg	134/68	Continue HCTZ 25 mg, losartan 100 mg and diltiazem 300 mg. Unstable housing, set up with social work and case management	3 months

HTN = hypertension; BP = blood pressure; RTC = return to clinic; Fam Med = family medicine clinic; HCTZ = hydrochlorothiazide; Internal Med = internal medicine clinic; NA = not available; PCP = primary care physician

Table 1. Click to enlarge

Six months after his initial eyecare visit, the patient was seen in the dental clinic with elevated BP again. The patient was sent to Urgent Care, and his BP at that time was 160/101. He had been taking the HCTZ and losartan, but thought he was supposed to stop the diltiazem. He was restarted on the diltiazem at that time. Eventually, BP control was achieved with the following medications: HCTZ 25 mg QD, losartan 100 mg QD and diltiazem HCl 300 mg QD.

One year after the initial eyecare visit, the patient presented for his yearly eye exam. Exam findings were stable from the previous exam. Best-corrected visual acuity remained 20/25+2 OD and 20/20 OS, and the cataract did not progress into the visual axis any further OD. There was no worsening of the hypertensive retinopathy. The patient's BP was well-controlled, and he was continuing to work on reducing his alcohol intake. He was currently consuming approximately one beer per day.

Education Guidelines

Key concepts

1. Optometrists can be part of interprofessional collaboration in the management of chronic diseases such as HTN
2. Optometrists are obligated to keep up with changing practice guidelines for ocular and systemic conditions
3. Discussions regarding lifestyle and/or medication management of HTN can take place in the optometrist's office

4. All optometrists should know the clinical manifestations and treatment and management options of hypertensive retinopathy
5. Analysis of optical coherence tomography angiography (OCT-A) can be used to detect retinal microvascular changes associated with HTN

Learning objectives

At the conclusion of this case report, readers should be able to:

1. Research updated HTN management guidelines with evidence-based medicine and differentiate between previous and current BP guidelines
2. Articulate retinal microvascular changes in patients with HTN without significant retinopathy
3. List the risk factors for the progression of hypertensive retinopathy
4. Define and explain interprofessional collaboration
5. Identify pertinent eye exam findings to be communicated to a patient's managing physician
6. Communicate with healthcare providers outside of eye care regarding a patient's systemic health status

Discussion questions

1. What are examples of end organ damage that have been identified as a result of uncontrolled HTN?
2. How can HTN impact ocular health and function?
3. What potentially lethal systemic complications are associated with hypertensive retinopathy?
4. How does the World Health Organization define HTN?
5. What factors impact the reliability of automatic and manual BP measurement?
6. How can OCT be applied in the diagnosis and management of hypertensive retinopathy?
7. What is optometry's role in the multidisciplinary approach to patient care?
8. Why is communication such an important feature of interprofessional collaboration and what barriers/challenges to collaboration exist?
9. How did interprofessional collaboration help aid in the care of this patient?
10. What are some factors that impact medication adherence for patients with HTN and which factors did this patient experience?

Learning assessment

Students may be:

- Broken into small groups and tasked with finding current and past BP guidelines (A discussion can then be facilitated to identify the differences in diagnostic criteria and treatment recommendations)
- Broken into small groups and tasked with researching various opinions, cautions and recommendations regarding potential overtreatment of HTN and factors that might mitigate or exacerbate such incidents
- Assigned to research journal articles on the topic of OCT-A and its use in assessing hypertensive retinopathy
- Tasked with writing a letter to a patient's PCP or an Urgent Care physician explaining the ocular exam results and in-office BP findings
- Assigned roles as patient and doctor and role-play a scenario in which the doctor obtains details related to medication adherence from the patient utilizing the factors in Table 2

Discussion

Anatomical changes that occur as a result of hypertensive end organ damage have been identified in the heart, brain, kidneys and retina.[2] The pathology observed in each of these organs shares a common mechanism of arterial damage and atherosclerosis, which means the clinical appearance of the ocular fundus vasculature as a result of HTN likely mimics the changes taking place throughout the rest of the body.[2]

Currently, the pathophysiology of HTN is widely understood under a "mosaic theory" model due to the multifactorial nature of the condition.[3] Several modifiable risk factors, such as high sodium intake, low potassium intake, excessive alcohol intake and obesity, have been found to have a causal relationship with elevated BP.[1] While African and Hispanic Americans have a significantly higher age-standardized prevalence of HTN, there is no evidence to support that this disparity is a result of genetic factors.[1] A growing body of evidence also shows that systemic HTN does not often occur in isolation and is typically accompanied by other diseases such as diabetes.[3] Because HTN is such a complex and multivariate process, it is often impossible to point to one specific etiology for each patient who develops this condition. Regardless of how HTN developed in an individual patient, lowering BP with oral medication is the mainstay for decreasing the risk of premature death from end

organ damage.

Optometrists are understandably most concerned with the eye as it represents end organ damage from HTN. Long-term uncontrolled elevated BP leads to vasospasm of the retinal arterioles as well as progressive intimal thickening, hyperplasia of the medial wall and hyaline degeneration,[4] which the clinician observes as arteriolar narrowing and artery-vein nicking. If BP remains high for a long enough period of time, the blood-retinal barrier breaks down, which leads to exudation, retinal ischemia and optic nerve head elevation. Current therapeutic strategies involve addressing the underlying pathologically increased BP, and oral anti-hypertensive medications are almost always prescribed by PCPs.

However, the role of the eyecare provider does not end with the ocular manifestations of HTN. In patients with minimal hypertensive retinopathy, the early detection of uncontrolled HTN is even more important to prevent other end organ damage because the microvascular changes the optometrist observes in the retinal vasculature likely mirrors the microvascular changes that take place throughout the body. The American Heart Association identifies CVD, heart failure and stroke as the most significant sequelae of this damage.[5] Increasing evidence suggests that the presence of hypertensive retinopathy is an independent risk factor for cardiovascular dysfunction.[6] Additionally, the presence of hypertensive retinopathy has been associated with an increased risk of potentially lethal complications of ST-segment elevation myocardial infarction (STEMI) thrombolysis.[7] Furthermore, one study of 2,907 participants showed a significant association between hypertensive retinopathy and stroke.[8] These correlations of hypertensive retinopathy with potentially lethal systemic complications underscore the importance of ensuring that the patient's BP is under control, in addition to not adversely affecting their ocular health.

In-office blood pressure measurement

To adequately address the potential implications of hypertensive retinopathy for the patient, a holistic approach is indicated. For the eyecare provider, this means checking systolic and diastolic BP in-office. The World Health Organization defines HTN as a systolic BP of greater than 140 mmHg and/or a diastolic BP of greater than 90 mmHg.[9] A manual or automatic wrist cuff may be used as a screening tool in-office to obtain reliable results. Despite anecdotal claims that automatic wrist cuffs overestimate BP, a meta-analysis in 2019 concluded that when used appropriately, automatic BP measurements conducted in-office are actually more accurate and repeatable than manual BP measurements in identifying patients with possible HTN.[10] However, this accuracy is predicated on proper measurement conditions, and the most reliable results are obtained when the patient is sitting with their legs uncrossed and arm supported at heart level.[11] Several studies have also emphasized the importance of cuff size, as cuffs that are too small tend to overestimate BP regardless of whether manual or automatic measurements are taken.[3]

The Joint National Committee (JNC) developed one of the most widely cited set of guidelines for the management of HTN. However, there is no paucity of recommendations, as the American Heart Association acknowledges nine other hypertensive treatment recommendations in addition to the JNC 8.[5] While this abundance of guidelines may make it difficult for eyecare providers to gauge whether their patient's HTN is "controlled," these guidelines generally follow the trend of aiming for a BP less than 140/80, with more aggressive goals aimed at patients with diabetes and chronic kidney disease.

Ancillary testing

OCT is a useful tool for monitoring the progression of hypertensive retinopathy and is especially valuable in its ability to detect the presence of macular edema. Intra-retinal fluid and subretinal fluid may be observed and indicate the presence of severe hypertensive retinopathy.[12] This fluid typically accumulates around the optic nerve head or around arterioles, but may extend further if BP is elevated beyond a systolic reading of 240.[12] Changes from HTN may also be visualized in the choroid, and OCT with enhanced-depth imaging has revealed a substantial increase in choroidal thickness in eyes as a result of systemic HTN.[12]

More recently, OCT-A has been used to detect and follow microvascular changes in the retina. OCT-A has the ability to detect minute changes in vessel density and the superficial retinal microvasculature.[13] Preliminary research has revealed that patients with HTN show changes in these parameters, which may be a more objective and measurable way to follow these patients over time.[14] As our understanding of this technology progresses, OCT-A could be used to supplement systemic medical management with the potential to spare patients the complications of more severe organ damage. For example, one study found a significant association between retinal vessel diameter and coronary artery stenosis.[12] These findings indicate the potential of OCT-A to aid in the risk calculation for myocardial infarction. OCT-A was not available in the clinic where this patient was seen, but as the technology becomes more widely available it will be a consideration in the management of patients with HTN.

Interprofessional collaboration

The terminology related to interprofessional collaboration is variable. For purposes of this discussion, interprofessional collaborative care will be defined as "the provision of comprehensive health services to patients by multiple caregivers from

different professions who work collaboratively to deliver quality care within and across settings."[15] For this case study, the manner in which clinicians worked to meet the needs of this patient was as a multidisciplinary team. This has been defined as "situations where several different professionals work on the same project but independently or in parallel."[16]

In addition to the ocular health care of the patient, this case has several aspects that can and should be elaborated. First, the number of visits to healthcare providers during a 14-month period to address a single healthcare issue is voluminous. The summary of visits provided in this case study is not exhaustive, meaning that this patient had even more healthcare visits during the period covered. Second, an interprofessional group of clinicians was involved in the identification, treatment and management of this patient's HTN. Third, adherence to the treatment regimen recommended to this patient was difficult, and several factors contributed to this. Lastly, optometrists are part of the healthcare system and should participate in facilitating care on behalf of their patients.

The triple aim in healthcare refers to addressing the patient experience, population health and healthcare costs.[17] As such, the integration and coordination of care has become a growing area of focus. Improved patient care outcomes, particularly for chronic diseases such as BP control for HTN, and adherence to medication regimens have been fostered through interprofessional collaboration.[15]

Being co-located in the same building, the optometry and dental clinicians were able to facilitate timely care through referrals to Urgent Care when the patient presented in hypertensive crisis. Urgent Care clinicians managed the patient's acute needs and the PCP and nurse collaborated for chronic care. One study would classify this multidisciplinary approach as collaboration via referral and counter-referral.[18] While optometrists can be valuable members of a multidisciplinary team communicating in real time, according to a 2017 survey by the American Optometric Association, only 14% of respondents practiced in a multidisciplinary setting.[19] This increases the likelihood that collaboration via referral and counter-referral is more likely for practicing optometrists in siloed environments. This emphasizes the importance of developing and maintaining healthy referral relationships with other healthcare practitioners.

Other team approaches to care include those which are interdisciplinary and transdisciplinary, indicating elevating levels of coordination and shared decision-making. One study identified themes related to interprofessional collaboration including communication and clinical interaction, shared philosophy, power and hierarchy, physical environment and financial considerations.[20] Barriers to collaboration are also related to these themes. Lack of understanding of the roles and responsibilities of other health professionals, entrenched perception of hierarchy and power dynamics, lack of trust related to perceptions of competency, physical separation impeding the ability to communicate, and lack of time to facilitate collaboration have all been reported as barriers.[21–23]

Interprofessional communication

Interprofessional communication is a specific area of concern for interprofessional collaboration. In addition to having an underlying understanding of provider roles and a shared vision or philosophy, the general approach to patient care may vary.[21–25] For example, a holistic approach rooted in emotional intelligence taught in nursing school is more likely to differ from an objective, structured, succinct approach taught in medical schools.[24] It is, therefore, important to understand one's audience and adjust accordingly when communicating patient findings. However, there is less coverage in the published literature on how other clinicians, such as optometrists, dentists, pharmacists, etc., are taught and what their preferences are regarding communication. Additional studies in this area would be beneficial.

Medication adherence

The patient in this case study had difficulty adhering to the medication regimen because of frequent changes, running out of refills and difficulty obtaining a medication due to insurance issues. Five categories have been identified as factors that may impact medication adherence.[26] These categories of factors include sociodemographics, healthcare team/healthcare system, therapy-related, condition-related and patient-related **(Table 2)**.[26,27] Of the factors impacting this patient, those that were therapy-related included the complex medication regimens and treatment changes, while those involving the healthcare system were access to and cost of care, and those involving sociodemographics were unstable housing and lower income. While these are factors we may be aware of, there are many factors listed in the table, notably those in the healthcare system column and patient-

TABLE 2
Five Categories of Factors Impacting Adherence to Prescription Medications for Hypertension[a]

Therapy-Related	Healthcare Team/ Healthcare System	Condition-Related	Sociodemographics	Patient-Related
Complex regimens[b]	Access to and cost of care[b]	Multiple chronic conditions	Homeless, unstable home[b]	Deny diagnosis
Treatment changes[b]	Patient-centeredness	Drug/alcohol use disorder	Low income, poverty[b]	Perception of illness severity/future impact
Treatment failure	Communication style	Depression, psychoses	Young and very old adults	Perception of treatment efficacy
Time to benefit	Patient-clinician relationship	Dementia	Social support	Fear dependence or adverse effects
Adverse effects	Lack of team-based care	Major disability	Copayments	Lack knowledge/ misunderstanding
Treatment duration	Clinician burnout	Symptom severity	Health literacy	Forget
Refill frequency	Fail to detect clues	Quality of life	Transportation, rural residents	Limited follow-up
Refill consolidation	Lack of knowledge/QI support		War, disasters	Low self-efficacy/ discount future
	Pay for volume			Alternative therapy

[a]Data derived and adapted from World Health Organization and Burnier M[26,27]
(*) indicates applicable factors for the patient in this case
QI = quality improvement

Table 2. Click to enlarge

related column, that could be significantly impacting our patients' perceptions of care. It is important for the clinician to keep the many challenges to adherence in mind when interacting with patients, counseling/educating patients on their medications, and/or troubleshooting barriers to care.

Conclusion

A significant amount of interprofessional collaboration was required to coordinate the management of this patient's BP and overall health status. Monitoring of the patient's BP, timely verbal communication between staff and providers, and prompt referrals between clinics facilitated necessary and appropriate care. Each provider played a vital role in delivering a consistent message regarding the importance of medication adherence, balanced diet, exercise and reduced alcohol consumption via verbal and written patient education at each visit. Eventually, this collective effort resulted in effective stabilization of this patient's BP. This case highlights the important role optometrists can and should play in caring for the whole patient in addition to caring for their ocular health.

References

1. Mills KT, Stefanescu A, He J. The global epidemiology of hypertension. Nat Rev Nephrol. Published online 2020. doi:10.1038/s41581-019-0244-2.
2. Kolman SAM, Van Sijl AM, Van Der Sluijs FA, Van De Ree MA. Consideration of hypertensive retinopathy as an important end-organ damage in patients with hypertension. J Hum Hypertens. Published online 2017. doi:10.1038/jhh.2016.49.
3. Elliott WJ. Systemic hypertension. Curr Probl Cardiol. Published online 2007. doi:10.1016/j.cpcardiol.2007.01.002.
4. Wong TY, Mitchell P. Hypertensive retinopathy. N Engl J Med. Published online 2004. doi:10.1056/NEJMra032865.
5. Kovell LC, Ahmed HM, Misra S, et al. US hypertension management guidelines: a review of the recent past and recommendations for the future. J Am Heart Assoc. Published online 2015. doi:10.1161/JAHA.115.002315.
6. Grosso A, Cheung N, Veglio F, Wong TY. Similarities and differences in early retinal phenotypes in hypertension and diabetes. J Hypertens. Published online 2011. doi:10.1097/HJH.0b013e3283496655.
7. Jibran MS, Habib SA, Khan SB. Hypertensive retinopathy: a prognostic factor for morbidity and mortality after acute ST elevation myocardial infarction. J Coll Physicians Surg Pakistan. Published online 2019. doi:10.29271/jcpsp.2019.03.205.
8. Ong YT, Wong TY, Klein R, et al. Hypertensive retinopathy and risk of stroke. Hypertension. Published online 2013. doi:10.1161/HYPERTENSIONAHA.113.01414.
9. Noncommunicable disease education manual for primary health care professionals and patients [Internet]. Manila: WHO Regional Office for the Western Pacific; 2017 [cited 2020 Sept 14]. Available from: https://apps.who.int/iris/handle/10665/254746.
10. Roerecke M, Kaczorowski J, Myers MG. Comparing automated office blood pressure readings with other methods of blood pressure measurement for identifying patients with possible hypertension: a systematic review and meta-analysis. JAMA Intern Med. Published online 2019. doi:10.1001/jamainternmed.2018.6551.
11. Bilo G, Sala O, Perego C, et al. Impact of cuff positioning on blood pressure measurement accuracy: may a specially designed cuff make a difference? Hypertens Res. Published online 2017. doi:10.1038/hr.2016.184.
12. Ahn SJ, Woo SJ, Park KH. Retinal and choroidal changes with severe hypertension and their association with visual outcome. Investig Ophthalmol Vis Sci. Published online 2014. doi:10.1167/iovs.14-14915.
13. Lee WH, Park JH, Won Y, et al. Retinal microvascular change in hypertension as measured by optical coherence tomography angiography. Sci Rep. Published online 2019. doi:10.1038/s41598-018-36474-1.
14. Hua D, Xu Y, Zeng X, et al. Use of optical coherence tomography angiography for assessment of microvascular changes in the macula and optic nerve head in hypertensive patients without hypertensive retinopathy. Microvasc Res. Published online 2020. doi:10.1016/j.mvr.2019.103969.
15. Lutfiyya MN, Chang LF, McGrath C, Dana C, Lipsky MS. The state of the science of interprofessional collaborative practice: a scoping review of the patient health-related outcomes based literature published between 2010 and 2018. PLoS One. 2019 June;14(6):e0218578. doi:10.1371/journal.pone.0218578.
16. D'Amour D, Ferrada-Videla M, San Martin Rodriguez L, Beaulieu MD. The conceptual basis for interprofessional collaboration: core concepts and theoretical frameworks. J Interprof Care. 2005 May;19 Suppl 1:116-31. doi: 10.1080/13561820500082529.
17. Berwick DM, Nolan TW, Whittington J. The triple aim: care, health, and cost. Health Aff. 2008 May-Jun;27(3):759-769. doi:10.1377/hlthaff.27.3.759.
18. Saint-Pierre C, Herskovic V, Sepúlveda M. Multidisciplinary collaboration in primary care: a systematic review. Fam Pract. 2018 Mar 27;35(2):132-141. doi:10.1093/fampra/cmx085.
19. 2017 Practicing Optometrists & Their Patients Executive Summary [Internet]. American Optometric Association; [cited 2020 Sept 14]. Available from: https://store.aoa.org/Product/viewproduct/?ProductId=10318782.

20. Seaton J, Jones A, Johnston C, Francis K. Allied health professionals' perceptions of interprofessional collaboration in primary health care: an integrative review. J Interprof Care. Published online 2020. doi:10.1080/13561820.2020.1732311.
21. McDonald J, Jayasuriya R, Harris MF. The influence of power dynamics and trust on multidisciplinary collaboration: a qualitative case study of type 2 diabetes mellitus. BMC Health Serv Res. 2012 Mar 13;12:63. doi:10.1186/1472-6963-12-63.
22. Supper I, Catala O, Lustman M, Chemla C, Bourgueil Y, Letrilliart L. Interprofessional collaboration in primary health care: a review of facilitators and barriers perceived by involved actors. J Public Health (United Kingdom). 2015 Dec;37(4):716-727. doi:10.1093/pubmed/fdu102.
23. Bollen A, Harrison R, Aslani P, van Haastregt JCM. Factors influencing interprofessional collaboration between community pharmacists and general practitioners – a systematic review. Healh Soc Care Community. Published online 2018. doi:10.1111/hsc.12705.
24. Foronda C, MacWilliams B, McArthur E. Interprofessional communication in healthcare: an integrative review. Nurse Educ Pract. 2016 Jul;19:36-40. doi:10.1016/j.nepr.2016.04.005.
25. Nguyen J, Smith L, Hunter J, Harnett JE. Conventional and complementary medicine health care practitioners' perspectives on interprofessional communication: a qualitative rapid review. Medicina. Published online 2019. doi:10.3390/medicina55100650.
26. Adherence to Long-Term Therapies. Evidence for Action [Internet]. Geneva, Switzerland: World Health Organization; 2003. Available from: https://apps.who.int/iris/bitstream/handle/10665/42682/9241545992.pdf.
27. Burnier M, Egan BM. Adherence in hypertension. Circ Res. 2019 Mar;124(7):1124-1140. doi:10.1161/CIRCRESAHA.118.313220.

Follow

Share

Ocular Ischemic Syndrome: a Teaching Case Report

Evelynne Chavez, OD, and Andrea Yiasemis, OD, FAAO | Optometric Education: Volume 46 Number 3 (Summer 2021)

PDF of Article

Background

While the primary focus of eyecare providers is to provide treatment and care for the structures confined within the orbital area, clinical findings that necessitate a systemic intervention often may arise. Ocular ischemic syndrome (OIS) is a prime example of a serious ocular condition that sometimes can signal severe systemic neurological damage. With the proper team in place, a patient's overall well-being can be enhanced. We present a case report of a 65-year-old male with chronic OIS and accompanying complete stenosis of the left internal carotid artery (ICA). Furthermore, we review the epidemiology, pathogenesis, signs, symptoms, differentials, diagnostic and ancillary testing available, as well as both systemic and ocular treatment options. The intended audience is third- and fourth-year optometry students, optometry residents and current practitioners.

Case Descrption

A 65-year-old African American male presented to clinic for a routine eye exam with a chief complaint of blurry vision at near and some dryness symptoms. His previous ocular history was unremarkable with his last exam being two years ago. Personal eye history was void of any injuries or surgeries. His personal medical history was significant for carotid artery stenosis, dyslipidemia, essential hypertension, cerebral infarction, peripheral vascular disease, chronic periodontitis and neoplasm of the tonsils. His medications included atorvastatin, clopidogrel, metoprolol and nifedipine.

Entrance testing, including cover test, extraocular muscles, confrontations, pupils and visual field screener, were all normal. With an updated refraction, the right eye was correctable to 20/20 while the left eye was correctable to 20/25+2. Intraocular pressure (IOP) was 16 mmHg in both the right and left eye. Anterior segment findings were within normal limits in both eyes. Posterior segment findings were significant for dilated veins and extensive dot-blot hemorrhages in the mid-periphery of the left eye **(Figure 1A)**. The right eye did not demonstrate any retinopathy. The patient was tentatively diagnosed with OIS in the left eye and referred for carotid ultrasound. He was instructed to return to the eye clinic for a fluorescein angiogram (FA).

The patient returned approximately a month later and had best-corrected visual acuity (BCVA) of 20/40 without improvement from pinhole in the right eye and 20/70 with pinhole improvement to 20/30 in the left eye. Gonioscopy was performed at this time and no neovascularization of the angle or iris was identified. IOP at this follow-up visit was 18 mmHg in the right eye and 12 mmHg in the left eye. Anterior and posterior segment findings were stable since the previous exam. Carotid ultrasound results were reviewed with findings of persistent complete occlusion of the left ICA and 50% stenosis of the right ICA **(Figure 2)**. On FA right eye findings were inconspicuous, while the left eye showed leakage at the macula, patchy areas of ischemia in the periphery, and delayed choroidal and retinal arteriovenous filling times **(Figure 1B)**. At this time the patient was simultaneously being evaluated by his cardiologist and vascular surgeon who decided to continue to closely monitor him instead of recommending surgical intervention for his stenosis. The patient was subsequently lost to follow-up for a couple of years before returning with BCVA in the right and left eye of 20/40. IOP at that visit was 18 mmHg in the right eye and 14 mmHg in the left eye with mid-peripheral hemorrhages still visible on fundus exam of the left eye. Other anterior and posterior findings were similar to previous findings. Throughout the years, findings in this patient have remained relatively stable with mild improvements in retinopathy of the left eye and without the development of neovascular complications. IOP has also stayed within normal range and is relatively symmetric between eyes. Surgery has continuously been deferred, and the patient is monitored annually by his vascular surgeon.

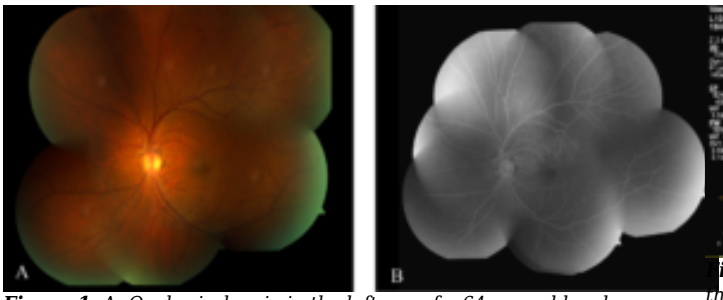

Figure 1. *A: Ocular ischemia in the left eye of a 64-year-old male. The retina exhibited mid-peripheral hemorrhages, dilated veins and narrowed arteries. B: Fluorescein angiography of the same eye.*
Click to enlarge

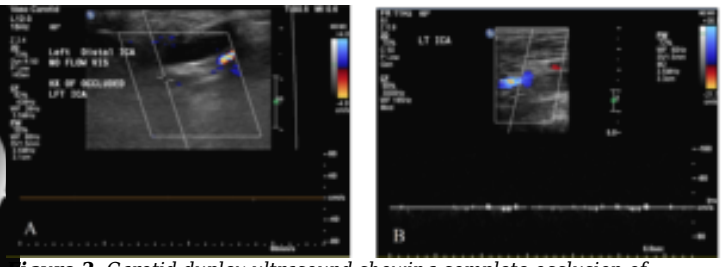

Figure 2. *Carotid duplex ultrasound showing complete occlusion of the left internal carotid artery in a 64-year-old male.*
Click to enlarge

Education Guidelines

Learning objectives

1. Become familiar with the ocular manifestations of OIS
2. Become familiar with the systemic manifestations of OIS
3. Understand that ocular manifestations of OIS may be the first sign of a potentially life-threatening underlying health condition

Key concepts

1. Understand the pathophysiology of OIS
2. Become familiar with the optometrist's role in diagnosis
3. Become familiar with how to manage patients with OIS

Discussion questions

1. What is the pathogenesis of OIS?
2. What are the symptoms of OIS?
3. What are the clinical signs of OIS?
4. What are some differential diagnoses that should be considered in cases of suspected OIS?
5. What are some ancillary tests that could be performed to aid in the diagnosis of OIS?
6. What ocular and systemic treatment is indicated for patients with OIS?

Literature review

OIS is a condition found more commonly in the elderly at a mean of 65 years of age.[1] It is rarely seen in those younger than 50. Additionally, there is a stronger male predilection; men are affected twice as often as women. This has been associated with an increased incidence of underlying atherosclerotic disease in males. Moreover, OIS tends to be unilateral in the majority of cases. No major differences in racial incidence have been recognized.

Discussion

Teaching instructions: The authors recommend that participants read each discussion question and attempt to answer before reading the answers provided in the text. Participants may work individually or together in small groups. Learning objectives may be assessed by comparing participants' responses to the answers provided.

What is the pathogenesis of ocular ischemic syndrome?

Atherosclerotic disease has been identified as the primary culprit in the development of OIS. Other less common causes include Bechet's disease, giant cell arteritis, aortic arch syndrome, Takayasu arteritis, carotid artery dissecting aneurysm and fibrovascular dysplasia.[2,3] Case studies have demonstrated that OIS also may develop from complications from radiotherapy of nasopharyngeal carcinoma or after intravitreal injections of bevacizumab.[4,5] Another recent case study reported OIS leading to blindness after botched facial filler injections.[6] Frequently found comorbidities contributing to the patient's poor overall cardiovascular health include hypertension and diabetes mellitus.[7] Moreover, systemic vascular diseases such as ischemic

heart disease, peripheral vascular disease, history of transient ischemic attacks or prior cerebrovascular accidents are commonly a part of the patient's medical history.

Patients who develop OIS are likely to have a 90% stenosis of the ipsilateral common carotid artery or ICA leading to ocular hypoperfusion.[8] In 50% of cases the artery may even be completely stenosed. Poor collateral circulation between the internal and external carotid or between both ICAs have been demonstrated to increase the risk of development of OIS.[2,9] Some studies have shown that those with well-developed collateral circulation may have complete obstruction of the ICA without the development of OIS.[10] Conversely, other patients with poorly developed collateral systems and as low as 50% stenosis of the ICA may go on to develop this condition.[1,2,9] While the severity of occlusion may be clinically significant, OIS may be the initial manifestation of carotid stenosis in some patients. Additionally, these patients may suffer from further exacerbation of retinal ischemia when blood flow is reversed and shunted away from the eye through the ophthalmic artery (OA) into the intracranial circuit in what has been termed steal phenomena.[11,12] Irrespective of the cause of the altered blood flow dynamic, the results are reduced central retinal artery pressure producing low perfusion pressure and decreased blood flow to the orbit ensuring widespread ocular hypoxia. **Table 1** summarizes factors affecting the pathogenesis of OIS.

TABLE 1
Factors Affecting Pathogenesis of Ocular Ischemic Syndrome

Laterality of stenosis	Degree of stenosis
Absence or presence of collaterals	Chronicity of carotid artery disease
Associated systemic vascular diseases	Anastomotic channels created to shunt blood flow

Table 1. *Click to enlarge*

What are the symptoms of OIS?

Symptoms in patients with OIS can vary and may even be absent. Vision loss is a common cause for concern that often leads patients to seek care. Vision changes may arise from optic nerve (ON) damage from secondary glaucoma or from acute to chronic retinal ischemia.[13] This can manifest as either sudden, such as an episode of amaurosis fugax, or slow changes in eyesight. A retrospective study by Brown et al. found the majority of patients noted a gradual decrease in visual acuity over the course of weeks to months, while approximately one in eight patients noticed reduced vision over a period of days or minutes.[8] In cases of acute vision loss, embolization of the central retinal artery may be responsible.[13] The degree of vision loss at presentation may vary with roughly one-third of patients having visual acuity of counting fingers or worse, 20/50 to 20/200, or 20/20 to 20/50.[7] A predictive factor of visual outcomes is acuity at initial presentation, as those with poorer acuity are less likely to demonstrate improvement and likely will remain stable or deteriorate.[9] The presence of neovascularization at the iris has also been associated with poorer visual outcomes.

Other visual complaints patients may present with include delayed visual recovery after being exposed to bright light.[14] This may be explained by macular ischemia causing delayed photoreceptor regeneration.[14] Additionally, patients with OIS may experience a variety of visual field defects or may have completely unaffected peripheral vision.[1,2,9]

Pain can be another common symptom in patients with OIS. The pain may be felt as part of the eye or in the periorbital area and is commonly associated with the presence of neovascular glaucoma (NVG).[1,2,9,13] However, hypoxia to the eye or surrounding dura mater may also be the cause, especially in the setting of normal IOP. The pain is typically described as dull with a gradual onset and may be lessened when the patient lies down.[2]

What are the signs of OIS?

On clinical exam the patient may present with either anterior or posterior segment involvement or both. The most potentially devastating anterior segment finding is neovascularization of the iris and/or angle.[15] This may result in additional complications in managing the obstruction to aqueous outflow and contribute to the development of secondary glaucoma.[1,2] However, due to extensive ischemia impairing ciliary body function, aqueous production could be reduced, which may cause normal to hypotonous IOP, even in the presence of neovascularization.[15] Additionally, a low-grade inflammatory response may sometimes be noted in the anterior chamber.[2,8,13] This inflammatory response can often be related to an iridocyclitis and is usually mild with flare outweighing the presence of cells.[2] Due to its commonly unilateral nature, patients with OIS may also exhibit an asymmetrical appearance in cataracts with the more opaque lens ipsilateral to the occluded artery.[1,2,9] Moreover, atrophy of the iris and sphincter muscle may occur, resulting in a fixed and semi-dilated pupil or a minimal, sluggish reaction to light.[1,2,13] Further anterior segment findings can include conjunctival and episcleral vessel dilation, scleral melting, synechiae, spontaneous hyphema, corneal edema and bullous keratopathy **(Table 2)**.[1,2]

TABLE 2
Clinical Signs of Ocular Ischemic Syndrome

Anterior Segment	Posterior Segment
Conjunctival and episcleral injection	Ischemic optic neuropathy (2-18%)
Corneal edema	Neovascularization of the optic nerve (8-37%)
Fixed semi-dilated pupil	Macular edema
Sluggish reaction to light	Macular capillary telangiectasias
Iris atrophy	Cherry-red spot (12%)
Neovascularization of the iris/irido-corneal angle (60%)	Emboli
Indocyclitis (20%)	Narrowed retinal arteries
Spontaneous hyphema	Dilated retinal veins
Anterior or posterior synechia	Arteriovenous communications
Asymmetric cataract	Spontaneous retinal arterial pulsations
Scleral melting	Retinal hemorrhages (80%)
	Microaneurysms
	Cotton wool spots
	Neovascularization elsewhere
	Vitreous hemorrhage
	Chorioretinal atrophy
	Asymmetric choroidal thickness

Percentages indicate the prevalence of the clinical sign among ocular ischemic syndrome cases

Table 2. *Click to enlarge*

When the entire eye is not involved, it is more common to observe posterior segment findings only (Table 2). These may include dilated retinal veins with narrowed retinal arteries, anterior and posterior ischemic optic neuropathy, cotton wool spots, retinal arterial pulsations and chorioretinal atrophy.[1,2,15] Retinal arteriovenous communications may also be identified adjacent to ischemic retinal areas. Hypoxia from lack of retrobulbar blood flow could produce ischemic damage to the ON in the context of what can present as normal-tension glaucoma. Conversely, damage to the ON secondary to the development of NVG may develop.[15] Due to widespread ischemia and the retina's production of vascular endothelial growth factor (VEGF), retinal neovascularization may occur with a higher incidence at the disc.[8] Subsequently, vitreous hemorrhages may develop. Classically, retinal hemorrhages and microaneurysms are often seen in the mid-periphery.[1,2,15] Microaneurysms may also be observed in the macula, and in combination with capillary telangiectasias can lead to macular edema. A cherry-red spot at the macula may alternatively be found when IOP exceeds the central retinal artery perfusion pressure in glaucomatous eyes or when an embolus occludes the central retinal artery.[2] More recently, studies have begun to highlight asymmetric thinning of the choroid in eyes affected by OIS.[16,17,18] Very rarely, orbital infarction syndrome may develop in which the chronic ocular hypoperfusion affects both the intraocular and intraorbital structures.[1,2]

What are some differential diagnoses that should be considered in cases of suspected OIS?

Common differentials that should be considered in cases of suspected OIS include diabetic retinopathy (DR) and central retinal vein occlusion (CRVO).[1,2,19] Important distinctions in clinical presentation may be observed that will help elucidate the proper diagnosis. Tortuous retinal veins may support a diagnosis of CRVO as this is a feature absent in OIS. In contrast, when differentiating between DR and OIS, it has been found that intraretinal hemorrhages are generally fewer in OIS vs. diabetes. Additionally, hard exudates may point toward a diabetic etiology as this is not commonly seen in cases of OIS. However, it is important to note that OIS may sometimes co-exist with DR. In cases with discernable asymmetric or unilateral retinopathy, OIS should be considered. If funduscopic findings remain ambiguous, FA may be a beneficial test to help illuminate the true cause. Important distinguishing findings are choroidal filling defects and retinal arterial stasis that are classically found in OIS and absent in the other common differentials. Other rare but possible differentials that should be considered include

autoimmune uveitis and hyperviscosity syndromes.

What are some ancillary tests that could be performed to aid in the diagnosis of OIS?

Diagnosis of OIS is acheived by imaging, particularly of the carotid arteries. Commonly, a non-invasive test such as a carotid duplex ultrasound is performed to help provide information about both flow and anatomical structure.[20] Lumen diameter and velocity of blood flow are parameters indicative of the degree of stenosis. In conjunction with carotid duplex, color doppler imaging of the retrobulbar vessels, including the OA, should be considered as should computed tomography angiography and magnetic resonance angiography.[21-23] Flow reversal in the OA has been demonstrated to be a highly specific indication of extensive ipsilateral stenosis or occlusion. However, it is important to note that multiple factors and possible variabilities in the vascular network can affect a patient's propensity to develop OIS in the context of OA blood flow reversal. Additionally, Yamamoto et al. postulated that assessing flow in the central retinal and short posterior ciliary arteries could help assess risk for rubeosis iridis development.[12] More invasive testing includes carotid arteriography and is usually reserved for select cases.

Aside from gonioscopy and a thorough comprehensive eye examination with dilation, ophthalmic testing that can be performed in adjunct includes FA. A prolonged arm-to-retina and arm-to-choroid circulation time is an important identifier of OIS.[8,10,24] An extended choroidal filling time is considered the most specific FA sign of OIS. Meanwhile, the most sensitive sign is a prolonged retinal arteriovenous time. Staining of the major retinal vessels and branches is also commonly observed in the late stages of testing. Mid-peripheral retinal capillary non-perfusion may be an additional manifestation. Macular edema with accompanying hyperfluorescence at the optic disc from capillary leakage may sometimes be seen. While FA is more commonly done, indocyanine green angiography may also be performed. This form of imaging will confirm choroidal circulation abnormalities. Delayed arm-to-choroid and intra-choroidal circulation time should be observed.[25] Vascular filling defects may also highlight areas of hypoperfusion. Associated findings may include slow filling of watershed zones. Other less commonly performed studies are electroretinography, visual-evoked potential, ocular plethysmography and ophthalmotonometry.[26,27]

Recent advancements in technology have catapulted a multimodal approach to more thoroughly studying OIS. In a small study examining FA, spectral domain optical coherence tomography (SD-OCT), OCT angiography (OCT-A) and fundus autofluorescence in patients with acute retinal ischemia, a transient occurrence of a highly reflective band superior to or within the outer plexiform layer on SD-OCT was identified.[28] This prominent middle limiting membrane sign was said to be a retinal ischemia marker of the junction of the retina starved for oxygen between the outer and inner vascular supply. Furthermore, OCT-A imaging outlined damaged retina by illustrating a loss of flow signal most prominent in both the deep and superficial capillary plexus of the hypoxic area. Other studies using SD-OCT have identified additional markers of poor perfusion via intravascular cross-sectional appearance, vessel reflexes, and shadowing patterns of vessels present in OIS patients.[29] Enhanced depth imaging on SD-OCT has also made it possible to identify thinner subfoveal choroidal thickness in eyes with OIS and in those with symptomatic carotid artery stenosis.[16-18] It was speculated that thinning may precede the classic retinal manifestations of OIS and may be correlated to vascular status of the carotid artery. This could point toward a retinal vascular insufficiency threshold that causes the signs of OIS to develop after choroidal transformations have already taken place. Also noted were smaller choroidal luminal and stromal areas with these differences noticeable when comparing the ipsilateral affected eye in those with OIS or symptomatic carotid artery stenosis to their contralateral eye. Additionally, a positive correlation between increasing carotid artery stenosis and increased thinning of central retinal thickness, central choroidal thickness and foveal center choroidal and retinal volume was found.[18] However, it should be noted that confounding variables make these findings on OCT not OIS-specific; therefore, it is best to use a combination of diagnostic tools.

Further advances in imaging technology have made it easier to identify retinal hemodynamic alterations with the non-invasive methods OCT-A and laser speckle flowgraphy (LSFG). OCT-A can be employed to track changes in the foveal avascular zone as well as vessel density in OIS patients before and after carotid artery stenting surgery.[30] Therapeutic effect was observed through the increased vessel density and reduced superficial and deep avascular zones measured after surgical intervention. Meanwhile, another case study demonstrated improvement in macular perfusion via OCT-A findings after an anti-VEGF injection in OIS patients.[31] While FA testing can give useful information, the higher resolution and detail of OCT-A can give in vivo detailed views of anatomical and topographical changes to vessel morphology throughout the course of treatments.[30-32] In addition, LSFG may help illuminate the microcirculation of the ON and help gauge success of treatment efforts by giving an indication of retinochoroidal blood flow quantitatively.[33] Possible correlations between degree of visual disturbances in patients with ICA stenosis and the decrease in choroidal blood flow have been speculated, although further studies are required.[34,35] Nonetheless, with new explorations in research, LSFG may become a more useful application for assessment of hemodynamic compromise. Together, these studies demonstrate the potential for further understanding and assessment of changes in ocular blood flow dynamics in the presence of systemic medical intervention.

What ocular and systemic treatment is indicated for patients with OIS?

Urgent referrals to a team of doctors are necessary when identifying OIS patients. This includes cardiologists, vascular surgeons, neurologists and the patient's primary care physician. Interdisciplinary care involves managing the ocular and systemic ramifications of patients' health problems.

Treatment of patients with OIS is heavily focused on managing any potential complications that arise. While some outcomes may be irremediable and visually devastating, such as central retinal artery occlusion or ischemic optic neuropathy, others such as neovascularization may be treated. Thus, excess production of VEGF from chronic retinal ischemia is an element that needs to be mitigated. Neovascularization of the iris, irido-corneal angle, optic disc or retina may surface and necessitates intervention, particularly to curtail the development of secondary NVG which is often poorly responsive to treatment.[36] When this arises, it can be highly indicative of a poor visual prognosis. Risk factors for development of NVG include length of time between diagnosis of OIS and initial symptoms as well as the degree of carotid stenosis.[15] A method commonly used to decrease oxygenation demand of the retinal tissue is ablation of the peripheral retina. Panretinal photocoagulation or anti-VEGF injections may be considered as treatment options in patients with active neovascularization, though regression is not guaranteed.[37,38] In the event of poor retinal visualization, transconjunctival cryotherapy of the mid- to- far retinal periphery or transscleral diode laser retinopexy may be considered.[1,36]

In the event of the development of NVG, which occurs in approximately 50% of cases, both topical and oral medications to reduce IOP may be initially employed.[36,1,2] Topical alpha-2 agonists or beta-adrenergic blockers as well as topical or oral carbonic-anhydrase inhibitors are recommended as prostaglandins may aggravate any co-existing inflammatory response. In the event topical and oral therapeutic interventions are unsatisfactory, surgical intervention may be pursued. A trabeculectomy can be performed in patients with functional vision and more limited angle/iris neovascularization. However, outcomes are generally guarded due to a low success rate as well as possible intra- and post-operative complications. Another surgical option that could be explored is an aqueous shunt implant, especially in instances where neovascularization is advanced or trabeculectomy has failed. If the patient is experiencing pain or has a very poor visual prognosis, partial cycloablation by cryosurgery or the use of a diode laser may be the appropriate course of action. In instances where the eye still produces discomfort a retrobulbar injection of alcohol is appropriate for sensory denervation. Meanwhile, in extreme cases of refractory pain and a blind eye, enucleation or evisceration could be carried out.

When perfusion pressure to the ON is reduced in association with generalized hypoxia of the eye, even a normal IOP may begin to cause glaucomatous damage.[2] In these instances of normal-tension glaucoma, the standard therapeutic approach to treatment can be utilized barring the presence of any inflammatory activity. If an anterior uveitis is present, the appropriate course of action would be steroidal anti-inflammatories accompanied by a cycloplegic agent to decrease the chances of a spontaneous hyphema by restricting iris movement and simultaneously stabilizing the blood-aqueous barrier. In the presence of macular edema, treatment attempts have included intravitreal injections of anti-VEGF medications and steroids. However, there is a lack of extensive research studying its efficacy in the context of OIS.[31,38,39]

Systemic treatment of OIS may necessitate surgical intervention. A carotid artery endarterectomy (CEA) is the more commonly performed surgery and has been shown to be effective at treating symptomatic and asymptomatic stenosis of varying degrees.[40]

The North American Symptomatic Carotid Endarterectomy Trial and the European Carotid Surgery Trial both recommend CEA in patients with high-grade stenosis (70-99%), but not in patients with low-grade stenosis.[41-42] Patients with moderate stenosis (30-69%) may be considered for CEA.[41-42] Carotid artery stenting and arterial bypass surgery are other alternatives available in select circumstances.[2] If successful, carotid revascularization surgery can improve retinal perfusion. In a prospective study by Costa et al. retrobulbar blood flow was enhanced leading to alleviation of OIS-related ophthalmic findings.[43] Neroev et al. also found ophthalmic improvement in acute OIS patients as well as improvement in electrophysiological parameters of the ON in some.[44] Restored perfusion can improve photostress recovery, visual field defects and dark adaptation and eliminate amaurosis fugax.[11,45] Once blood flow is restored to the eye, OA flow may be reversed to normal. The visual prognosis after improved hemodynamics can range from stable, to deteriorating to improved eyesight.[2,11,44] Visual acuity improvement potential is greater if systemic surgery was performed prior to the development of iris neovascularization or secondary glaucoma as those with iris neovascularization are more likely to continue to visually decline.[46-49] If bypass surgery is executed during the initial stages of NVG, a regression of neovascularization of the angle is possible as well as the impediment of further glaucomatous damage. However, an unpredictable and potentially negative side effect of surgically assisted restoration of ocular blood flow is an increase in aqueous humor that leads to increased IOP. Reperfusion of the ciliary body may lead to an increase in aqueous production that is met by fibrous tissue obstruction at the angle or iris. If this were to occur, ocular surgery may be necessary. Unfortunately, in some cases even though carotid surgery is performed, a patient's pre-existing chronic vascular comorbidities may impair the body's ability to adequately increase retinal perfusion.[11,33]

In addition to or in place of surgery, patients are often placed on systemic treatment for various comorbidities including

medications to control their hypertension, diabetes, clotting, coronary heart disease,and atherosclerosis. Moreover, quitting smoking and reducing weight are recommended.[44] Even with treatment, due to the frequently severe underlying systemic conditions in patients with OIS, mortality rate can be as high as 40% within five years from onset, with cardiovascular disease and stroke being the main causes.[1]

Conclusion

Considering that an eye examination may reveal the first signs of a potentially life-threatening underlying health condition, correctly identifying OIS could be crucial to the survival of a patient. Moreover, catching the early manifestations may help preserve sight and produce better outcomes. A multimodal approach to monitoring ocular hemodynamics may help eyecare specialists assess efficacy of systemic treatments. Eyecare providers are an integral part of the interdisciplinary team involved in a patient's overall well-being and survival.

References

1. Terelak-Borys Barbara, et al. Ocular ischemic syndrome – a systematic review. Med Sci Monit. 2012;18(8):RA138-144.
2. Mendrinos E, Machinis TG, Pournaras CJ. Ocular ischemic syndrome. Surv Ophthalmol. Jan-Feb 2010;(1):2-34.
3. Koz OG, Ates A, Numan Alp M, Gultan E, Karaaslan Y, Kural G. Bilateral ocular ischemic syndrome as an initial manifestation of Takayasu's arteritis associated with carotid steal syndrome. Rheumatol Int. 2007 Jan;27(3):299-302.
4. Tang Y, Luo D, Peng W, Huang F, Peng Y. Ocular ischemic syndrome secondary to carotid artery occlusion as a late complication of radiotherapy of nasopharyngeal carcinoma. J Neuroophthalmol. 2010 Dec;30(4):315-20.
5. Huang ZL, Lin KH, Lee YC, Sheu MM, Tsai RK. Acute vision loss after intravitreal injection of bevacizumab (Avastin) associated with ocular ischemic syndrome. Ophthalmologica. 2010;224(2):86-89.
6. Ramesh S, Fiaschetti D, Goldberg RA. Orbital and ocular ischemic syndrome with blindness after facial filler injection. Ophthalmic Plast Reconstr Surg. Jul/Aug 2018;34(4):e108-e110.
7. Sivalingam A, Brown GC, Magargal LE. The ocular ischemic syndrome. III. Visual prognosis and the effect of treatment. Int Ophthalmol. 1991 Jan;15(1):15-20.
8. Brown GC, Magargal LE. The ocular ischemic syndrome. Clinical, fluorescein angiographic and carotid angiographic features. Int Ophthalmol. 1988 Feb;11(4):239-51.
9. Mizener JB, Podhajsky P, Hayreh SS. Ocular ischemic syndrome. Ophthalmology. 1997 May;104(5):859-64.
10. Hansen GL, Kofoed PK, Munch IC, et al. Retinal angiographic blood flowmetry is reduced in the ocular ischaemic syndrome. Dan Med J. 2013 Oct;60(10):A4716.
11. Kawaguchi S, Iida J, Uchiyama Y. Ocular circulation and chronic ocular ischemic syndrome before and after carotid artery revascularization surgery. J Ophthalmol. 2012;2012:350475.
12. Yamamoto T, Mori K, Yasuhara T, Tei M, Yokoi N, Kinoshita S, Kamei M. Ophthalmic artery blood flow in patients with internal carotid artery occlusion. Br J Ophthalmol. 2004 Apr;88(4):505-8.
13. Luo J, Yan Z, Jia Y, Luo R. Clinical analysis of 42 cases of ocular ischemic syndrome. J Ophthalmol. 2018 Mar 11;2018:2606147.
14. Roberts DK, Sears JM. Light-induced amaurosis associated with carotid occlusive disease. Optom Vis Sci. 1992 Nov;69(11):889-97.
15. Kim YH, Sung MS, Park SW. Clinical features of ocular ischemic syndrome and risk factors for neovascular glaucoma. Korean J Ophthalmol. 2017 Aug;31(4):343-350.
16. Kang HM, Choi JH, Koh HY, Lee SC. Significant changes of the choroid in patients with ocular ischemic syndrome and symptomatic carotid artery stenosis. PloS One. 2019;14(10):e0224210.
17. Kim DY, Joe SG, Lee JY, Kim JG, Yang SJ. Choroidal thickness in eyes with unilateral ocular ischemic syndrome. J Ophthalmol. 2015;2015:620372.
18. Wang H, Wang YL, Li HY. Subfoveal choroidal thickness and volume in severe internal carotid artery stenosis patients. Int J Ophthalmol. 2017 Dec 18;10(12):1870-1876.
19. Klijn CJ, Kappelle LJ, van Schooneveld MJ, et al. Venous stasis retinopathy in symptomatic carotid artery occlusion: prevalence, cause, and outcome. Stroke. 2002 Mar;33(3):695-701.
20. Mortimer R, Nachiappan S, Howlett DC. Carotid artery stenosis screening: where are we now? Br J Radiol. 2018 Oct;91(1090):20170380.
21. Lee HM, Fu ER. Orbital colour Doppler imaging in chronic ocular ischaemic syndrome. Aust N Z J Ophthalmol. 1997 May;25(2):157-63.
22. Modrzejewska M. Guidelines for ultrasound examination in ophthalmology. Part III: Color Doppler ultrasonography. J Ultrason. 2019;19(77):128-136.
23. Sekine T, Takagi R, Amano Y, et al. 4D flow MR imaging of ophthalmic artery flow in patients with internal carotid artery stenosis. Magn Reson Med Sci. 2018 Jan 10;17(1):13-20.
24. Wang H, Wang Y, Li H. Multimodality imaging assessment of ocular ischemic syndrome. J Ophthalmol.

2017;2017:4169135.
25. Utsugi N, Takahashi K, Kishi S. Choroidal vascular occlusion in internal carotid artery obstruction. Retina. 2004 Dec;24(6):915-9.
26. Kofoed PK, Munch IC, Sander B, et al. Prolonged multifocal electroretinographic implicit times in the ocular ischemic syndrome. Invest Ophthalmol Vis Sci. 2010 Apr;51(4):1806-10.
27. Klefter ON, Kofoed PK, Munch IC, Larsen M. Macular perfusion velocities in the ocular ischaemic syndrome. Acta Ophthalmol. 2019 Feb;97(1):113-117.
28. Feucht N, Zapp D, Reznicek L, Lohmann CP, Maier M, Mayer CS. Multimodal imaging in acute retinal ischemia: spectral domain OCT, OCT-angiography and fundus autofluorescence. Int J Ophthalmol. 2018 Sep 18;11(9):1521-1527.
29. Willerslev A, Li XQ, Cordtz P, Munch IC, Larsen M. Retinal and choroidal intravascular spectral-domain optical coherence tomography. Acta Ophthalmol. 2014 Mar;92(2):126-32.
30. Saito K, Akiyama H, Mukai R. Alteration of optical coherence tomography angiography in a patient with ocular ischemic syndrome. Retin Cases Brief Rep. 2019 Feb 4. Epub ahead of print.
31. Choi EY, Lee SC, Kim M. Optical coherence tomography angiography before and after bevacizumab injection in ocular ischemic syndrome. Retina. 2018 Mar;38(3):e23-e25.
32. Lupidi M, Fiore T, Cerquaglia A, Coscas G, Cagini C. Depth-resolved imaging of papillary vitreoretinal neovascularization: OCT-angiography assessment in ocular ischemic syndrome. Retina. 2017 Apr;37(4):e42-e44.
33. Ishii M, Hayashi M, Yagi F, Sato K, Tomita G, Iwabuchi S. Relationship between the direction of ophthalmic artery blood flow and ocular microcirculation before and after Carotid Artery Stenting. J Ophthalmol. 2016;2016:2530914.
34. Shinohara Y, Kashima T, Akiyama H, Shimoda Y, Li D, Kishi S. Evaluation of fundus blood flow in normal individuals and patients with internal carotid artery obstruction using laser speckle flowgraphy. PLoS One. 2017 Jan 5;12(1):e0169596.
35. Kunikata H, Nakazawa T. Recent clinical applications of laser speckle flowgraphy in eyes with retinal disease. Asia Pac J Ophthalmol (Phila). 2016 Mar-Apr;5(2):151-8.
36. Havens SJ, Gulati V. Neovascular glaucoma. Dev Ophthalmol. 2016;55:196-204.
37. Behera UC, Singh A. Choroidal hypoperfusion: an indicator of low tension neovascular glaucoma. Int Ophthalmol. 2019 Jan;39(1):199-201.
38. Amselem L, Montero J, Diaz-Llopis M, et al. Intravitreal bevacizumab (Avastin) injection in ocular ischemic syndrome. Am J Ophthalmol. 2007 Jul;144(1):122-4.
39. Klais CM, Spaide RF. Intravitreal triamcinolone acetonide injection in ocular ischemic syndrome. Retina. 2004 Jun;24(3):459-61.
40. Lauria AL, Koelling EE, Houghtaling PM, White PW. Carotid endarterectomy for ocular ischemic syndrome: a case report and review of the literature. Ann Vasc Surg. 2020 Aug;67:567.e9-567.e12.
41. North American Symptomatic Carotid Endarterectomy Trial Collaborators, Barnett HJM, Taylor DW, Haynes RB, et al. Beneficial effect of carotid endarterectomy in symptomatic patients with high-grade carotid stenosis. N Engl J Med. 1991 Aug 15;325(7):445-53.
42. Warlow CP. Symptomatic patients: the European Carotid Surgery Trial (ECST). J Mal Vasc. 1993;18(3):198-201.
43. Costa VP, Kuzniec S, Molnar LJ, Cerri GG, Puech-Leão P, Carvalho CA. The effects of carotid endarterectomy on the retrobulbar circulation of patients with severe occlusive carotid artery disease. An investigation by color Doppler imaging. Ophthalmology. 1999 Feb;106(2):306-10.
44. Neroev VV, Kiseleva TN, Vlasov SK, Pak NV, Gavrilenko AV, Kuklin AV. Visual outcomes after carotid reconstructive surgery for ocular ischemia. Eye (Lond). 2012 Oct;26(10):1281-7.
45. Machalińska A, Kowalska-Budek A, Kawa MP, et al. Effect of carotid endarterectomy on retinal function in asymptomatic patients with hemodynamically significant carotid artery stenosis. Pol Arch Intern Med. 2017 Nov 30;127(11):722-729.
46. Rennie CA, Flanagan DW. Resolution of proliferative venous stasis retinopathy after carotid endarterectomy. Br J Ophthalmol. 2002;86(1):117-8.
47. Kozobolis VP, Detorakis ET, Georgiadis GS, Achtaropoulos AA, Papas TT, Lazarides MK. Perimetric and retrobulbar blood flow changes following carotid endarterectomy. Graefes Arch Clin Exp Ophthalmol. 2007 Nov;245(11):1639-45.
48. Clouse WD, Hagino RT, Chiou A, DeCaprio JD, Kashyap VS. Extracranial cerebrovascular revascularization for chronic ocular ischemia. Ann Vasc Surg. 2002 Jan;16(1):1-5.
49. Ma F, Su J, Shang Q, Ma J, Zhang T, Wang X, Ma H, Yu J. Changes in ocular hemodynamics after carotid artery angioplasty and stenting (CAAS) in patients with different severity of ocular ischemic syndrome. Curr Eye Res. 2018 Feb;43(2):266-272.

Follow

Share